

# Condyle-Pinching Double-Bundle Anterior Cruciate Ligament Reconstruction



Jin Tang, B.M., and Jinzhong Zhao, M.D.

**Abstract:** The outcomes of anterior cruciate ligament (ACL) reconstruction are still unsatisfactory. Anterolateral ligament (ALL) reconstruction has been applied to augment ACL reconstruction, with better but still nonoptimal results. An anatomical analysis revealed that the route of ALL is quite different from that of ACL on the lateral view of the knee. Thus, we hope to augment ACL reconstruction with the reconstruction of an ACL-mimicking anterolateral structure, in which the route is similar to that of ACL. Thus, we aimed to introduce a combined ACL and ACL-mimicking anterolateral structure reconstruction technique, which we named condyle-pinching double-bundle ACL reconstruction. The main indication of this technique is ACL injury with a high degree of pivot shift or general laxity. The main steps of this technique include preparation of a combined graft, creation of a common femoral tunnel and 2 tibial tunnels, graft placement, and final graft fixation to an adjustable loop. We have been obtaining obvious outcome improvement clinically with this technique and consider that this report will provide special option in ACL reconstruction.

Anterior cruciate ligament (ACL) injury is a common clinical condition that often requires reconstruction. However, the clinical outcomes of ACL reconstruction are still unsatisfactory.<sup>1</sup> Studies have indicated that knee anterolateral structure (ALS) deficiency may be one of the reasons that lead to failure after ACL reconstruction.<sup>2</sup> Thus, anterolateral ligament (ALL) reconstruction has been performed to augment the reconstructed ACL. Recent studies revealed that ALL reconstruction was helpful biomechanically<sup>3</sup> but still nonoptimal clinically.<sup>4</sup> An anatomical analysis revealed that the route of ALL is quite different from that of ACL on the lateral view of the knee.

We considered that the difference between the passing direction of ALL and ACL may be the reason why ALL reconstruction was not so favorable. Thus, we developed a method to augment ACL reconstruction by reconstructing an ACL-mimicking ALS, with a route similar to that of ACL. We name this combined ACL reconstruction and ACL-mimicking ALS reconstruction

technique as condyle-pinching double-bundle ACL reconstruction, because this technique appears to be 2 ACL structure reconstructions with the lateral femoral condyle lying in between. The main indications of this technique are ACL injuries with a high degree of pivot shift.

## Surgical Techniques

### Graft Preparation

The patient is placed in a supine position (Table 1). The semitendinosus tendon and gracilis tendon, as well as the anterior half of the peroneus longus tendon, are harvested.<sup>5</sup> The 3 tendons are truncated to an equal length of >24 cm, placed side by side, braided together at both ends with 2 no. 2 ultra-high molecular weight polyester sutures (Smith & Nephew, Andover, MA), and then folded at the junction of the middle one-thirds and one lateral one-thirds, with 4 ultra-high molecular weight polyester sutures as traction sutures pulled

From the Operating Theater (J.T.) and Department of Sports Medicine (J.Z.), Shanghai Sixth People's Hospital, Shanghai Jiao Tong University, Shanghai, China.

The authors report the following potential conflicts of interest or sources of funding: Funded by National Key Research and Development Program of China (grant no. 2018YFC1106200 and 2018YFC1106202), and the project of Shanekang Hospital Development Center of Shanghai (grant no. 16CR3108B). Full ICMJE author disclosure forms are available for this article online, as [supplementary material](#).

Received February 20, 2020; accepted April 10, 2020.

Address correspondence to Jinzhong Zhao, M.D., Department of Sports Medicine, Shanghai Sixth People's Hospital, Shanghai Jiao Tong University, 600 Yishan Rd, Shanghai 200233, China. E-mail: [zhaojinzhong@vip.163.com](mailto:zhaojinzhong@vip.163.com) or [jzzhao@sjtu.edu.cn](mailto:jzzhao@sjtu.edu.cn)

© 2020 by the Arthroscopy Association of North America. Published by Elsevier. This is an open access article under the CC BY-NC-ND license (<http://creativecommons.org/licenses/by-nc-nd/4.0/>).

2212-6287/20241

<https://doi.org/10.1016/j.eats.2020.04.009>

**Table 1.** Step-by-Step Procedure

1. The semitendinosus tendon, gracilis tendon, and the anterior half of the peroneus longus tendon are harvested.
2. A combined graft including a 6-stranded folded part for ACL reconstruction and a 3-stranded nonfolded part for ALS reconstruction is made.
3. The tibial tunnel for ALS is created from the anterior edge of the tibial plateau, just medial to the Gerdy tubercle to the anterior medial side of the tibia, in a distal direction.
4. The common femoral tunnel is created in an outside-in manner from a point 5-mm posterior to the tip of the lateral femoral epicondyle to the center of the ACL footprint.
5. The ACL tibial tunnel is created from the anteromedial side of the proximal tibia to the midpoint of the ACL footprint.
6. The ACL graft part is placed from the femoral tunnel into the joint, and then into the tibial tunnel.
7. An interference screw is placed into the femoral tunnel.
8. The ALS graft part is passed underneath the iliotibial band to the lower anterolateral incision, and then pulled into its tibial tunnel.
9. An interference screw is placed into the ACL tibial tunnel.
10. A transverse tibial tunnel is created. An adjustable loop with a mini-plate is placed through this tunnel and fixed at the lateral orifice by flipping the mini-plate.
11. The sutures from the grafts are fixed to the adjustable loop.

(ACL, anterior cruciate ligament; ALS, anterolateral structure.)

through the folded end, to make a combined graft structure, including a 6-stranded folded part for ACL reconstruction and a 3-stranded nonfolded part for ALS reconstruction (Fig 1).

### Locating the Femoral Tunnel (With Video Illustration)

The knee is flexed at 90°. Through a routine anteromedial and anterolateral portal, the joint is debrided. The inner orifice of the common femoral tunnel is marked at the center of the ACL footprint with a radi-frequency probe (Fig 2A, Video 1).

### Creating a Tibial Tunnel for ALS

A low anterolateral incision is made just medial to the Gerdy tubercle. The proximal orifice of the ALS tibial tunnel is located at the anterior edge of the tibial plateau, just medial to the Gerdy tubercle (Fig 3). The tunnel is created in an anterior medial distal direction toward the incision for hamstring tendon harvesting.

### Creating a Common Femoral Tunnel

A 2- to 3-cm longitudinal incision is made at the lateral side of the knee, just 5 mm posterior to the tip of the lateral femoral epicondyle. The iliotibial band is incised longitudinally to expose the tip and the posterior slope of the lateral femoral epicondyle. A 1-cm deep socket is made with a 4-mm wide Steinman pin at a point 5 mm posterior to the tip of the lateral femoral epicondyle. A 2.4-mm K wire is placed into the socket.

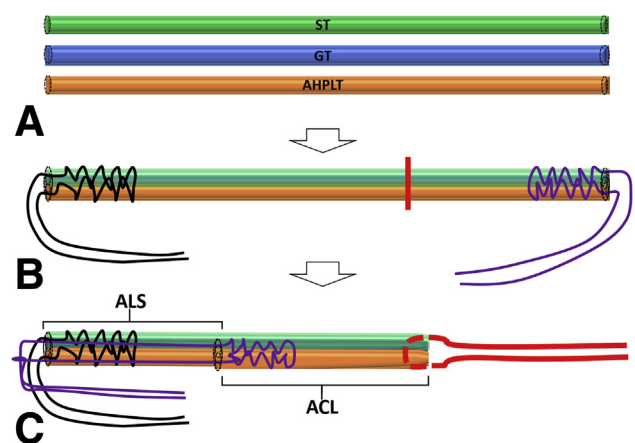
A tibial tunnel-aiming device for PCL reconstruction (Smith & Nephew, Andover, MA) is placed into the joint through the anterolateral portal. The K wire, which is placed into the socket in the lateral femoral condyle, and the tunnel-aiming pin are mounted into the device sequentially.

The arthroscope is placed into the joint through the anteromedial portal for observation. The K wire is drilled in across the lateral femoral condyle. A 6-mm

drill is drilled over the K wire to create a temporary femoral tunnel. The K wire is placed into this temporary femoral tunnel again for micro-adjustment of the final tunnel. Then, the K wire is overdrilled again to create a final femoral tunnel of the expected size, which is equal to the size of the ACL part of the graft (Fig 2B and 4B).

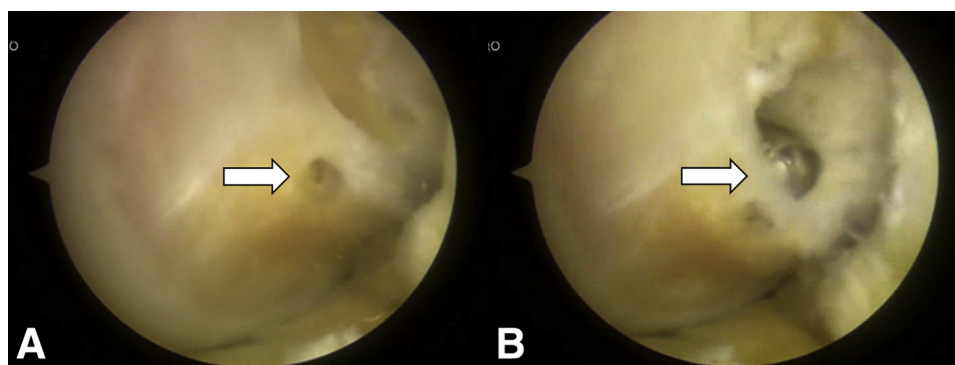
### Creating a Tibial Tunnel for the ACL

With the arthroscope placed into the joint through the anterolateral portal, the ACL tibial tunnel-aiming device (Aesculap, Tutlingen, Germany) is placed in. The inner orifice of the ACL tibial tunnel is located at the midpoint of the footprint, with its outer orifice located approximately 4 cm lower to the tibial plateau and 2 cm medial to the tibial tubercle.



**Fig 1.** Graft preparation. (A) The semitendinosus tendon (ST), gracilis tendon (GT), and the anterior half of the peroneus longus tendon (AHPLT) are used. (B) The tendons are put together and braided. (C) The tendons are folded at the junction of the middle and lateral one-thirds to form a combined graft. (ACL, anterior cruciate ligament; ALS, anterolateral structure.)

**Fig 2.** Intra-articular view of the location of the femoral tunnel (right knee viewed from the anteromedial portal). It is located at the center of the ACL footprint. (A) Reference point for location. (B) Created tunnel. (ACL, anterior cruciate ligament.)



### Graft Placement

A guide suture is placed into the joint through the femoral tunnel, and then pulled into the ACL tibial tunnel. Then, the ACL part of the graft is placed in from the femoral tunnel to the tibial tunnel until the whole ACL part of the graft is pulled into the lateral orifice of the femoral tunnel (Fig 5). A 6-mm wide interference screw is placed into the femoral tunnel for graft fixation (Fig 4).

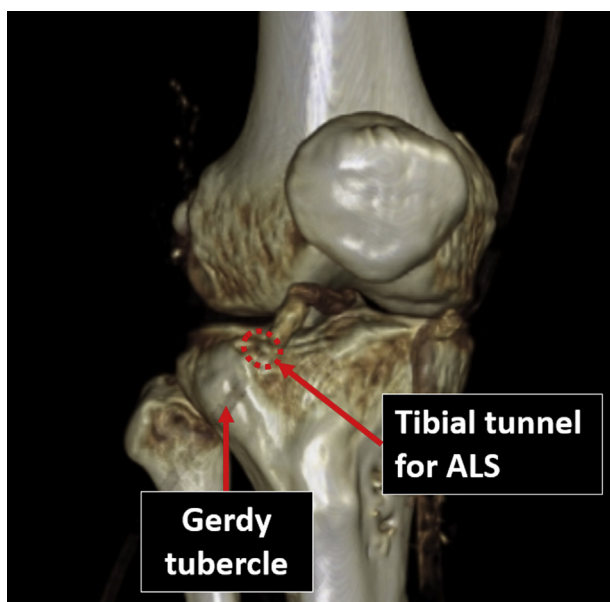
A hemostat is placed into the low anterolateral incision, through the underside of the iliotibial band and out of the lateral incision, to create a soft-tissue tunnel for the reconstructed ALS. Then, the knee is moved from flexion to extension several times to widen and straighten the soft tissue tunnel. The ALS part of the graft is pulled through this soft-tissue tunnel to the low

anterolateral incision. Then, the graft end is pulled into the tibial tunnel for ALS.

### Graft Fixation on the Tibial Side

The knee is placed in full extension. An interference screw is placed into the ACL tibial tunnel, through the posterior side of the graft, until it reaches the inner orifice of the tunnel.

A 2-mm incision is made approximately 1 cm lateral to the anterior tibial ridge at a transverse plane distal to the distal orifices of the 2 tibial tunnels for ACL and ALS reconstruction. A 4.5-mm transverse tibial tunnel is created. A mini-plate with an adjustable loop (Arthrex, Naples, FL) is pulled through this tunnel from the medial to the lateral side. Half of the sutures from each graft end are pulled through the adjustable loop. The mini-plate is pulled through the transverse tibial tunnel and flipped over the lateral orifice. The sutures from each graft end are tied to their counterparts (Fig 6). The adjustable loop is reduced for final graft fixation.

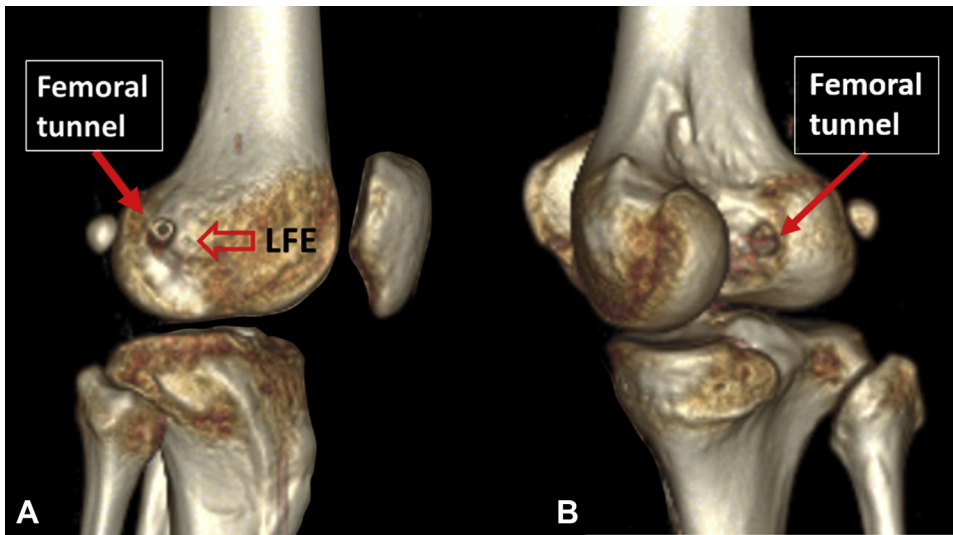


**Fig 3.** Location of the tibial tunnel for ALS reconstruction (right knee). The tibial tunnel for the ALS reconstruction is located at the anterior edge of the lateral tibial plateau, just medial to the Gerdy tubercle. (ALS, anterolateral structure.)

### Discussion

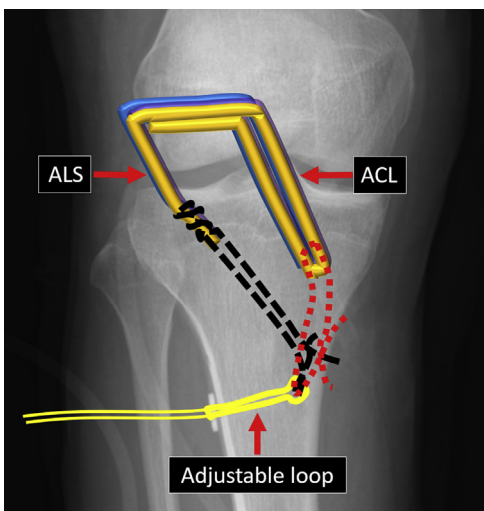
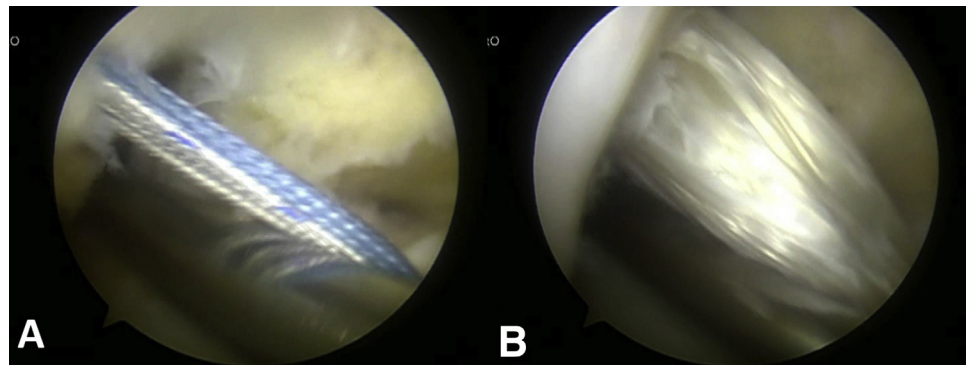
From our point of view, this combined reconstruction technique is special because in this technique, we created a special ALS that is ACL mimicking instead of ALL mimicking. The ALL originates somewhere around the lateral femoral epicondyle to its tibial attachment between the fibular head and Gerdy tubercle,<sup>6</sup> with a route similar to that of MCL, but different from that of ACL on the lateral view of the knee (Fig 7). Considering that structures with similar routes have similar functions, we think that ALS reconstruction is the best augmentation method for ACL reconstruction. The current reconstruction technique supports the concept of augmentation of the anterolateral complex, instead of the ALL of the knee.<sup>7</sup>

One critical step in this technique is to create a common femoral tunnel that is perpendicular to the sagittal plane. Our pilot study revealed that the anatomic center of the femoral footprint corresponds to a point

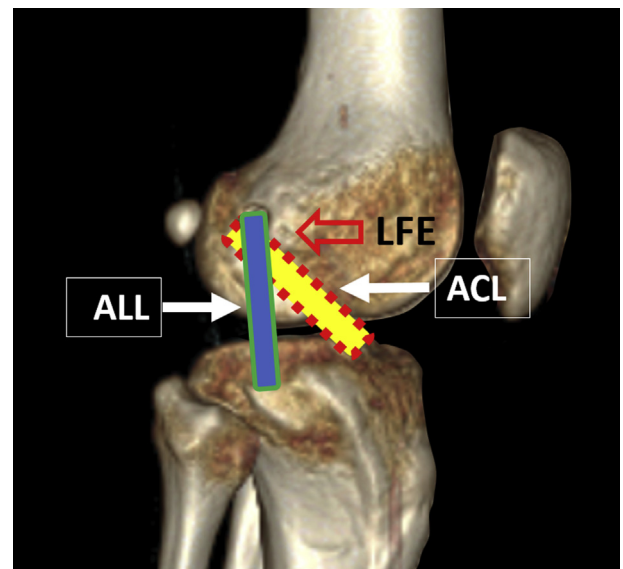


**Fig 4.** Location of the femoral tunnel (right knee). (A) Outer orifice. (B) Inner orifice. (LFE, lateral femoral epicondyle.)

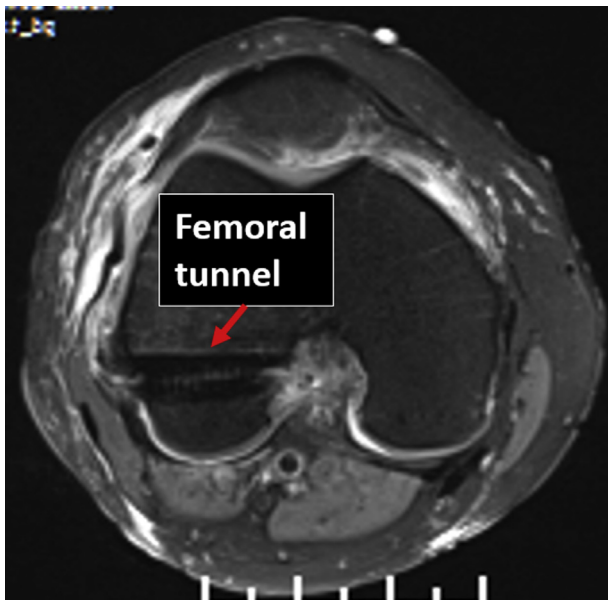
**Fig 5.** Placement of the intra-articular graft part (right knee viewed from the anteromedial portal). An obturator is placed under the traction sutures (A) and the graft (B) as a pulley.



**Fig 6.** Distal suspension fixation of both the ACL and ALS (right knee). The sutures from the grafts are tied to an adjustable loop placed through a transverse tibial tunnel. (ACL, anterior cruciate ligament; ALS, anterolateral structure.)



**Fig 7.** The routes of ACL and ALS (lateral view of right knee). An obvious angulation between the 2 lines can be found. (ACL, anterior cruciate ligament; ALS, anterolateral structure; LFE, lateral femoral epicondyle.)



**Fig 8.** Direction of the femoral tunnel (right knee). A femoral tunnel perpendicular to the sagittal plane results in concentric locations of the ACL and ALS insertions. (ACL, anterior cruciate ligament; ALS, anterolateral structure.)

approximately 5 mm posterior to the tip of the lateral femoral epicondyle on lateral view of the knee (unpublished data, Zhao, 2019). Thus, starting from this point medially to the center of the ACL footprint, the desired femoral tunnel is created in most cases (Fig 8). On the tibial side, ALS insertion is slightly anterior compared with ACL insertion. Through the desired location for the ALS on both femoral and tibial sides, a structure mimicking the route of ACL can be created (Fig 9).

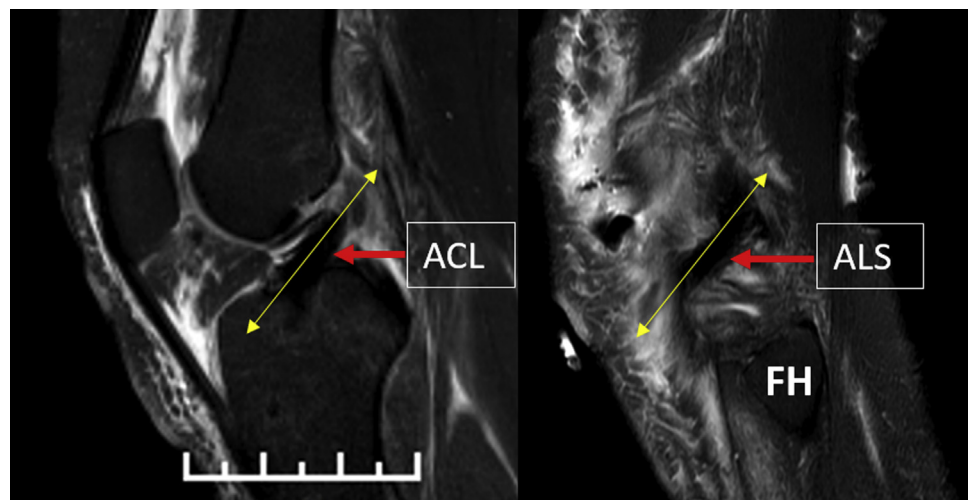
**Table 2.** Pearls and Pitfalls

1. A graft that is large enough should be used. We prefer the size of the graft part for ACL reconstruction to be  $\geq 8$  mm. Thus, we used 3 tendon strands (ST, GT, and the AHPLT). However, when the ST and GT are large enough, there is no need to use the AHPLT.
2. When creating the tibial tunnel for ALS, slightly drill posteriorly into the tibial edge at first, then change the drilling direction to the anterior, medial, and distal sides.
3. During creation of the common femoral tunnel, make sure that the direction of the tunnel is perpendicular to the sagittal plane to ensure that the femoral insertions of the ACL and ALS show a concentric pattern in lateral view.
4. When the graft fits the femoral tunnel well, interference screw fixation on the femoral side can be omitted. When interference screw fixation is applied, do not use screws that are too large. Otherwise, the graft will be cut at the orifice.
5. Creating a straight soft tissue tunnel for ALS under the iliotibial band is critical at positions from knee flexion to extension. A curved soft-tissue tunnel will result in a curved or loose ALS, which may affect the knee stability.
6. All grafts are fixed in full extension and neutral rotation of the knee to prevent overconstraint.

ACL, anterior cruciate ligament; AHPLT, anterior half of the peroneus longus tendon; ALS, anterolateral structure; GT, gracilis tendon; ST, semitendinosus tendon.

The main limitation of this technique is irritation of the ALS to the iliotibial band. Creating a soft-tissue tunnel under the iliotibial band for the ALS is important to avoid irritation (Table 2). Harvesting the anterior half of the peroneus longus tendon is easier than harvesting the hamstring tendons. However, sometimes it is difficult to push the tendon stripper across the tendon–muscle conjunction because the muscle part lies inside and is enclosed by the outside tendon part. In this case, an additional proximal incision is always needed to complete the harvesting.

**Fig 9.** Similar routes of the reconstructed ACL and ALS (right knee) (ACL, anterior cruciate ligament; ALS, anterolateral structure; FH, fibular head.)



## References

1. Xie X, Liu X, Chen Z, Yu Y, Peng S, Li Q. A meta-analysis of bone-patellar tendon-bone autograft versus four-strand hamstring tendon autograft for anterior cruciate ligament reconstruction. *Knee* 2015;22:100-110.
2. Kittl C, El-Daou H, Athwal KK, et al. The role of the anterolateral structures and the ACL in controlling laxity of the intact and ACL-deficient knee. *Am J Sports Med* 2016;44:345-354.
3. Kraeutler MJ, Welton KL, Chahla J, LaPrade RF, McCarty EC. Current concepts of the anterolateral ligament of the knee: Anatomy, biomechanics, and reconstruction. *Am J Sports Med* 2018;46:1235-1242.
4. Sonnery-Cottet B, Barbosa NC, Vieira TD, Saithna A. Clinical outcomes of extra-articular tenodesis/anterolateral reconstruction in the ACL injured knee. *Knee Surg Sports Traumatol Arthrosc* 2018;26:596-604.
5. Zhao J, Huangfu X. The biomechanical and clinical application of using the anterior half of the peroneus longus tendon as an autograft source. *Am J Sports Med* 2012;40:662-671.
6. Ariel de Lima D, Helito CP, Lacerda de Lima L, de Castro Silva D, Costa Cavalcante ML, Dias Leite JA. Anatomy of the anterolateral ligament of the knee: A systematic review. *Arthroscopy* 2019;35:670-681.
7. Getgood A, Brown C, Lording T, et al. The anterolateral complex of the knee: Results from the International ALC Consensus Group Meeting. *Knee Surg Sports Traumatol Arthrosc* 2019;27:166-176.