

Minimally Invasive Approach for Redo Mitral Valve Replacement: No Aortic Cross-Clamping and No Cardioplegia

Hong Rae Kim, M.D., Gwan Sic Kim, M.D., Jae Suk Yoo, M.D., Jae Won Lee, M.D.

A 75-year-old woman who had previously undergone a double valve replacement was admitted to Asan Medical Center because of severe bioprosthetic mitral valve dysfunction and tricuspid regurgitation. Under hypothermic fibrillatory arrest without aortic cross-clamping, minimally invasive mitral and tricuspid valve surgery was performed via a right minithoracotomy.

Key words: 1. Minimal invasive surgery
2. Mitral valve, replacement
3. Aortic cross-clamping

CASE REPORT

A 75-year-old woman who had previously undergone a double valve replacement, tricuspid annuloplasty, and maze operation in 2005 presented with dyspnea (New York Heart Association Functional Class III). On examination, the patient had a cachectic appearance with a body mass index of 20.1. An irregular heartbeat with a diastolic murmur was detected by auscultation. Laboratory tests revealed no remarkable findings, apart from an increased level of brain natriuretic peptide (120 pg/mL). A chest X-ray showed previous median sternal wiring, cardiomegaly, and pulmonary vascular engorgement. A pulmonary function test showed a reduced forced expiratory volume indicative of obstructive lung disease (35% of normal; 0.57 L). Transthoracic echocardiography revealed severe bioprosthetic mitral valve stenosis and severe tricuspid regurgitation. The prosthetic mitral valve was closed due to thickening of the leaflet, except on the anterior side. Computed tomography showed mitral leaflet thickening and

calcification, which explained the early degeneration of the prosthetic valve. The patient's European System for Cardiac Operative Risk Evaluation II was 9.51%.

We decided to perform minimally invasive mitral and tricuspid valve surgery via right minithoracotomy using the AESOP 3000 system (Automated Endoscope System for Optimal Positioning; Computer Motion Inc., Santa Barbara, CA, USA) through a sternotomy approach in order to avoid major vessel injury, despite the presence of extensive pericardial adhesions.

Under general anesthesia with double lumen intubation, the patient was positioned with the right chest slightly elevated. External defibrillation pads were placed. After an anterolateral minithoracotomy was performed through the right fourth intercostal space via an 8-cm incision, cardiopulmonary bypass was initiated using peripheral cannulation through the right internal jugular vein, right femoral vein, and right femoral artery, under transesophageal echocardiography guidance (Fig. 1). A videoscope of the AESOP 3000 was inserted through a

Department of Thoracic and Cardiovascular Surgery, Asan Medical Center, University of Ulsan College of Medicine

Received: July 7, 2014, Revised: August 11, 2014, Accepted: September 3, 2014, Published online: April 5, 2015

Corresponding author: Jae Won Lee, Department of Thoracic and Cardiovascular Surgery, University of Ulsan College of Medicine, 88 Olympic-ro 43-gil, Songpa-gu, Seoul 138-736, Korea
(Tel) 82-2-3010-3584 (Fax) 82-2-3010-6966 (E-mail) jwlee@amc.seoul.kr

© The Korean Society for Thoracic and Cardiovascular Surgery. 2015. All right reserved.

© This is an open access article distributed under the terms of the Creative Commons Attribution Non-Commercial License (<http://creativecommons.org/licenses/by-nc/3.0>) which permits unrestricted non-commercial use, distribution, and reproduction in any medium, provided the original work is properly cited.

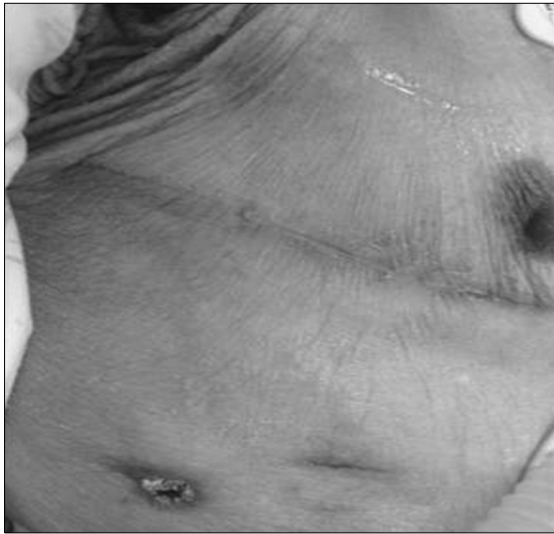

Fig. 1. Photograph of the right minithoracotomy wound.

port placed in the third intercostal space on the anterior axillary line. The operative field was filled with carbon dioxide gas at the rate of 5 L/min throughout the surgery. Dissection of the ascending aorta for aortic cross-clamping was initially attempted, but was not possible due to severe periaortic adhesion and sternal wire erosion into the ascending aorta wall (Fig. 2). Therefore, we changed the operative strategy and performed the surgery without aortic cross-clamping. The patient's body temperature was lowered to 23°C to induce ventricular fibrillation. When hypothermic fibrillatory arrest was achieved, the superior vena cava and inferior vena cava were snared down. After a longitudinal right atriotomy, a trans-septal incision was performed to obtain a surgical view of the mitral lesion. The previous mitral prosthesis showed structural valve deterioration involving leaflet thickening and calcification, as indicated by transthoracic echocardiography. The prosthetic valve was replaced with a 25-mm Epic valve (St. Jude Medical Inc., St Paul, MN, USA). The tricuspid valvuloplasty was performed using the Alfieri (edge-to-edge) method. To prevent possible left atrial air embolism, the left atrium was filled with blood before the trans-septal incision was closed. Intraoperative transesophageal echocardiography, which was performed by a cardiologist after weaning the patient from cardiopulmonary bypass, revealed no paravalvular leakage of the mitral valve or interatrial shunt, although mild tricuspid regurgitation remained. The total cardiopulmonary

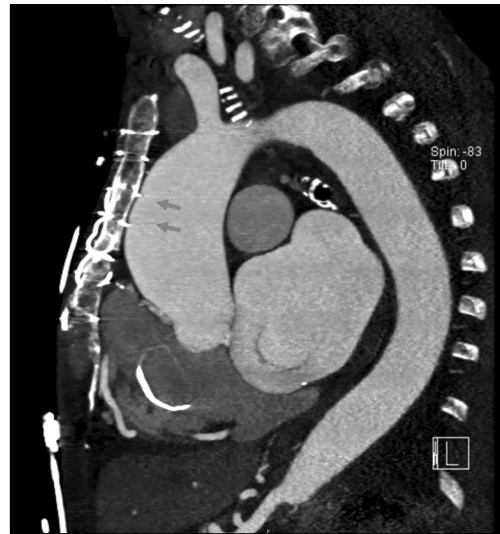


Fig. 2. Preoperative computed tomography scan showing sternal wire erosion (arrows) into the aorta.

bypass and fibrillatory arrest times were 243 and 89 minutes, respectively.

Postoperative echocardiography showed a well-functioning prosthetic mitral valve with an ejection fraction of 55%. The patient recovered without major complications, such as low cardiac output syndrome or stroke.

DISCUSSION

Minimally invasive mitral valve surgery via right minithoracotomy has grown in popularity over the last several years [1]. Continuing technological development has facilitated the implementation of minimally invasive approaches in cardiac surgery, and our institution has published several studies in which minimally invasive cardiac surgery has shown favorable results [2]. One of the advantages of the minimally invasive approach is that in case of repeat mitral valve surgery, the right thoracotomy approach can provide excellent exposure of the mitral valve through a relatively clear plane that is not influenced by the previous sternotomy. A sternotomy approach in the presence of extensive pericardial adhesions carries a higher risk of major vessel injury and the danger of injuring a previous patent coronary artery bypass. Of course, transapical transcatheter mitral valve-in-valve implantation could be an alternate possibility, but our institution

has little experience with that technique. Therefore, in our institution, the minithoracotomy approach is usually utilized when conducting a repeat mitral surgery. However, the dissection of the ascending aorta to achieve aortic cross-clamping is a major concern.

In the present case, dissecting the ascending aorta for aortic cross-clamping was not possible due to severe adhesion and sternal wire erosion into the ascending aorta. We therefore decided to apply a strategy involving hypothermic fibrillatory arrest without an aortic cross-clamp, which is known as the no-touch technique [3,4].

Adequate myocardial protection against both ischemic and distention injuries and reducing the risk of stroke are generally major concerns in left heart surgery performed under fibrillatory arrest [5]. In order to achieve successful myocardial protection, we opened the left atrium immediately upon fibrillation in order to keep the left ventricle decompressed. Moreover, carbon dioxide gas was infused into the operative field to ensure that air did not enter the systemic circulation, and the mean arterial perfusion pressure was maintained at over 30 mmHg in order to keep the aortic valve closed. Transesophageal echocardiography confirmed that no intracardiac air was present before cardioversion.

Multiple potential contraindications exist for applying the no-touch technique. One is the presence of severe pulmonary adhesion, and the other is the presence of aortic regurgitation. In conditions of severe aortic regurgitation, coronary perfusion cannot be sufficiently maintained and distention of the left ventricle can occur if no specific left ventricular venting procedure is followed. However, despite preoperative risk factors such as mild aortic regurgitation and a low ejection fraction, our patient recovered well with no major complications.

Our case report demonstrates that in select cases, well-conducted fibrillatory arrest, careful left ventricular decompression, and air embolism can overcome these potential problems.

In conclusion, in cases of cardiac valve surgery performed via right thoracotomy, the no-touch technique using hypothermic fibrillatory arrest may be a useful alternative if aortic cross-clamping is unexpectedly impossible.

CONFLICT OF INTEREST

No potential conflict of interest relevant to this article was reported.

REFERENCES

1. Cohn LH, Adams DH, Couper GS, et al. *Minimally invasive cardiac valve surgery improves patient satisfaction while reducing costs of cardiac valve replacement and repair.* Ann Surg 1997;226:421-6.
2. Yoo JS, Kim JB, Jung SH, Choo SJ, Chung CH, Lee JW. *Echocardiographic assessment of mitral durability in the late period following mitral valve repair: minithoracotomy versus conventional sternotomy.* J Thorac Cardiovasc Surg 2014; 147:1547-52.
3. Kitamura T, Stuklis RG, Edwards J. *Redo mitral valve operation via right minithoracotomy: "no touch" technique.* Int Heart J 2011;52:107-9.
4. Chitwood WR Jr, Elbeery JR, Moran JF. *Minimally invasive mitral valve repair using transthoracic aortic occlusion.* Ann Thorac Surg 1997;63:1477-9.
5. Petracek MR, Leacche M, Solenkova N, et al. *Minimally invasive mitral valve surgery expands the surgical options for high-risk patients.* Ann Surg 2011;254:606-11.