

Abdominal Wall Reconstruction Using Pedicled Antero Lateral Thigh Flap

Amit Sharma¹, Sushrut Kalra^{1*}, Mayank Aggarwal¹, Samarth Gupta²

1. Department of Plastic and Reconstructive Surgery, Sawai Man Singh Medical College and Hospital, Jaipur, Rajasthan, India
2. St Andrews Center for Plastic Surgery, Broomfield Hospital, Chelmsford, Essex, United Kingdom

ABSTRACT

Background: Reconstructing abdominal wall defects has been a difficult task for surgeons. The abdominal wall defects range from defects of only soft tissue to full thickness defects including all the three layers of the abdomen. Only soft tissue defects are commonly caused by peritonitis and laparotomies, and full thickness defects can occur from en bloc resection of tumours as well as trauma. Treatment options available include component separation, partition technique, flap coverage, and more recently acellular dermal matrix.

Methods: This retrospective study done between 2016 and 2020 where 20 patients were operated for abdominal wall defect using Pedicled ALT flap in the Department of Plastic and Reconstructive Surgery, Sawai Man Singh Hospital, Jaipur, Rajasthan, India.

Results: The study consisted of total 20 patients, 14 males and 6 females. Eight patients were post electric burn, 5 patients had suffered trauma, 4 patients underwent resection of abdominal wall tumour and 3 patients were post laparotomy for peritonitis. Mean age of patients was 48 years (range from 36 to 62 years). Mean fascia defect size was 14.2 cm (range 12.2 to 16.4 cm). Mean operative time was 170 minutes (range from 140 minutes to 220 minutes). Postoperative hospital stay ranged from 8 days to 24 days (mean-12 days).

Conclusion: Pedicled ALT flap has expanded the armamentarium of plastic surgeons for reconstruction of abdominal wall defects.

Keywords: Abdominal wall defect, Abdominal wall reconstruction, Pedicled Anterolateral Thigh flap

Please cite this paper as:

Sharma A, Kalra S, Aggarwal M, Gupta S. Abdominal Wall Reconstruction Using Pedicled Antero Lateral Thigh Flap. *World J Plast Surg*. 2022;11(3):63-71.

doi: 10.52547/wjps.11.3.63

*Corresponding Author:

Sushrut Kalra

SMS Medical College and Hospital

Jaipur, Rajasthan, India

Email: sushrutkalra125@gmail.com

Received: 2022/08/14

Accepted: 2022/11/25

INTRODUCTION

Reconstructing abdominal wall defects has been a difficult task for surgeons. The abdominal wall defects range from defects of only soft tissue to full thickness defects including all the three layers of the abdomen. Only soft tissue defects are commonly caused by peritonitis and laparotomies¹⁻⁴, and full thickness defects can occur from en bloc resection of tumours⁵ as well as trauma. Electric burns can cause both soft tissue as well as full thickness defects.



The musculature of lateral abdominal wall is composed of three layers. The most superficial layer is made by external oblique, under which lies internal oblique and the deepest one is the transverse abdominis. The fibres of external oblique are in superolateral to inferomedial direction, those of internal oblique lie perpendicular to the external oblique. Transverse abdominis muscle fibres run horizontally. Each of these three muscles form an aponeurosis and that inserts into the linea alba which is a structure in the midline. The aponeurosis of these three muscles forms the anterior and posterior layers of the rectus sheath. Rectus abdominis muscle forms the muscular layer of the medial part of the abdominal wall. The posterior layer of the rectus sheath is absent below the arcuate line, which lies 3 to 6 cm below the umbilicus⁶.

An ideal reconstruction of abdominal wall is possible when 3 layers of abdomen including skin, muscle and fascia. Muscle reconstruction provides adequate functioning^{7,8} and fascia gives protection from hernia and infection.

Treatment options available include component separation, partition technique, flap coverage, and more recently acellular dermal matrix.

Pedicled ALT flap was first used by Kimata et al.⁹ for an abdominal reconstruction following which it has been widely used^{10,11}. It derives its blood supply from the descending branch of the lateral circumflex femoral artery (branch of profunda femoris artery)¹².

Pedicled ALT flap has following advantages: the flap can reach various locations such as gluteal region, groin, perineum and lower abdomen as the pedicle length ranges from 4 to 20 cm and it has a wide arc of reach. It has no functional deficit and donor site can be primarily closed for a maximum size of 21 x 9 cm¹³.

The pedicled ALT flap can be harvested as adipofascial or myocutaneous flap. In addition, tensor fascia lata, vastus lateralis or rectus femoris can be harvested with the flap depending on the requirements.

In our study, we discuss the use of pedicled ALT flap in abdominal wall reconstruction in various conditions and assess the outcome.

MATERIALS AND METHODS

This retrospective study was conducted between

2016 and 2020 where 20 patients were operated for abdominal wall defect using Pedicled ALT flap in the Department of Plastic and Reconstructive Surgery, Sawai Man Singh Hospital, Jaipur, Rajasthan, India. The study has been evaluated by the institutional Ethics Committee and an approval was obtained to carry it out. A written and informed consent was obtained from the patients participating in the study. Indications included abdominal wall defect due to electric burn, trauma, perforation, and malignancy. Surgical technique: anterior superior ilia spine and superior- lateral border of patella are marked and a line joining both the points is drawn. A circle of 3 cm radius is drawn on the midpoint of this line and it is divided into 4 compartments. Using hand help doppler, perforators were marked in this circle. Most of the perforators lie in inferior-lateral compartment of the circle.

The flap is designed according to the defect of abdominal wall keeping the perforator in the center. Incision is given over the medial border of the marked flap and deepened to the subfascial layer. The pedicle is dissected between the rectus femoris and vastus lateralis muscle and perforators marked are carefully visualized and isolated with the pedicle. The tensor fascia lata lying laterally to the vastus lateralis muscle is included in the flap along the lateral markings of the flap.

After elevation of the flap, a subcutaneous tunnel is created under the rectus femoris and sartorius muscles was prepared, and flap was transposed to the abdominal wall defect. The muscle of the flap is fixed with the abdominal wall muscle and TFL fixed to the abdominal fascia and negative suction drain placed underneath.

Donor site is also closed primarily if possible or skin grafted.

RESULTS

The study consisted of total 20 patients, out of which 14 were males and 6 females. Eight patients were post electric burn, 5 patients had suffered trauma, 4 patients underwent resection of abdominal wall tumour and 3 patients were post laparotomy for peritonitis.

Mean age of patients was 48 years (range from 36 to 62 years). Mean fascia defect size was 14.2 cm (range 12.2 to 16.4 cm). Mean operative time was 170 minutes (range from 140 minutes to 220 minutes).

Postoperative hospital stay ranged from 8 days to 24 days (mean- 12 days).

Fourteen patients (5 post electric burn, 5 post traumatic, and 4 post abdominal wall tumour resection) had abdominal wall defects including all the three layers and 6 patients (3 post electric burn and 3 post laparotomy) had only soft tissue defects / partial thickness defects (Figure 1- 8).

Patients with full thickness defects were reconstructed by fasciocutaneous pedicled ALT flap with tensor fascia lata and patients with partial thickness defects were reconstructed by only fasciocutaneous pedicled ALT flap.

One patient developed abdominal wound infection in postoperative period and was treated with dressing and antibiotics.

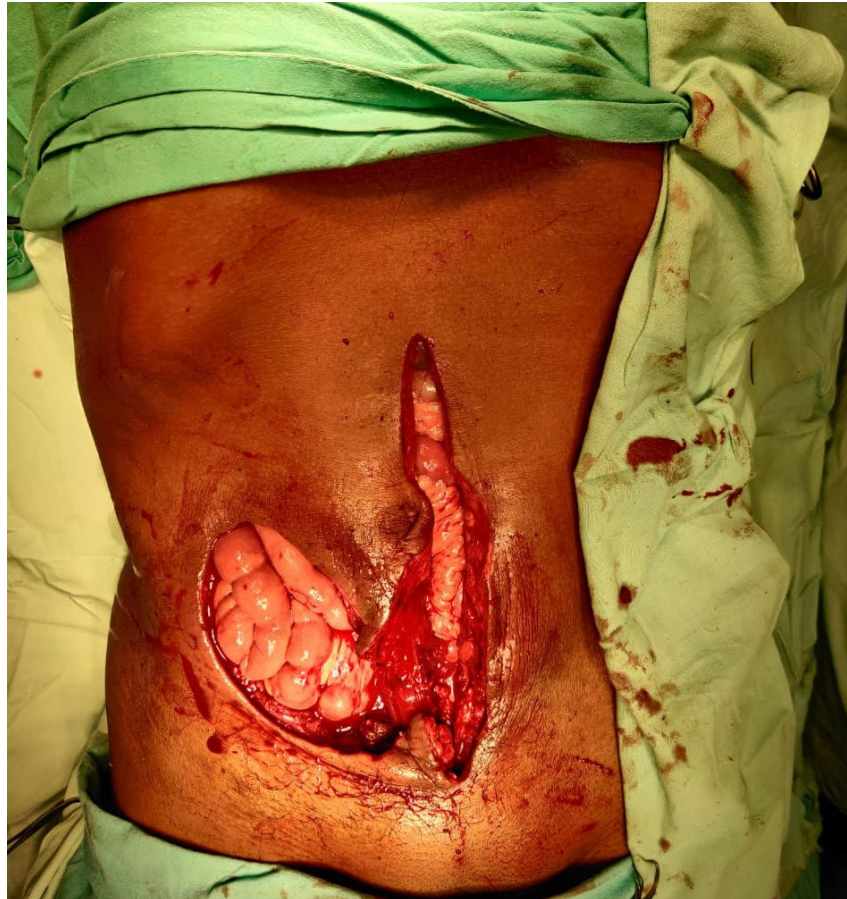

Figure 1: A 42-year-old patient operated for abdominal wall tumour. A full thickness defect of 14 x 8 cm after tumour resection

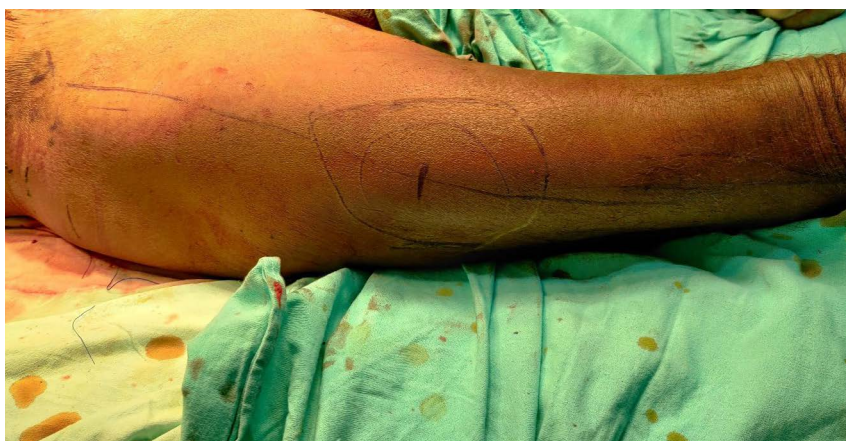

Figure 2: Markings of pedicled ALT flap

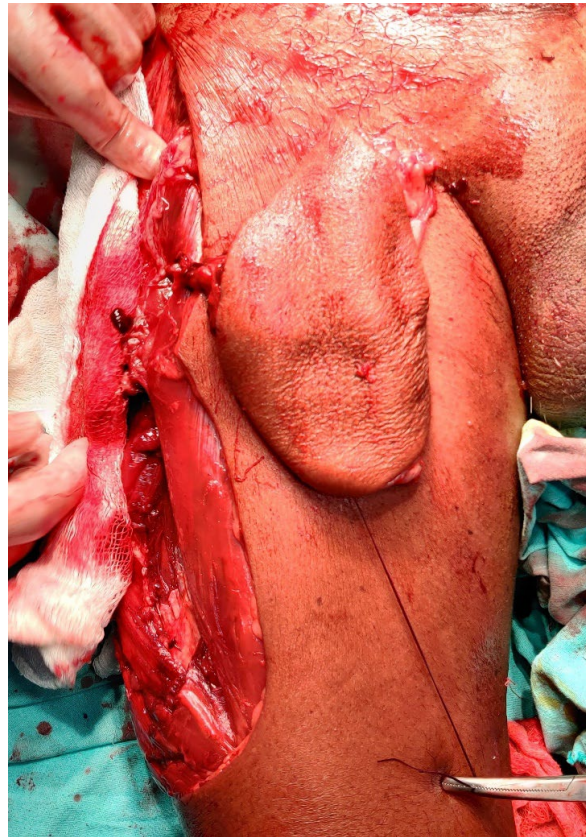


Figure 3: Intra operative picture of raised pedicled ALT flap

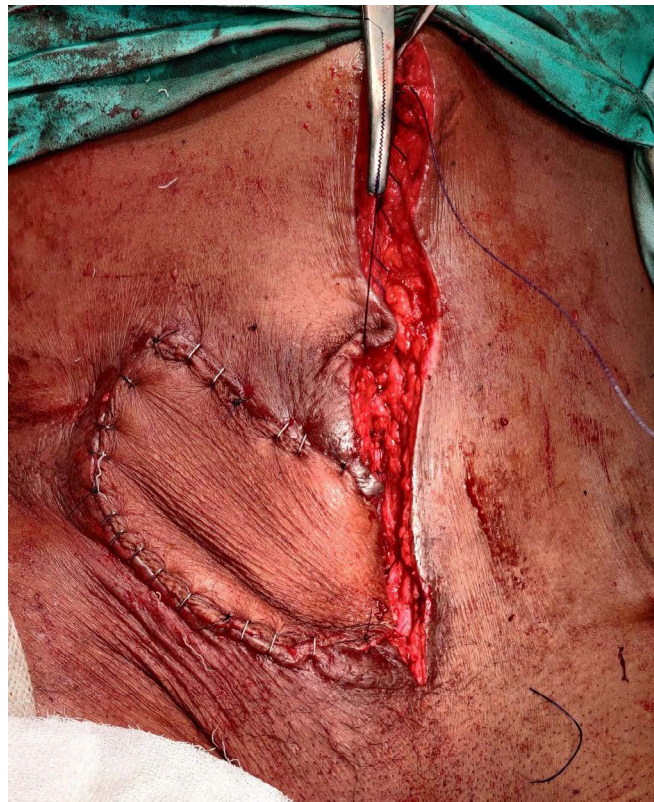

Figure 4: Flap after inset

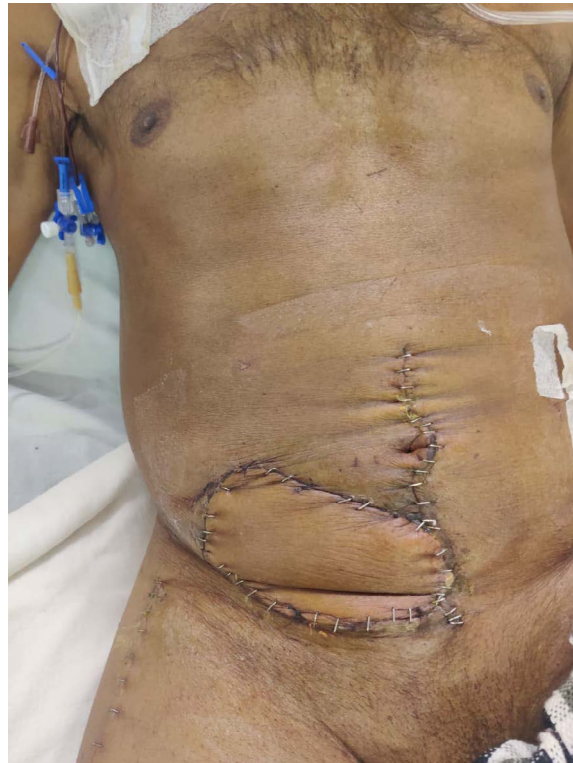

Figure 5: Post operative picture

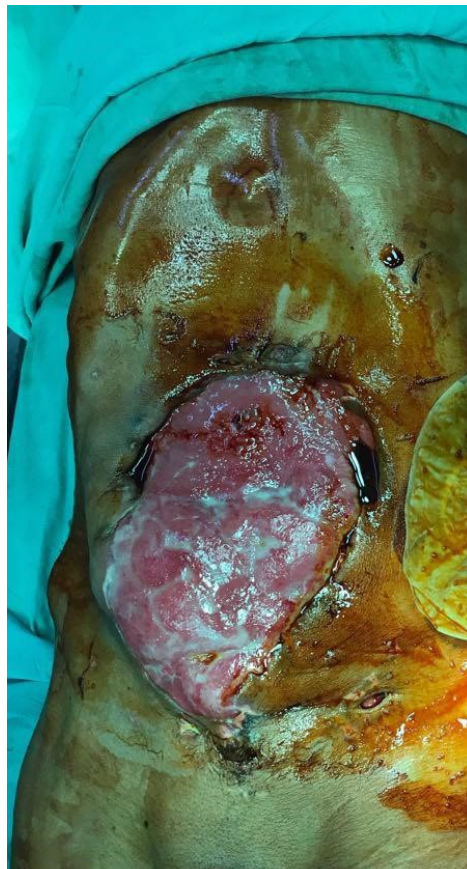

Figure 6: A 40-year-old patient with history of laparotomy for perforation, presented with abdominal wall defect of size around 25 x 18 cm.

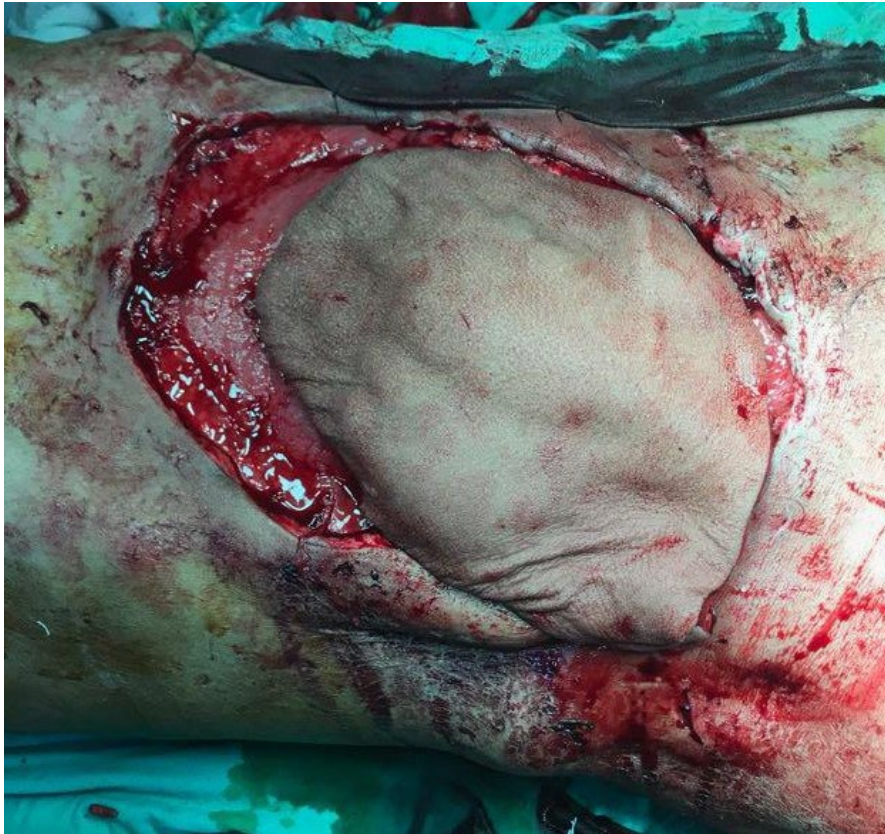


Figure 7: Patient was operated and defect covered with pedi cled ALT flap

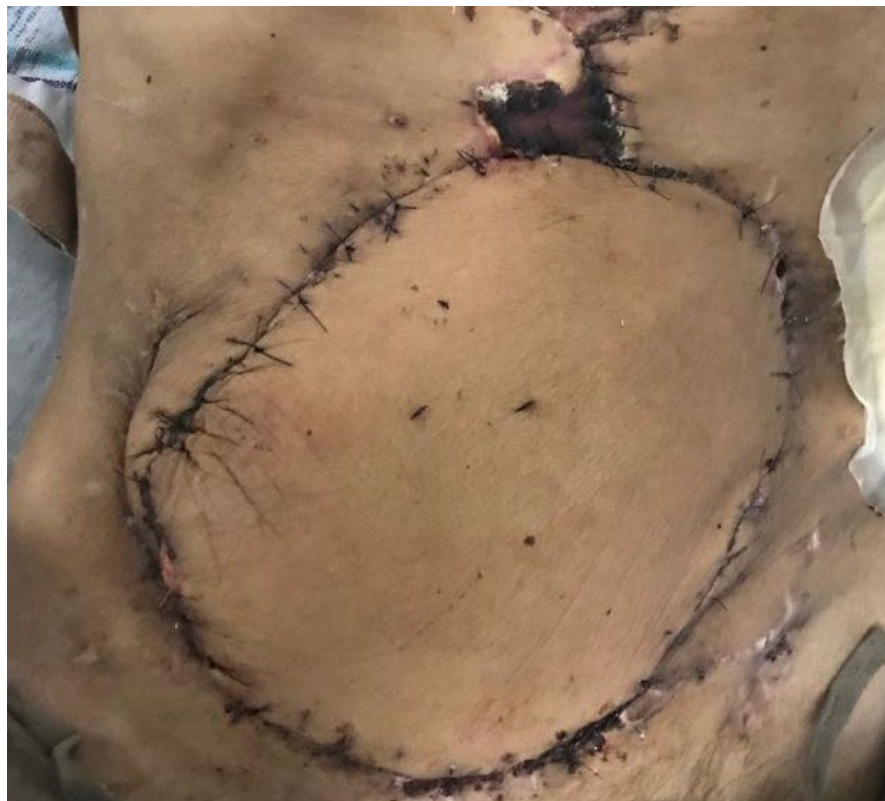

Figure 8: Post operative picture

On long term follow up, one patient developed hypertrophic scarring on abdomen, and one patient developed incisional hernia and four patients complained of a bulky flap.

Patient with incisional hernia underwent mesh hernioplasty with no recurrence. Patients with bulky flap underwent flap thinning and patient with hypertrophic scar was treated by triamcinolone injection in scar.

DISCUSSION

There are various methods to reconstruct the abdominal wall, including component separation, flaps both pedicled and free as well as recently used like acellular dermal matrix. In cases with bowel eventration and mesh infection, it is difficult to reconstruct composite abdominal wall defects.

For abdominal wall reconstruction, many pedicled flaps have been described such as, external obliques¹⁴, rectus abdominis¹⁵ and the antero-lateral thigh (ALT) myocutaneous flap¹⁶. Less frequently free tissue transfer using latissimus dorsi⁽³⁾ and ALT flap has also been described ALT flap is preferred due to its anatomical properties and versatility¹⁷, and when raised with fascia lata a better functional repair is possible as it gives strength and reduce the risk of eventration in future. The vastus lateralis muscle will work like abdominal wall muscle, rectus abdominis^{16,18,19}.

Mathes et al. suggested to use flap cover in complex abdominal wall reconstruction especially where attempts had been made with mesh and it got infected⁴. In cases where there is infection present use of flaps has its advantages as they bring in healthy vascularised tissue and there is better wound healing and antibiotic delivery as well^{16,20}.

ALT flap was first described by Song et al¹⁸ as a free flap, and since then the flap has been routinely used. It has now expanded the armamentarium of plastic surgeons for skin and soft tissue reconstruction. In the past few years, popularity of pedicled ALT flap has increased considerably. For abdominal wall reconstruction, the ALT flap has been successfully used^{19,21-23}. Its vascular pedicle is long and reliable, and due to its versatility, flap can be designed accordingly to match the defect which requires reconstruction. In some case reports, it has been shown the flap sizes up to 38 x 20 cm (760 cm²) can be raised²⁴. Raising a pedicled flap is less complex

and takes less time as compared to the free flap²⁵.

The perforators on which pedicled ALT is based are present near mid-thigh because of which the length of the pedicle is more as compared to the TFL flap, which has its pedicle as its proximal end⁽⁹⁾. The blood supply of the ALT flap is also more reliable blood supply as it is a "true" perforator flap based 80% of the time on the musculocutaneous perforators traversing the vastus lateralis muscle²⁶. Pedicled ALT flap is more useful as compared to free flaps especially in high-risk groups where a failure of free flap will lead to complete necrosis of the flap whereas pedicled flaps can escape with partial necrosis even if some complications arise.

Statistical analysis suggests that patients undergoing partition technique have a higher risk of postoperative complications if the fascia defect size is larger than 11.35 cm²⁷. Therefore, the partition technique is indicated in patients with delayed abdominal wall reconstruction (more than 6 months since exploratory laparotomy) and fascia defect size smaller than 11.35 cm. The pedicled ALT flap for abdominal wall closure expands abdominal volume, preserves the blood supply to the abdominal wall, and decreases the risks of compartment syndrome; therefore, the flap is an option for immediate abdominal wall reconstruction for patients with major trauma, abdominal wall defect due to deep and wide excision²⁸, delayed abdominal reconstruction (less than 6 months since exploratory laparotomy), and delayed abdominal reconstruction (more than 6 months since exploratory laparotomy) with fascia defect size larger than 11.35 cm.

In our study we have used fasciocutaneous pedicled ALT flap with tensor fascia lata in patients with full thickness defects so as to have extra support to the abdominal wall.

One patient in our study developed incisional hernia and was treated by mesh hernioplasty. One patient developed hypertrophic scarring and after waiting for 3 months, triamcinolone injection in scar was give thrice at 3 weeks interval, following which the scar settled. All patients were advised to wear abdominal binders for 6 months.

CONCLUSION

Pedicled ALT flap has expanded the armamentarium of plastic surgeons for reconstruction of abdominal wall defects.

ACKNOWLEDGMENTS

This study did not receive any funding.

CONFLICT OF INTEREST

The authors declare no conflict of interest.

REFERENCES

- Gottlieb JR, Engrav LH, Walkinshaw MD, Eddy AC, Herman CM. Upper abdominal wall defects: Immediate or staged reconstruction? *Plast Reconstr Surg* 1990;**86**(2): 281-286. PMID: 2142309. DOI: 10.1097/00006534-199008000-00013
- DeFranzo AJ, Kingman GJ, Sterchi JM, Marks MW, Thorne MT. Rectus turnover flaps for the reconstruction of large midline abdominal wall defects. *Ann Plast Surg* 1996;**37**(1): 18-23. PMID: 8826587. DOI: 10.1097/00000637-199607000-00003
- Ninkovic M, Kronberger P, Harpf C, Rumer A, Anderl H. Free innervated latissimus dorsi muscle flap for reconstruction of full-thickness abdominal wall defects. *Plast Reconstr Surg* 1998;**101**(4): 971-978. PMID: 9514329. DOI: 10.1097/00006534-199804040-00013
- Mathes SJ, Steinwald PM, Foster RD, Hoffman WY, Anthony JP. Complex abdominal wall reconstruction: A comparison of flap and mesh closure. *Ann Surg* 2000;**232**(4): 586-596. PMID: 10998657. DOI: 10.1097/00006534-200010000-00014
- Khansa I, Janis JE. Modern reconstructive techniques for abdominal wall defects after oncologic resection. *J Surg Oncol* 2015;**111**(5): 587-598. PMID: 25371050. DOI: 10.1002/jso.23824
- Gopinathan R, Granick M. Anterior abdominal wall reconstruction. *Clin Plast Surg* 2006 Apr;**33**(2):259-67. doi: 10.1016/j.cps.2005.12.006. PMID: 16638468.
- Butler CE, Baumann DP, Janis JE, Rosen MJ. Abdominal wall reconstruction. *Curr Probl Surg* 2013;**50**(12): 557-586. PMID: 24231005. DOI: 10.1067/j.cpsurg.2013.08.003
- Ghazi B, Deigni O, Yezhelyev M, Losken A. Current options in the management of complex abdominal wall defects. *Ann Plast Surg* 2011;**66**(5): 488-492. PMID: 21372667. DOI: 10.1097/SAP.0b013e31820d18db
- Kimata Y, Uchiyama K, Sekido M, et al. Anterolateral thigh flap for abdominal wall reconstruction. *Plast Reconstr Surg* 1999;**103**(4):1191-1197.
- Neligan PC, Lannon DA. Versatility of the pedicled anterolateral thigh flap. *Clin Plast Surg* 2010;**37**(4):677-681 vii.
- Ng RW, Chan JY, Mok V, et al. Clinical use of a pedicled anterolateral thigh flap. *J Plast Reconstr Aesthet Surg* 2008;**61**(2):158-164.
- Kimata Y, Uchiyama K, Ebihara S, et al. Anatomic variations and technical problems of the anterolateral thigh flap: a report of 7 cases. *Plast Reconstr Surg* 1998; **1-2**(5):1517-1523.
- Lin CT, Wang CH, Ou KW, et al. Clinical applications of the pedicled anterolateral thigh flap in reconstruction. *ANZ J Surg* 2017;**87**(6):499-504.
- Althubaiti G and Butler CE. Abdominal wall and chest wall reconstruction. *Plast Reconstr Surg* 2014;**133**(5): 688e-701e. PMID: 24776572. DOI: 10.1097/PRS.0000000000000086
- Kushimoto S, Yamamoto Y, Aiboshi J, Ogawa F, Koido Y, Yoshida R, Kawai M. Usefulness of the bilateral anterior rectus abdominis sheath turnover flap method for early fascial closure in patients requiring open abdominal management. *World J Surg* 2007;**31**(1): 2-8; discussion 9-10. PMID: 17103095. DOI: 10.1007/s00268-006-0282-3
- Vranckx JJ, Stoel AM, Segers K and Nanhekhan L. Dynamic reconstruction of complex abdominal wall defects with the pedicled innervated vastus lateralis and anterolateral thigh piva flap. *J Plast Reconstr Aesthet Surg* 2015;**68**(6): 837-845. PMID: 25964228. DOI: 10.1016/j.bjps.2015.03.009
- Kuo YR, Kuo MH, Lutz BS, Huang YC, Liu YT, Wu SC, Hsieh KC, Hsien CH, Jeng SF. One-stage reconstruction of large midline abdominal wall defects using a composite free anterolateral thigh flap with vascularized fascia lata. *Ann Surg* 2004;**239**(3): 352-358. PMID: 15075651. DOI: 10.1097/01.sla.0000114229.89940.e8
- Song YG, Chen GZ and Song YL. The free thigh flap: A new free flap concept based on the septocutaneous artery. *Br J Plast Surg* 1984;**37**(2): 149-159. PMID: 6713155. DOI: 10.1016/0007-1226(84)90002-x
- Wei FC, Jain V, Celik N, Chen HC, Chuang DC and Lin CH. Have we found an ideal soft-tissue flap? An experience with 672 anterolateral thigh flaps. *Plast Reconstr Surg* 2002;**109**(7): 2219-2226; discussion 2227-2230. PMID: 12045540. DOI: 10.1097/00006534-200206000-00007
- Medgyesi S. A successful operation for lymphoedema using a myocutaneous flap as a "wick". *Br J Plast Surg* 1983;**36**(1): 64-66. PMID: 6821730. DOI: 10.1016/0007-1226(83)90014-0
- Fernandez-Alvarez JA, Barrera-Pulido F, Lagares-Borrego A, Narros-Gimenez R, Gacto-Sanchez P, Gomez-Cia T. Coverage of supraumbilical abdominal wall defects: The tunnelled-pedicled alt technique. *Microsurgery* 2017;**37**(2): 119-127. PMID: 26109324. DOI: 10.1002/micr.22437
- Zelken JA, AlDeek NF, Hsu CC, Chang NJ, Lin CH and Lin CH. Algorithmic approach to lower

- abdominal, perineal, and groin reconstruction using anterolateral thigh flaps. *Microsurgery* 2016;**36**(2): 104-114. PMID: 25487137. DOI: 10.1002/micr.22354
23. Lv Y, Cao D, Guo F, Qian Y, Wang C and Wang D. Abdominal wall reconstruction using a combination of free tensor fasciae lata and anterolateral thigh myocutaneous flap: A prospective study in 16 patients. *Am J Surg* **210**(2): 365-373, 2015. PMID: 25824825. DOI: 10.1016/j.amjsurg.2014.11.008
 24. Friji MT, Suri MP, Shankhdhar VK, et al. Pedicled anterolateral thigh flap: a versatile flap for difficult regional soft tissue reconstruction. *Ann Plast Surg* 2010; **64**(4):458-461.
 25. Kayano S, Sakuraba M, Miyamoto S, et al. Comparison of pedicled and free anterolateral thigh flaps for reconstruction of complex defects of the abdominal wall: review of 20 consecutive cases. *J Plast Reconstr Aesthet Surg* 2012;**65**(11):1525-1529.
 26. Wei FC, Celik N. Perforator flap entity. *Clin Plast Surg* 2003;**30**:325-329.
 27. Shih PK, Cheng HT, Liu KW, Chen HH. Partition technique in management of difficult abdominal fascia closure. *Formosan J Surg* 2013; **46**:149-156.
 28. Zhang A, Kuc A, Smith P, Zimmerman A, Billington A, Gonzalez RJ, Dayicioglu D. Large chest and abdominal wall defect reconstruction with anterolateral thigh free flap to right gastroepiploic artery anastomosis. *Eplasty* 2017; **17**:ic24.