

## A case of *de novo* dynamin 2 (DNM2)-related centronuclear myopathy with electrical but not clinical myotonia

Xiao Huang<sup>1,2</sup>, Xiang-Yi Liu<sup>1,2</sup>, Lu Chen<sup>1,2</sup>, A-Ping Sun<sup>1,2</sup>, Ying-Shuang Zhang<sup>1,2</sup>, Dan-Feng Zheng<sup>2,3</sup>, Yan-Feng Zhong<sup>2,3</sup>, Dong-Sheng Fan<sup>1,2,4</sup>

<sup>1</sup>Department of Neurology, Peking University Third Hospital, Beijing 100191, China;

<sup>2</sup>Beijing Municipal Key Laboratory of Biomarker and Translational Research in Neurodegenerative diseases, Beijing 100191, China;

<sup>3</sup>Department of Pathology, School of Basic Medical Sciences, Peking University, Beijing 100191, China;

<sup>4</sup>Key Laboratory for Neuroscience, National Health Commission/Ministry of Education, Peking University, Beijing 100191, China.

*To the Editor:* A 39-year-old man presented with progressive limb atrophy and weakness. The patient had generalized muscular hypotonia at birth; he could not run well in elementary school. Neurologic examination revealed atrophy of the facial muscles and limited left eye adduction. In the upper limbs, the patients showed proximal muscle atrophy and weakness [Figure 1A], while in the lower extremities, the weakness was more prominent distally than proximally. Neither spontaneous or percussion myotonia nor muscle hypertrophy was observed.

Serum creatine kinase was mildly elevated, 223 IU/L (normal value < 170). In the electrophysiologic examinations, motor and sensory conduction studies were normal; needle electromyogram showed fibrillation and positive sharp waves; in addition, numerous myotonic discharges were noted, and they waxed and waned with variations in amplitude and frequency [Figure 1B]. Motor unit potentials of the first dorsal interosseous, tibialis anterior, and quadriceps femoris were of short duration and low amplitude, with early recruitments.

Muscle biopsy from the left biceps brachii showed central nuclei in almost all muscle fibers. Nicotinamide dehydrogenase tetrazolium reductase staining revealed increased perinuclear oxidative activity and sarcoplasmic strands radiating from the central nucleus conferring a spoke-like appearance, which was also observed in immunohistochemical desmin and vimentin staining [Figure 1 C–F].

Genetic evaluation revealed a heterozygous c.1565G>A substitution in dynamin 2 (DNM2) [Figure 1G], resulting in R522H amino acid change in dynamin-2, which was previously reported to be pathogenic.<sup>[1,2]</sup> The patient's

parents showed no variations in this nucleotide site, revealing that the patient carried a *de novo* mutation.

Mutations in *DNM2* are rare, and have been found to be associated with centronuclear myopathy (CNM) and Charcot-Marie-Tooth disease.<sup>[1]</sup> Our patient had ophthalmoparesis, facial and limb atrophy, and weakness, and electrophysiologic study showed myogenic impairment without nerve conduction abnormalities, revealing a pure CNM phenotype.

Myotonia is a defining clinical symptom and sign common to a relatively small group of muscle diseases, including the myotonic dystrophies and the non-dystrophic myotonic disorders. Myotonic discharge without clinical myotonia can be seen in polymyositis, acid maltase deficiency, and so on.<sup>[3]</sup> In 1978, Gil-Peralta *et al*<sup>[4]</sup> firstly reported clinical myotonia in a case of CNM, while during the same period, CNM cases with electrical myotonia have been reported. Although these cases had no genetic tests to identify the casual gene, they were distinct from dystrophic myotonia due to the clinical and pathologic presentations. In 2018, Stino and Iyadurai reported a patient presenting electrical but not clinical myotonia, carrying the same mutation (R522H) on the *DNM2* gene; however, the patient did not undergo muscle biopsy evaluation.<sup>[1]</sup> It is worth noting that the same mutation has also been reported in two CNM patient cohorts, who showed neither clinical nor electrical myotonia.<sup>[2,5]</sup>

In summary, our study further confirms that *DNM2*-related CNM may present electrical without clinical myotonia. According to the function of *DNM2* protein and the morphologic change in immunohistochemical desmin and vimentin staining, we presume that the

Access this article online

Quick Response Code:



Website:  
www.cmj.org

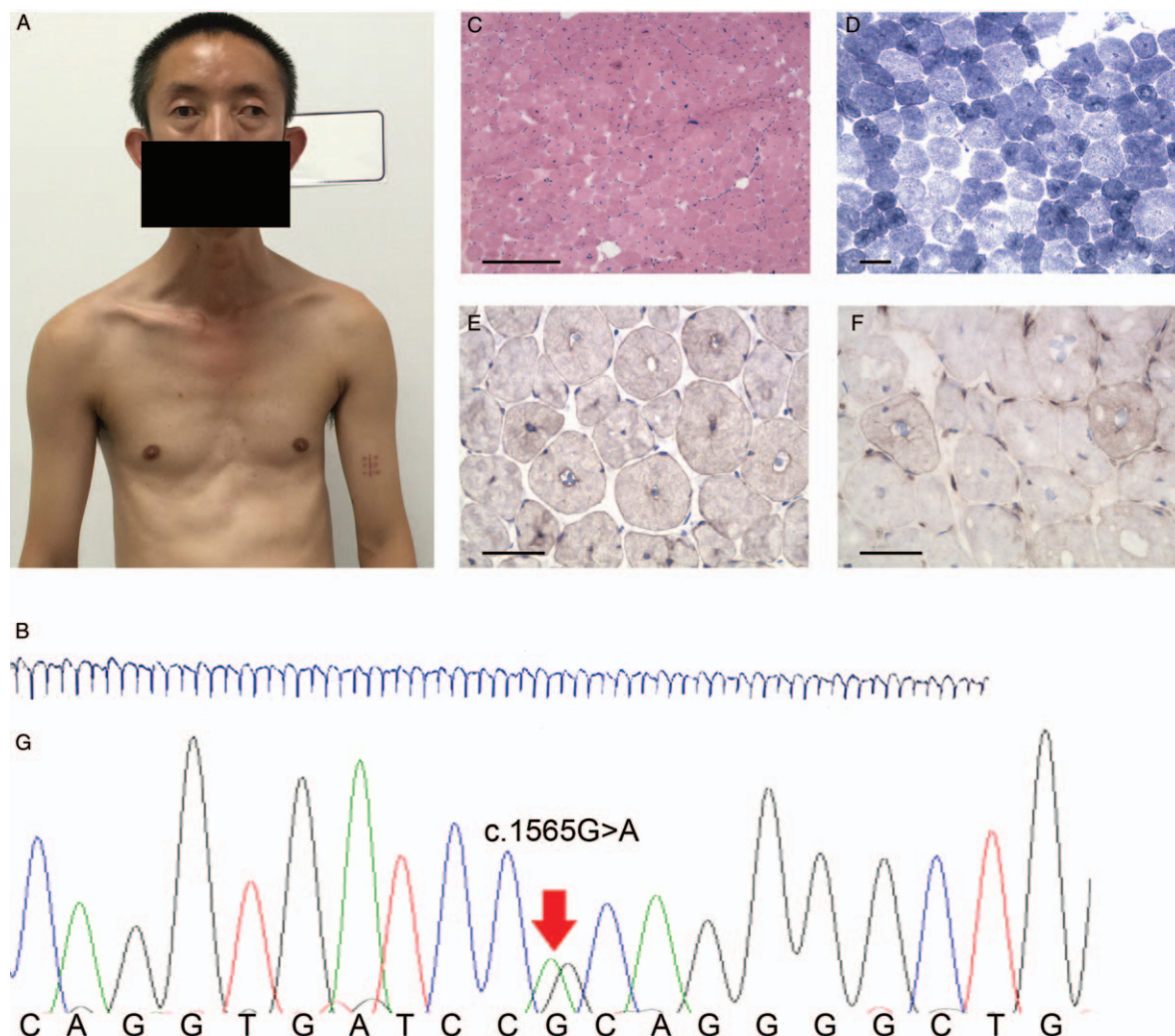
DOI:  
10.1097/CM9.0000000000000974

**Correspondence to:** Prof. Dong-Sheng Fan, Department of Neurology, Peking University Third Hospital, No. 49, North Garden Road, Haidian District, Beijing 100191, China  
E-Mail: dsfan2010@aliyun.com

Copyright © 2020 The Chinese Medical Association, produced by Wolters Kluwer, Inc. under the CC-BY-NC-ND license. This is an open access article distributed under the terms of the Creative Commons Attribution-Non Commercial-No Derivatives License 4.0 (CCBY-NC-ND), where it is permissible to download and share the work provided it is properly cited. The work cannot be changed in any way or used commercially without permission from the journal.

Chinese Medical Journal 2020;133(24)

Received: 02-02-2020 Edited by: Li-Shao Guo



**Figure 1:** (A) The patient showed extensive muscular atrophy of facial and limb. The left eye is fixed at abduction position. (B) Needle electromyogram showed myotonic discharges. (C) Central nuclei in almost all muscle fibers (hematoxylin-eosin staining, scale bars: 500  $\mu$ m). (D–F) Nicotinamide dehydrogenase tetrazolium reductase staining shows slightly type 1 fiber predominance and hypotrophy. The perinuclear oxidative activity increase and sarcoplasmic strands radiate from the central nucleus conferring a spoke-like appearance, which is also revealed in immunohistochemical desmin and vimentin staining (scale bars: 100  $\mu$ m). (G) Sequence electropherogram demonstrating a heterozygous c.1565G>A substitution in *DNM2*. *DNM2*: Dynamin 2.

myotonia may result from the impairment of cytoskeleton networks and membrane modulation. Further study is needed to clarify the mechanism of the myotonic discharge of *DNM2*-related CNM.

#### Declaration of patient consent

The authors certify that they have obtained the appropriate patient consent form. In the form, the patient provided his consent for his images and other clinical information to be reported in the journal. The patient understands that his name and initials will not be published and that due efforts will be made to conceal his identity but that anonymity cannot be guaranteed.

#### Conflicts of interest

None.

#### References

1. Stino AM, Iyadurai SJ. Dynamin-2-associated myopathy with electrical but not clinical myotonia. *Muscle Nerve* 2018;57:E118–E120. doi: 10.1002/mus.26006.
2. Chen T, Pu C, Wang Q, Liu J, Mao Y, Shi Q. Clinical, pathological, and genetic features of dynamin-2-related centronuclear myopathy in China. *Neurol Sci* 2015;36:735–741. doi: 10.1007/s10072-014-2028-6.
3. Heatwole CR, Statland JM, Logigian EL. The diagnosis and treatment of myotonic disorders. *Muscle Nerve* 2013;47:632–648. doi: 10.1002/mus.23683.
4. Gil-Peralta A, Rafel E, Bautista J, Alberca R. Myotonia in centronuclear myopathy. *J Neurol Neurosurg Psychiatry* 1978; 41:1102–1108. doi: 10.1136/jnnp.41.12.1102.
5. Susman RD, Quijano-Roy S, Yang N, Webster R, Clarke NF, Dowling J, *et al*. Expanding the clinical, pathological and MRI phenotype of *DNM2*-related centronuclear myopathy. *Neuromuscul Disord* 2010; 20:229–237. doi: 10.1016/j.nmd.2010.02.016.

**How to cite this article:** Huang X, Liu XY, Chen L, Sun AP, Zhang YS, Zheng DF, Zhong YF, Fan DS. A case of *de novo* dynamin 2-related centronuclear myopathy with electrical but not clinical myotonia. *Chin Med J* 2020;133:3023–3024. doi: 10.1097/CM9.0000000000000974