






# Synchronized diaphragmatic stimulation: a case report of a novel extra-cardiac intervention for chronic heart failure

Lee R. Goldberg<sup>1\*</sup> , Ana Jorbenadze<sup>2</sup>, Tamaz Shaburishvili<sup>2</sup>, Michael J. Mirro<sup>3</sup> , Marat Fudim<sup>4</sup> , Michel Zuber<sup>5</sup>, Simon F. Stämpfli<sup>6</sup> , Felix C. Tanner<sup>7</sup>, Paul Erne<sup>8</sup> and John G. Cleland<sup>9</sup> 

<sup>1</sup>Section of Advanced Heart Failure and Cardiac Transplant, Division of Cardiovascular Medicine, Perelman School of Medicine, University of Pennsylvania, 3400 Civic Center Boulevard, 11-171 South Tower, Philadelphia, PA 19104, USA; <sup>2</sup>Heart and Vascular Clinic, Tbilisi, Republic of Georgia; <sup>3</sup>Indiana University and Parkview Health, Fort Wayne, IN, USA; <sup>4</sup>Department of Medicine, Duke University Medical Center, Durham, NC, USA; <sup>5</sup>Heart Center, Kantonsspital, Aarau, Switzerland; <sup>6</sup>Heart Center, University Hospital, Zürich and Heart Center, Luzerner Kantonsspital, Lucerne, Switzerland; and <sup>7</sup>Heart Center, University Hospital, Zürich, Switzerland; <sup>8</sup>Faculty of Biomedical Sciences, Università della Svizzera Italiana, Lugano, Switzerland; <sup>9</sup>Robertson Centre for Biostatistics, University of Glasgow, Glasgow, UK

## Abstract

Synchronized diaphragmatic stimulation (SDS) is a novel extra-cardiac device-based therapy for symptomatic heart failure with reduced ejection fraction. SDS provides imperceptible chronic stimulation of the diaphragm through a laparoscopically implanted system consisting of an implantable pulse generator and two sensing/stimulating leads affixed to the inferior surface of the diaphragm delivering imperceptible R-wave gaited pulses that alter intrathoracic pressure improving ventricular filling and cardiac output. We describe, in a man with a history of myocardial infarctions resulting in heart failure and persistent New York Heart Association Class III symptoms despite standard therapies, the successful implantation of SDS resulting in improved quality of life, N-terminal pro brain natriuretic peptide, cardiac function, and exercise tolerance through 12 months of follow-up. Randomized trials are now required to validate these findings.

**Keywords** Congestive heart failure; Synchronized diaphragmatic stimulation; Acute cardiac haemodynamics

Received: 13 October 2021; Revised: 2 February 2022; Accepted: 28 February 2022

\*Correspondence to: Lee R. Goldberg, Section of Advanced Heart Failure and Cardiac Transplant, Division of Cardiovascular Medicine, Perelman School of Medicine, University of Pennsylvania, 3400 Civic Center Boulevard, 11-171 South Tower, Philadelphia, PA 19104, USA. Fax: 215-615-0820; 215-615-0828. Email: lee.goldberg@pennmedicine.upenn.edu

## Introduction

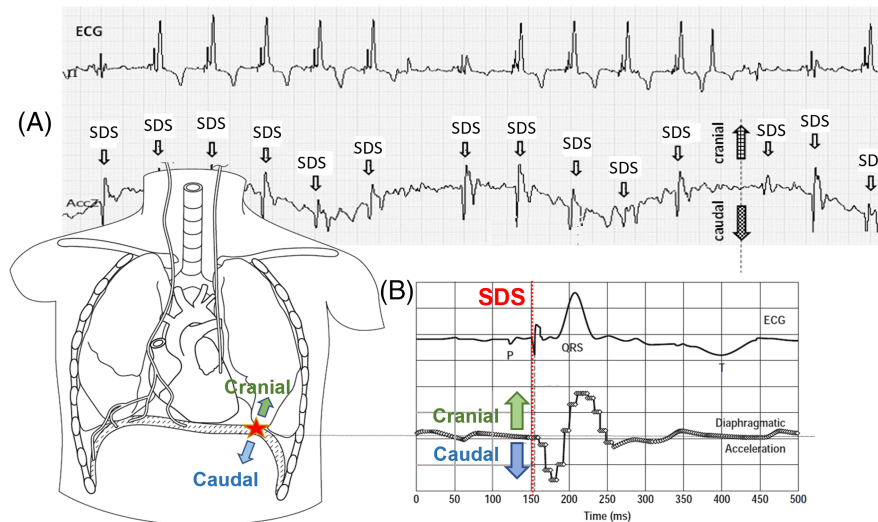
Synchronized diaphragmatic stimulation (SDS) is under investigation for patients with symptomatic heart failure and reduced left ventricular ejection fraction (LVEF) who are not candidates for cardiac resynchronization therapy due to degree of QRS prolongation or vascular access. Chronic stimulation of the diaphragm is provided by a system consisting of an implantable pulse generator (IPG) and two sensing/stimulating leads affixed to the diaphragm. The IPG delivers imperceptible R-wave gaited pulses (Figure 1) that alter intrathoracic pressures thereby improving ventricular filling and cardiac output. A system for delivering SDS (VisCardia Inc., Portland, OR) that allows minimally invasive implantation has been studied in a pilot study (NCT0348470), in which this patient participated.<sup>1,2</sup> This study was approved by the Ethics

Committee of Tbilisi Heart and Vascular Clinic 18/20 Ljublijana Str., Tbilisi 0159, Georgia.

## Case report

A 58-year-old man with past history of ischaemic cardiomyopathy and LVEF of 30% presented with worsening dyspnoea on exertion. On examination, his heart rate was 80 bpm, blood pressure 134/79 mmHg, a mild audible diastolic murmur but no abnormal heart sounds or jugular venous distention. His lungs were clear with good air movement bilaterally and no rales. A 12-lead ECG showed sinus rhythm, normal QRS duration but poor R-wave progression. His medications included torsemide, spironolactone, carvedilol,

**Figure 1** SDS stimulation and localized diaphragmatic acceleration. (A) Simultaneous recording of ECG and acceleration from probes attached to the diaphragm. SDS leads to short biphasic diaphragm movements superimposed onto the respiratory cycle. (B) Single beat recording of ECG and acceleration. SDS produces a caudal movement of the diaphragm (blue arrows) that is followed by a cranial rebound (green arrows). ECG, electrocardiogram; SDS, synchronized diaphragmatic stimulation.



a combination of perindopril, amlodipine and indapamide (thiazide), as well as aspirin and atorvastatin.

The patient had myocardial infarctions 18 and 20 years prior to enrolment involving the anterior wall of the left ventricle. He was found to be hypertensive 11 years prior to enrolment and his medical regimen was adjusted. Six years prior to enrolment, he underwent coronary artery bypass grafting (left internal mammary to the left anterior descending artery; saphenous vein graft to the posterior descending artery). A transthoracic echocardiogram shortly before enrolment showed moderate left ventricular hypertrophy and dilatation, moderate aortic regurgitation, mild mitral regurgitation, and an LVEF of 30%. Despite guideline directed medical therapy for over 1 year, the patient remained symptomatic exhibiting on-going dyspnoea with moderate exertion and fatigue consistent with New York Heart Association (NYHA) Class III symptoms.

Results of the patient's laboratory tests were as follows: serum creatinine, 1.38 mg/dL (normal, <1.2 mg/dL); haemoglobin, 153 g/L (normal, 126–174 g/L); and NT-proBNP, 1779 pg/mL (normal, <125 pg/mL). Spirometry revealed mild restriction (forced vital capacity 3.25 L, forced expiratory volume in 1 s 2.71 L, forced vital capacity ratio 83%). To establish exercise tolerance, a 6 min walk test was performed (start/end heart rate 80/99 bpm, start/end SpO<sub>2</sub> 97/91%, distance 302 m). The 6 min walk test was consistent with NYHA functional class III.

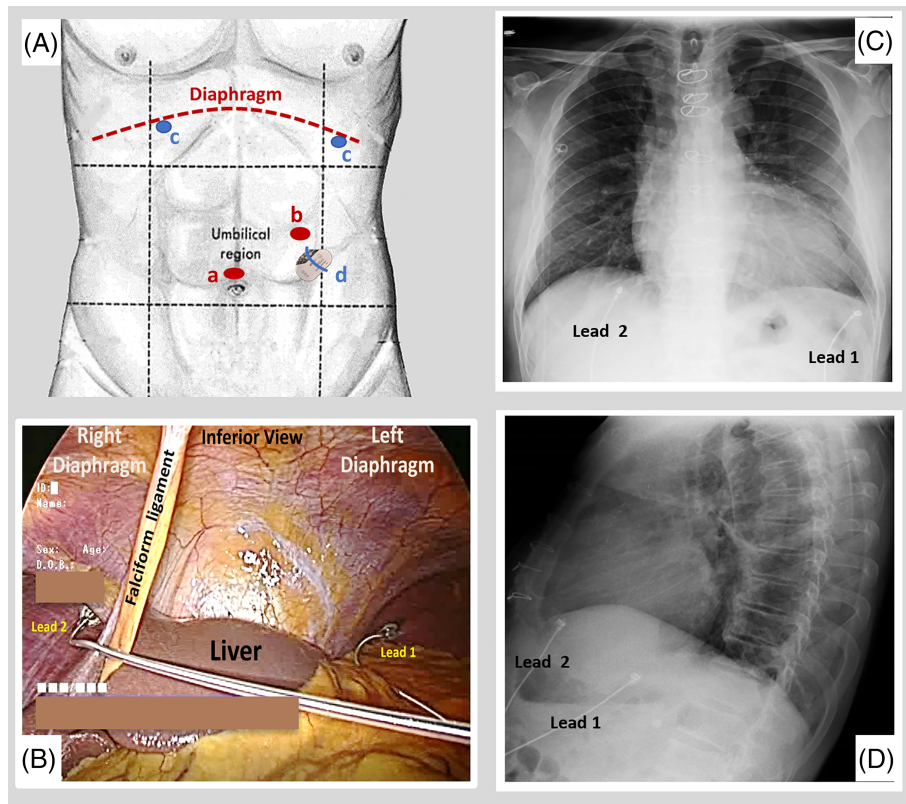
Based on the patient's history of heart failure with reduced LVEF (HFrEF) and declining exercise tolerance and quality of life (QOL), despite maximally tolerated guideline directed

medical therapy, the patient was invited to participate in a non-randomized, pilot study investigating the technical feasibility of SDS implantation. The patient consented to the study as previous therapy including coronary artery bypass grafting and current GDMT therapy had not adequately controlled his symptoms, and he did not qualify for alternative therapies including cardiac resynchronization therapy or valve interventions.

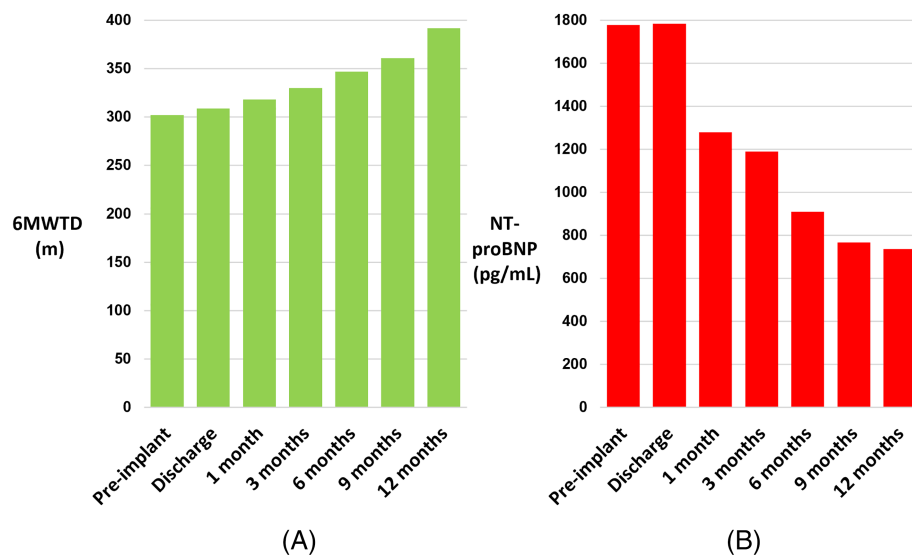
The SDS system was implanted via minimally invasive abdominal access, *Figure 2A*. A small midline incision (location a) was made to place the trocar and laparoscope. The abdomen was insufflated to allow adequate visualization of the diaphragm. Another small incision was made laterally (location b) to place another trocar through which the sensing/stimulating leads were inserted and attached to the left and right hemispheres of the diaphragm (locations c). A laparoscopic view of the sensing/stimulating leads is provided in panel B. A subcutaneous pocket was created for the IPG (panel A, location d) and the leads tunneled to connect to the IPG. Sensing thresholds were tested for adequate performance, and the diaphragmatic capture threshold was determined. The abdomen was desufflated, and all incisions were closed. Chest X-rays were taken to document lead placement (panels C and D). Prior to discharge on post-operative Day 2, device performance was confirmed and the therapy activated to deliver SDS therapy at an asymptomatic threshold.

The patient was evaluated at 3, 6, and 12 months post-discharge for QOL using SF-36 (Short Form Health Survey), spirometry, exercise tolerance, and echocardiography. *Figure 3* illustrates changes in 6 min walk distance (panel

**Figure 2** Minimally invasive SDS placement. (A) Laparoscopic access points: a, midline incision for trocar and camera; b, lateral incision for trocar and leads; c, location of leads placed on the diaphragm (red dashed line); d, location of IPG pocket. (B) Laparoscopic view of bilateral diaphragmatic lead locations. (C) Posteroanterior radiographic view of leads. (D) Left lateral radiographic view of leads.



**Figure 3** Chronic impact of SDS. Change over 12 months. (A) 6 MWTD, 6 min walk test distance (metres). (B) NT-proBNP (pg/mL). 6MWTD, 6 min walk test distance; NT-proBNP, N-terminal pro brain natriuretic peptide.



A, pre-implant = 302 to 12 month = 392 m) and NT-proBNP (panel B, screen = 1779 to 12 month = 736 pg/mL) over time. Substantial improvements occurred in LVEF (pre-implant = 28% vs. 12 month = 51%), and SF-36 QOL measures (role physical, pre-implant = 0 vs. 12 month = 25; role emotional, pre-implant = 0 vs. 12 month = 67) while no deterioration was seen in respiratory function (*Table 1* and *Figure 4*).

## Discussion

Heart failure is often associated with debilitating symptoms, recurrent hospitalizations, and a poor prognosis. Although innovations in pharmacological and device therapy have improved the outlook for many patients with HFrEF, there is still a need for further treatments that are effective for improving symptoms and/or prognosis, safe, minimally invasive or non-invasive, non-burdensome, and affordable. Despite appropriate pharmacological therapy,<sup>3</sup> this patient had worsening QOL, decreasing ability to perform daily activities and

frequent acute heart failure episodes. Following placement of the SDS system, the patient experienced improved clinical status and improved LVEF.

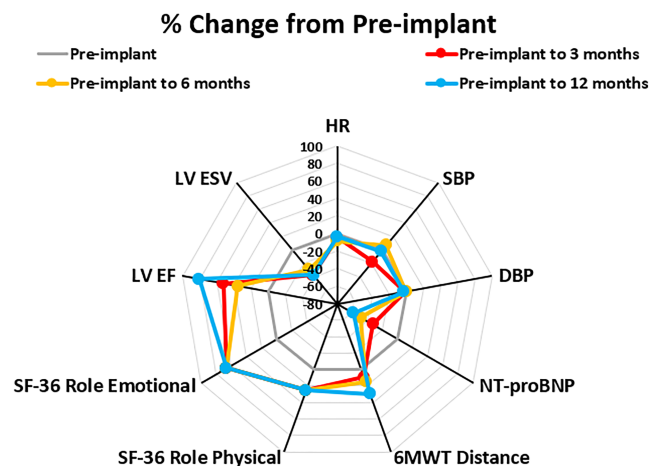
The mechanism of action of the SDS system on improved cardiovascular symptoms is unknown, but one hypothesis is the impact of diaphragmatic pacing on intrathoracic pressures translating to changes in ventricular pre-load, after-load, and pericardial restraint. Electrical stimulation of the diaphragm causes a contraction that transiently modulates intrathoracic pressure in a biphasic manner (*Figure 1*), which is imperceptible by the patient.<sup>4</sup> Changes in intrathoracic pressure due to diaphragmatic movement are known to affect haemodynamics and cardiac loading, such as during respiration. Inspiration reduces intrathoracic pressure while increasing intra-abdominal pressure resulting in increased systemic venous return and pulmonary venous capacitance. During inspiration, right atrial and right ventricular volume increase while left atrial and left ventricular volume decrease. During expiration, increased intrathoracic pressure results in the reduced right-sided volumes and increased left-sided volumes. More recently, there has been increased interest in the impact of intrathoracic pressure changes on pericardial

**Table 1** Change over 12 months

	HR (bpm)	SBP (mmHg)	DBP (mmHg)	6MWT (m)	NT-proBNP (pg/mL)	EF (%)	ESV (mL)	FEV1 (L)	FVC (L)	SF-36 role, physical	SF-36 role, emotional
Pre-implant	82	129	69	302	1779	28	162	2.7	3.3	0	0
3 months	78	106	68	330	1190	43	102	2.5	3.0	25	67
6 months	75	138	69	347	910	39	115	2.7	3.2	25	67
12 months	79	126	67	392	736	51	101	2.7	3.3	25	67

6MWT, 6 min walk test distance; DBP, diastolic blood pressure; EF, left ventricular ejection fraction; ESV, left ventricular end-systolic volume; FEV1, forced expiratory volume in 1 second; FVC, forced vital capacity; HR, heart rate; SBP, systolic blood pressure; SF-36, Short Form Health Survey.

**Figure 4** Percent change from pre-implant to 12 months. Percent change from pre-implant value. 6MWT Distance, 6 min walk test distance; DBP, diastolic blood pressure; HR, heart rate; LV EF, left ventricular ejection fraction; LV ESV, left ventricular end-systolic volume; SBP, systolic blood pressure.





restraint.<sup>5</sup> Stimulation of the diaphragm leads to reduced pericardial restraint and a reduction in ventricular wall stress, which could improve cardiac filling conditions and systolic performance.

Several research groups have independently demonstrated that even short transient, non-respiratory intrathoracic pressure changes such as due to hiccoughs, controlled phrenic nerve stimulation or respirator bursts, affects cardiac and large vessel pressures and flows.<sup>6–8</sup> Using a temporary pacing lead attached to the diaphragm, Roos *et al.*<sup>9</sup> demonstrated the ability to stimulate, asymptotically, the diaphragm in 35 patients leading to reproducible acute improvements to cardiac function. The effects of chronic SDS were investigated in patients after coronary artery bypass grafting with a pacing lead attached to the diaphragm.<sup>10</sup> Patients ( $n = 24$ ) were randomized in a crossover trial with 3-week treatment periods. Symptoms, exercise tolerance, and echocardiographic parameters were assessed at the end of each period. With timing-optimized SDS, LVEF increased and NYHA class and exercise performance improved. Some patients were followed for 1 year ( $n = 17$ ),<sup>11</sup> and the improvements in LVEF were sustained in those without comorbid respiratory disease (e.g. COPD).

Synchronized diaphragmatic stimulation, a new device-based intervention for symptomatic HFrEF, appears promising when guideline directed medical therapy does not adequately control symptoms. This case report highlights the clinical response to SDS after 1 year of follow-up in one of the first patients to receive this therapy. Randomized trials are now required to validate these findings.

## Conflict of interest

T. Shaburishvili received grant/research support and M. Mirro received stock options from VisCardia and is the Medical Director of VisCardia. L. Goldberg and M. Fudim are consultants to VisCardia.

## Funding

The Stiftung fuer Herz und Kreislaufkrankheiten (SHK), Switzerland, and VisCardia, Inc., Portland, OR, USA, funded the clinical study including the device involved in this case report.

## References

- Zuber M, Young R, Shaburishvili T, Rudenko K, Demyanchuk V, Jorbenadze A, Buriak R, Todurov B, Mirro M, Nikitin N. First-in-human VisONE heart failure study implant experience and study design: asymptomatic diaphragmatic stimulation for chronic heart failure. *Eur J Heart Fail.* 2019; **21**: P523–P524.
- Zuber M, Young R, Shaburishvili T, Rudenko K, Demyanchuk V, Jorbenadze A, Buriak R, Todurov B, Mirro M, Staempfli S, Tanner F, Erne P, McMonnachie A, Cleland JGF. First in human VisONE heart failure study: asymptomatic diaphragmatic stimulation for chronic heart failure: one month results. *J Card Fail.* 2019; **25**: S183.
- Yancy CW, Jessup M, Bozkurt B, Butler J, Casey DE, Drazner MH, Fonarow GC, Geraci SA, Horwich T, Januzzi JL, Johnson MR. 2013 ACCF/AHA guideline for the management of heart failure. *Circ.* 2013; **128**: 240–327.
- Toggweiler S, Kobza R, Roos M, Erne P. Visualizing pacemaker-induced phrenic nerve stimulation with acoustic cardiography. *Pacing Clin Electrophysiol.* 2007; Jun;Vol: 30:806.
- Borlaug BA, Reddy YNV. The role of the pericardium in heart failure: implications for pathophysiology and treatment. *JACC Heart Fail.* 2019; **7**: 574–585.
- Peters J, Kindred MK, Robotham JL. Transient analysis of cardiopulmonary interactions I. Diastolic events. *J Appl Physiol.* 1988; **64**: 1506–1517.
- Peters J, Kindred MK, Robotham JL. Transient analysis of cardiopulmonary interactions I. Systolic events. *J Appl Physiol.* 1988; **64**: 1518–1526.
- Pinsky MR, Marquez J, Martin D, Klain M. Ventricular assist by cardiac cycle-specific increases in intrathoracic pressure. *Chest.* 1987; **91**: 709–715.
- Roos M, Kobza R, Jamshidi P, Bauer P, Resink T, Schlaepfer R, Stulz P, Zuber M, Erne P. Improved cardiac performance through pacing-induced diaphragmatic stimulation: a novel electrophysiological approach in heart failure management? *Europace.* 2009; **11**: 191–199.
- Beeler R, Schoenenberger AW, Bauer P, Kobza R, Bergner M, Mueller X, Schlaepfer R, Zuber M, Erne S, Erne P. Improvement of cardiac function with device-based diaphragmatic stimulation in chronic heart failure patients. *Eur J Heart Failure.* 2014; **16**: 342–349.
- Beeler R, Schoenenberger A, Zuber M, Bauer P, Bergner M, Erne S, Schlaepfer R, Erne P. Sustained improvements to ventricular function due to asymptomatic diaphragmatic function. *Eur Heart J Cardiovasc Pharmacother.* 2017; **38**: ehx504.P3374.