

# Oral exfoliative cytology as a screening tool for iron overload in $\beta$ -thalassemia patients

Ajit Singh Rathore, Neha Keshri, Devi Charan Shetty, Saurabh Juneja

Department of Oral Pathology, I.T.S. Dental College, Ghaziabad, Uttar Pradesh, India

## ABSTRACT

**Background:** Increased iron overload is frequent problem in thalassemia patients, and this is monitored by serum ferritin levels or chemical assessment of the iron levels in liver tissue. However, repeated monitoring of serum ferritin levels to assess the iron overload is an invasive procedure associated with practical problems. **Aims:** To use Perl's Prussian blue reaction to evaluate the iron overload in beta-thalassemia patients by staining the oral cytosmears. **Materials and Methods:** The study comprised 35 patients diagnosed with beta-thalassemia. Cytosmears were prepared from exfoliated oral epithelial cells, fixed in 70% ethanol and stained with Perl's Prussian blue stain for detection of blue colored granules in the cytoplasm. **Results:** 29/35 (82.9%) cases showed a positive reaction for Perl's Prussian blue reaction while 6/35 (17%) cases did not show the presence of blue colored granules in the oral cytosmears. The presence of iron detected by Perl's Prussian blue reaction correlated with serum ferritin level ( $P < 0.05$ ). **Conclusion:** Perl's Prussian blue reaction can be used to evaluate the iron overload in beta-thalassemia patients by staining the oral cytosmears. It is a simple and noninvasive method for assessment of iron overload in such patients.

**Key words:** Beta thalassemia, cytology, iron overload, Prussian blue

**Submission:** 15-05-2015 **Accepted:** 23-09-2015

## INTRODUCTION

The thalassemias are a group of hemoglobinopathies characterized by a deficient synthesis of protein chains (either  $\alpha$  or the  $\beta$ ) of globin in the hemoglobin molecule.<sup>[1]</sup> Affected individuals are either heterozygotes, homozygotes, or compound heterozygotes for the  $\alpha$ - or  $\beta$ -chain genes. The heterozygous individual are known as having the  $\alpha$ - or  $\beta$ -thalassemia trait which is the milder form; the homozygous state is known as  $\alpha$ -thalassemia or  $\beta$ -thalassemia major (Cooley's anemia) which presents with severe manifestations of the disease. The

condition was first described by Thomas Cooley and Pearl Lee Detroit in 1925.<sup>[2]</sup>

In  $\beta$  thalassemia major, the production of beta globin chains is severely impaired as mutation occurs in the sequence of beta globin gene which results in a severe or total suppression of beta chain synthesis. The patient has anemia and the red blood cells (RBCs) show microcytic and hypochromic appearance with an aberrant morphology. Beta-thalassemic patients undergo repeated blood transfusions. This hypertransfusion treatment results in iron overload which is life-limiting complication commonly found in thalassemia patients.<sup>[1]</sup> It is mainly because of ineffective erythropoiesis and increased absorption of iron in gastrointestinal tract, lack of physiologic mechanism for excreting excess iron, and above all multiple

Address for correspondence: Dr. Saurabh Juneja,  
Department of Oral Pathology, I.T.S. Dental College, Murad Nagar,  
Ghaziabad - 201 206, Uttar Pradesh, India.  
E-mail: drsaurabhjuneja@gmail.com

Access this article online	
Quick Response Code:	Website: www.ijabmr.org
	DOI: 10.4103/2229-516X.174005

This is an open access article distributed under the terms of the Creative Commons Attribution-NonCommercial-ShareAlike 3.0 License, which allows others to remix, tweak, and build upon the work non-commercially, as long as the author is credited and the new creations are licensed under the identical terms.

**For reprints contact:** reprints@medknow.com

**How to cite this article:** Rathore AS, Keshri N, Shetty DC, Juneja S. Oral exfoliative cytology as a screening tool for iron overload in  $\beta$ -thalassemia patients. Int J App Basic Med Res 2016;6:28-30.

blood transfusions.<sup>[3]</sup> Normal individuals require 1–2 mg/l of elemental iron physiologically, an amount readily available in the diet. A unit of packed RBCs contains 250–300 mg iron (1 mg/ml), so that a single transfusion of two units of packed RBCs is about equal to a 1–2 year intake of iron. There are no mechanisms for increasing the excretion of iron beyond normal daily losses. Iron thus rapidly accumulates in chronically transfused patients.<sup>[4]</sup>

The signs of a clinical toxicity become apparent, when the body iron concentration reaches 400–1000 mg/kg of the body weight. Iron overload occurring due to repeated blood transfusion leads to excessive parenchymal accumulation of this element, causing multiorgan failure and death subsequently.<sup>[5]</sup> The signs of iron overload can be usually seen after 10–12 transfusions. Body iron status can be evaluated by assessing serum ferritin level for the diagnosis of iron overload and monitoring the response to treatment. However, serum iron concentration is increased in some diseases even when the body iron stores are within normal limits, as in acute and chronic liver damage, malignancies, infections, and megaloblastic anemia. A liver and bone marrow biopsy is, therefore, required to accurately identify iron overload in parenchymal cells, but these procedures are invasive and, therefore, are not advisable in each case.

The present study was designed to assess the utility of Perl's Prussian blue in the exfoliated buccal epithelial cells assess the iron overload and its correlation with serum ferritin levels in beta-thalassemia patients undergoing repeated blood transfusions.<sup>[6]</sup>

## MATERIALS AND METHODS

The present study comprised 35  $\beta$ -thalassemia major patients in the age group of 5–28 years undergoing repeated blood transfusions and 10 systemically healthy patients in the control group. Ethical clearance was taken from the Institutional Review Board. Patients with iron deficiency anemia, megaloblastic anemia, hepatitis, malignancy, and chronic liver damage were excluded from the study. A detailed case history was recorded and the hematological findings were recorded. The study subjects were regularly taking oral iron-chelation therapy for more than 1 year. The buccal mucosa of the patients were scraped with a wet wooden spatula after rinsing their mouth with distilled water and smeared onto a glass slide. The smear was fixed immediately in 70% ethanol for 1 h and then stained with Perl's Prussian blue. One percentage aqueous neutral red was used as the counterstain. The stained smears were examined under the research microscope (Olympus B  $\times$ 41) to study the presence or absence of blue colored intracytoplasmic granules in the oral epithelial cells. The iron overload was assessed using serum ferritin levels of the patients at the time of taking the oral cytosmears.

## RESULTS

The study group included 21 males (60%) and 14 females (40%) and the mean age was  $16.07 \pm 6.57$  years. The positive cytological smears showed blue colored granules in the cytoplasm of exfoliated oral epithelial cells stained with Perl's Prussian blue stain [Figures 1 and 2]. Twenty-nine (82.9%) cases showed positive reaction for Perl's Prussian blue reaction while 6 (17.1%) cases did not show the presence of blue colored granules in the oral cytosmears. The presence of iron by Perl's Prussian blue staining reaction was correlated with serum ferritin level and a statistically significant difference (*t*-test,  $P < 0.05$ ) was observed for the presence of high iron overload and its detection through Perl's Prussian blue in exfoliative cytology [Table 1]. However, the results did not correlate statistically with gender of the patients thus indicating that the findings were not related to gender in the study group [Table 2]. The number of cases with exfoliative cytosmears showing reaction with Perl's Prussian blue correlated with the increasing levels of serum ferritin levels in these patients [Figure 3].

## DISCUSSION

Beta-thalassemia is characterized by increased serum iron levels due to combined effects of increased ferritin synthesis and the release of intracellular ferritin from damaged cells.<sup>[7]</sup> Iron stores in the body show variation depending mainly on the intensity of transfusion and the efficacy of chelation.<sup>[8]</sup> Iron overload can also be seen in various conditions such as hereditary hemochromatosis, thalassemia major, aplastic anemia, and myelodysplasia due to the lack of specific excretory pathways.

The parenchymal iron overload can be assessed by liver and bone marrow biopsies. Chemical quantification of iron in liver biopsy tissue has been considered the "gold-standard" for assessing body iron stores. Telfer *et al.* highlighted the limitations of a single biopsy in predicting long-term complications

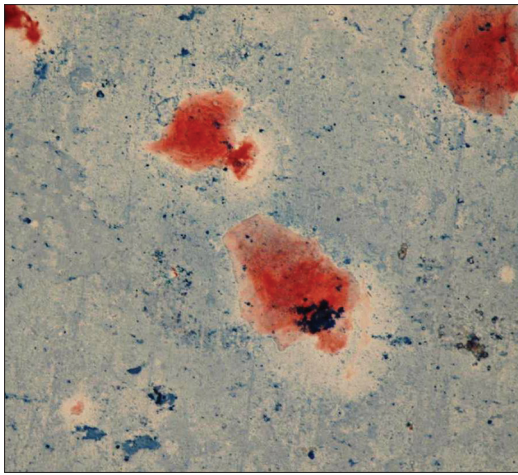
**Table 1: Correlation of the presence of iron in exfoliated oral epithelial cells with serum ferritin levels in patients with beta-thalassemia**

Prussian blue reaction	Number of cases	Mean serum ferritin levels	SD	P
Negative	6	1924.83	447.035	<0.05 (significant)
Positive	29	3714.86	1505.753	

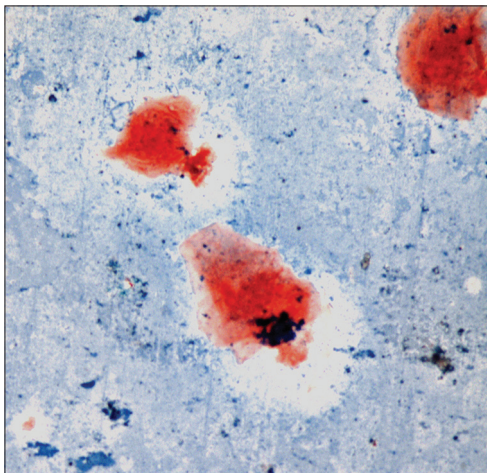
SD: Standard deviation

**Table 2: Correlation of Prussian blue reaction with gender in the study group**

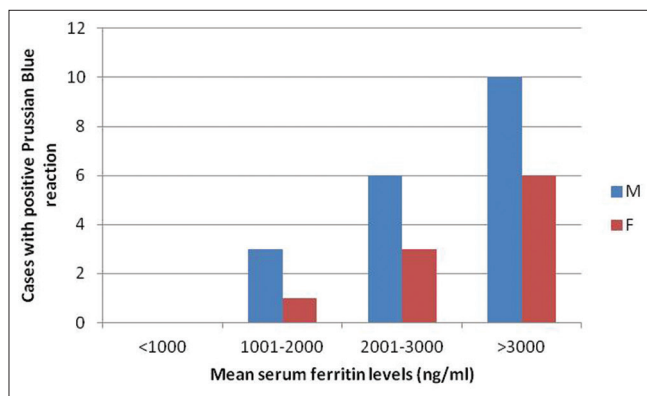
Gender	Prussian blue reaction (%)		P
	Negative	Positive	
Male	2/21 (9.5)	19/21 (90.5)	0.191 (nonsignificant)
Female	4/14 (28.6)	10/14 (71.4)	
Total	6/35 (17.1)	29/35 (82.9)	



**Figure 1:** Photomicrograph showing blue colored intracytoplasmic granules in the exfoliated oral epithelial cells (Perl's Prussian blue, ×40)



**Figure 2:** Photomicrograph showing positive staining for iron in the cytosmeared cells (Perl's Prussian blue, ×40)



**Figure 3:** Correlation of serum ferritin levels with positivity of oral cytosmeared cells with Perl's Prussian blue reaction

of transfusional iron overload. Long-term assessment and monitoring of iron overload in such patients is difficult.<sup>[8]</sup>

Oral exfoliative cytology is a simple and noninvasive procedure which can be used to study the cytological and nuclear features in

exfoliated oral epithelial cells. The cytosmeared cells were used to assess the iron overload by using Perl's Prussian blue staining reaction by histochemical demonstration of iron in the cytoplasm of the oral epithelial cells. Perl's Prussian blue reaction is based on the principle that acidified potassium ferrocyanide solution binds to iron in tissue, forming a relatively insoluble blue-purple precipitate.<sup>[9]</sup>

In the present study, 82.9% cases showed positivity for Perl's Prussian blue staining reaction in the cytological smears of exfoliated buccal cells. Our findings were similar to those observed by Nandaprasad et al.<sup>[4]</sup> who observed 65%, Bhat et al.<sup>[10]</sup> who found (71.7%), Gupta et al.<sup>[11]</sup> who found 61.6% positivity, and Gururaj and Sivapathasundaram<sup>[6]</sup> (2003) who observed 100% positivity. The presence or absence of these granules is not age or gender specific as previously shown by Nandaprasad et al. Based on the results of our study, it can be stated that Perl's Prussian blue reaction can be utilized as an objective indicator of iron overload in beta-thalassemic patients with high levels of iron overload.

#### Financial support and sponsorship

Nil.

#### Conflicts of interest

There are no conflicts of interest.

#### REFERENCES

- Greenberg M, Glick M. *Burket's Oral Medicine Diagnosis and Treatment. Hematologic Diseases*. 10<sup>th</sup> ed., Ch. 16. Philadelphia: Elsevier; 2006.
- Girinath P, Vahanwala S, Krishnamurthy V, Pagare S. Evaluation of orofacial manifestation in 50 thalassemia patients: A clinical study. *J Indian Acad Oral Med Radiol* 2010;22:126-32.
- Ikram N, Hassan K, Younas M, Amanat S. Ferritin levels in patients of Beta thalassemia major. *Int J Pathol* 2004;2:71-4.
- Nandaprasad S, Sharada P, Vidya M, Karkera B, Hemanth M, Prakash N. Oral exfoliative cytology in beta thalassemia patients undergoing repeated blood transfusions. *Internet J Pathol* 2008;10:7047.
- Cutando Soriano A, Gil Montoya JA, López-González Garrido Jde D. Thalassemias and their dental implications. *Med Oral* 2002;7:36-40.
- Gururaj N, Sivapathasundaram B. Demonstration of iron in the exfoliated cells of oral mucosa. *J Oral Maxillofac Pathol* 2003;7:37-9.
- Worwoon M, Cragg S, Jacobs A, McLaren C, Ricketts C, Economidou J. Binding of serum ferritin to concanavalin A: Patients with homozygous  $\beta$  thalassemia and transfusional iron overload. *Br J Haematol* 2008;46:409-16.
- Telfer PT, Prestcott E, Holden S, Walker M, Hoffbrand AV, Wonke B. Hepatic iron concentration combined with long-term monitoring of serum ferritin to predict complications of iron overload in thalassaemia major. *Br J Haematol* 2000;110:971-7.
- Wick MR. Histochemistry as a tool in morphological analysis: A historical review. *Ann Diagn Pathol* 2012;16:71-8.
- Bhat AA, Parwani RN, Wanjari SP. Demonstration of iron in exfoliated buccal cells of  $\beta$ -thalassemia major patients. *J Cytol* 2013;30:169-73.
- Gupta S, Trichal V, Malik R, Nigam R, Choudhary R, Shrivastava A. Perl's prussian blue positivity in exfoliated buccal cells of  $\beta$  thalassemia major patients and its correlation with serum ferritin. *J Evol Med Dent Sci* 2014;3:5135-40.