

## Permcath Catheter Embolization: a Case Report

Hadi Yousefshahi<sup>1</sup>; Payvand Bina<sup>2</sup>; Fardin Yousefshahi<sup>3,\*</sup>

<sup>1</sup>Department of Cardiology, Kermanshah University of Medical Sciences, Kermanshah, Iran

<sup>2</sup>Department of Research, Tehran Heart Center, Tehran University of Medical Sciences, Tehran, Iran

<sup>3</sup>Department of Anesthesiology, Tehran University of Medical Sciences, Tehran, Iran

\*Corresponding author: Fardin Yousefshahi, Department of Anesthesiology, Tehran University of Medical Sciences, P. O. Box: 1597856511, Tehran, Iran. Tel: +98-2188897761, Fax: +98-2188915959, E-mail: yousefshahi@tums.ac.ir

Received: February 2, 2014; Revised: May 24, 2014; Accepted: July 22, 2014

**Introduction:** Nowadays, many types of intravascular devices and catheters are used in order to diagnose and treat diseases. Complications related to these instruments are the costs that doctors and patients have to pay to benefit from their advantages. Catheter embolization is one of these side effects. Patients with devices in their cardiopulmonary system are at risk for severe complications such as arrhythmias, pulmonary embolism, myocardial injuries, hemoptysis, thrombosis and perforation.

**Case Presentation:** A 50-years-old woman, with a history of breast cancer, had a PermCath emplacement in right subclavian vein for a course of chemotherapy. The treatment for cancer seemed to be successful and the PermCath had remained in its position without complication, for a couple of years however, the catheter was founded broken and embolized to the right ventricle and the main left pulmonary artery, diagnosed by a chest X-ray study incidentally.

**Conclusions:** It is better to remove the unused devices safely to prevent and decrease their possible complications.

**Keywords:** Catheter; Embolization, Therapeutic; Medical Devices

### 1. Introduction

Nowadays in modern medicine, many practical measurements are not applicable without using devices or catheters (1, 2). In 1954, catheter emboli were reported for the first time (3). Reported embolized foreign bodies consist of catheters, ports, instruments, devices (1, 4-7), or even cotton or cellulose fibers (8). Embolization may occur during application, insertion, or even years after implantation (7, 9). It can be partial or complete (10). Catheter emboli incidence has been reported in articles from 0.1% to 25% (11, 12). Efficacious determinants affecting catheter emboli incidence are characteristic of the catheter, technique of insertion, and also, the site of embolization. Patients' general condition and management may influence the complications (11, 13, 14). By applying modern catheters, the incidence of this complication has decreased (11). Catheter embolization may remain undetected for a long time and often diagnosed incidentally (7, 12, 15). Catheter malfunction may be the first sign of this complication (7, 12). Many embolized foreign bodies were completely asymptomatic and founded only during autopsies (1, 8).

Venous catheters or its fragments may be embolized to the various sites (7). The rate of serious complications associated with foreign body embolism is about 71% (1). Mortality rate varies from 1.8% to 60% (1, 7, 13, 14); however, all of these deaths have not been confirmed to be directly a consequence of catheter embolism (11). Particularly, pa-

tients who have devices in their cardiopulmonary system are at risk of severe complications such as arrhythmia, pulmonary embolism, myocardial injury, hemoptysis, thrombosis, or perforation (1, 6, 7, 14). In more than 52% of catheters, which are in their normal position for more than 48 hours, bacterial contamination has been reported (1, 6, 14). Based on our knowledge, there was not any report about a lost and remained Permcath for a longtime period. Regarding these data, we decided to present this patient with a remained catheter in her body for about three years.

### 2. Case Presentation

A 50-year-old woman, with a history of breast cancer and a course of radiotherapy and chemotherapy, had a Permcath emplacement in right subclavian vein in august 2008 for her chemotherapy. Permcath is a flexible double lumen cuffed plastic tube that can be put into a vein just below the neck. The tube can then be used for long term purposes. The patient was otherwise in a good health condition and did not have any other positive medical or drug history. The treatment for cancer seemed to be successful and her oncologist performed routine follow-up measurements. The Permcath had remained in its position without any complication for three years followed up by routine chest X-ray study (Figures 1 and 2). However, the Permcath was found broken totally from its base and embolized to right ventricle and the left main

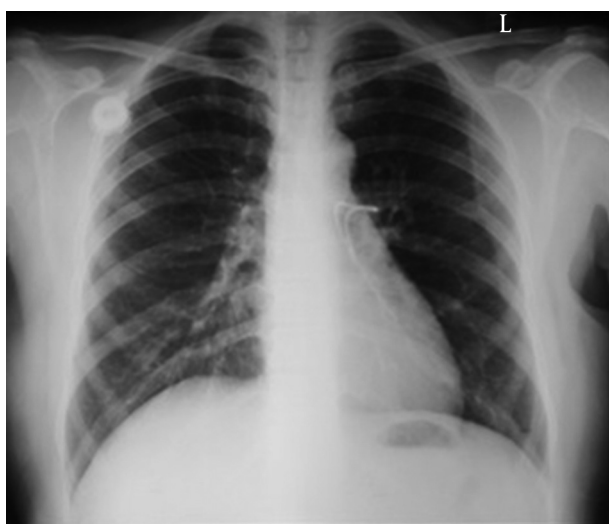
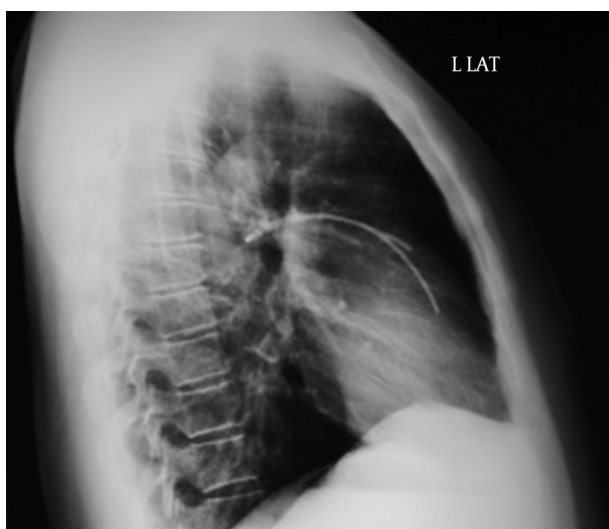

Figure 1. CXR Posteroanterior View

Figure 2. CXR Lateral View



Broken part is seen in this catheter is clear.

pulmonary artery (Figures 1 and 2) after three years of insertion.

The chest X-ray (dated a year before our evaluation) revealed that the Permcath was intact and in its normal position. Furthermore, there was no history of physical or traumatic injury or accident in the precise history review for the last three years. The patient did not report any use of her Permcath during the last investigation and did not remember any obvious complaint regarding embolization, migration, or lodging the catheter. There was not any positive chief complaint at the time of detection and physical examinations. Furthermore, electrocardiography and echocardiography investigations were normal or unchanged comparing with the previous ones.

We hypothesized that sticking the catheter between

her clavicle and first rib was the probable cause of its breaking (pinch-off syndrome). In consultation with colleagues and experts, and following discussion of probable symptoms and potential complications, considering the lack of any sign or symptom and the risk of open surgery to removal of the embolized catheter, we decided to leave it in its position, and the patient was advised to perform regular consecutive follow-up studies. There was no change in the patient condition and the catheter position during a one-year follow up.

### 3. Discussion

The main concerns with dislocated embolization coils are local thrombogenicity and distal ischemia (1, 6). Vascular wall may be perforated by guide-wires, stents and filters. There are reports of sudden death cases at the time of embolization (11). The worst prognosis has been reported in the patients with right heart catheter embolism with a mortality rate of 53% in the non-operated group. Intravascular embolization of port catheters can be asymptomatic at the time of diagnosis (7) or induce serious cardiovascular, pulmonary and septic complications with an overall mortality rate of 1.8% (7, 13). By a large margin, retracting the catheter through the needle was the most common mechanism of catheter embolization for many years (1, 11). Entrapment of the catheter between clavicle and first rib ("pinch-off") is another cause of embolization (7, 12, 15). To prevent pinch-off syndrome, port catheter should be implanted more laterally in the subclavian vein, or in some cases, jugular vein should be applied (12). Such preventive measurement may be impossible or too difficult in patients with history of chemotherapy and radiotherapy. Needle shearing force should be avoided by protecting the tubing, especially in flexion areas (16).

Guidelines suggest that unused ports should be removed (17). Regarding the potential dangers of retained intravascular objects, it is advised that intravascular devices should be precisely localized and taken away as soon as possible, if a piece of the device is lost in the cardiovascular system before it reaches heart (1, 4, 6, 12, 15). If a polyethylene catheter or a silicone rubber stays in cardiovascular system for about 6 - 8 weeks, their removal is complicated because of fibrous endothelial reaction around the catheter (14, 18).

Permcath is made of soft, silicone materials. These objects also may potentially act as a core for thrombosis; therefore, letting them to remain in a pathologic position is inadvisable (12, 18). Thoracotomy and its accompanied problems have made surgical device removal as a displeasing choice (14, 18). Besides, in the cases of longtime foreign bodies in vascular system, surgical techniques are too hard to be applied (7, 18). Based on long-term follow-up, there is no difference between patients in whom stents were removed percutaneously and those whose stents were removed to a secured replaced position (1). Furthermore, it is better to evaluate the risks associated

with the retrieval maneuver, such as permanent vascular wall trauma, against the advantage to the patient from the percutaneous procedure, before doing any invasive therapeutic measurement (1, 6).

Considering all potential problems and disadvantages, we strongly recommend that with regarding the guidelines, all foreign bodies and devices -which were applied intravenously- should be removed safely to prevent possible complications and decrease morbidity and mortality, if they are not supposed to be utilized anymore.

## Acknowledgements

The authors are indebted to the patient who is reported in this manuscript.

## Authors' contributions

Hadi Yousefshahi found and suggested the patient as a case report and collected the patient's data, Fardin Yousefshahi reviewed the literature and suggested the manuscript format, Payvand Bina wrote the manuscript and performed references list.

## References

- Bernhardt LC, Wegner GP, Mendenhall JT. Intravenous catheter embolization to the pulmonary artery. *Chest*. 1970;**57**(4):329-32.
- Ingram P, Sinclair L, Edwards T. The safe removal of central venous catheters. *Nurs Stand*. 2006;**20**(49):42-6.
- Turner DD, Sommers SC. Accidental passage of a polyethylene catheter from cubital vein to right atrium; report of a fatal case. *N Engl J Med*. 1954;**251**(18):744-5.
- Gabelmann A, Kramer S, Gorich J. Percutaneous retrieval of lost or misplaced intravascular objects. *AJR Am J Roentgenol*. 2001;**176**(6):1509-13.
- Grabenwoeger F, Bardach G, Dock W, Pinterits F. Percutaneous extraction of centrally embolized foreign bodies: a report of 16 cases. *Br J Radiol*. 1988;**61**(731):1014-8.
- Savage C, Ozkan OS, Walser EM, Wang D, Zwischenberger JB. Percutaneous retrieval of chronic intravascular foreign bodies. *Cardiovasc Intervent Radiol*. 2003;**26**(5):440-2.
- Surov A, Wienke A, Carter JM, Stoevesandt D, Behrmann C, Spielmann RP, et al. Intravascular embolization of venous catheter-causes, clinical signs, and management: a systematic review. *JPEN J Parenter Enteral Nutr*. 2009;**33**(6):677-85.
- Dimmick JE, Bove KE, McAdams AJ, Benzing G. Fiber embolization—a hazard of cardiac surgery and catheterization. *N Engl J Med*. 1975;**292**(13):685-7.
- Mashman WE, King SB, Jacobs WC, Ballard WL. Two cases of late embolization of Amplatzer septal occluder devices to the pulmonary artery following closure of secundum atrial septal defects. *Catheter Cardiovasc Interv*. 2005;**65**(4):588-92.
- Linz DN, Bisset G3, Warner BW. Fracture and embolization of a peripherally inserted central venous catheter. *JPEN J Parenter Enteral Nutr*. 1994;**18**(1):79-80.
- Propp DA, Cline D, Hennenfent BR. Catheter embolism. *J Emerg Med*. 1988;**6**(1):17-21.
- Surov A, Jordan K, Buerke M, Persing M, Wollschlaeger B, Behrmann C. Atypical pulmonary embolism of port catheter fragments in oncology patients. *Support Care Cancer*. 2006;**14**(5):479-83.
- Bhatt VR, Gupta S, Lowry J, Dhar M. Port-a-cath embolisation to pulmonary artery. *BMJ Case Rep*. 2011;**2011**.
- Rettig G, Doenecke P, Sen S, Volkmer I, Bette L. Complications with retained transvenous pacemaker electrodes. *Am Heart J*. 1979;**98**(5):587-94.
- Loch A, Singh RV, Abidin IZ, Han CK, Ahmad WA. Late intravascular embolization of a chemo port catheter. *J Thorac Oncol*. 2011;**6**(7):1292.
- Doering RB, Stemmer EA, Connolly JE. Complications of indwelling venous catheters, with particular reference to catheter embolus. *Am J Surg*. 1967;**114**(2):259-66.
- Bishop L, Dougherty L, Bodenham A, Mansi J, Crowe P, Kibbler C, et al. Guidelines on the insertion and management of central venous access devices in adults. *Int J Lab Hematol*. 2007;**29**(4):261-78.
- Foley PT, Carter RM, Uberoi R. Endovascular removal of long-term hemodialysis catheters. *Cardiovasc Intervent Radiol*. 2007;**30**(5):1079-81.