

Use of Valtrac™-Secured Intracolonic Bypass in Laparoscopic Rectal Cancer Resection

Feng Ye, PhD, Dong Chen, MD, Danyang Wang, MD, Jianjiang Lin, MD, and Shusen Zheng, PhD

Abstract: The occurrence of anastomotic leakage (AL) remains a major concern in the early postoperative stage. Because of the relatively high morbidity and mortality of AL in patients with laparoscopic low rectal cancer who receive an anterior resection, a fecal diverting method is usually introduced. The Valtrac™-secured intracolonic bypass (VIB) was used in open rectal resection, and played a role of protecting the anastomotic site. This study was designed to assess the efficacy and safety of the VIB in protecting laparoscopic low rectal anastomosis and to compare the efficacy and complications of VIB with those of loop ileostomy (LI).

Medical records of the 43 patients with rectal cancer who underwent elective laparoscopic low anterior resection and received VIB procedure or LI between May 2011 and May 2013 were retrospectively analyzed, including the patients' demographics, clinical features, and operative data.

Twenty-four patients received a VIB and 19 patients a LI procedure. Most of the demographics and clinical features of the groups, including Dukes stages, were similar. However, the median distance of the tumor edge from the anus verge in the VIB group was significantly longer (7.5 cm; inter-quartile range [IQR] 7.0–9.5 cm) than that of the LI group (6.0 cm; IQR 6.0–7.0 cm). None of the patients developed clinical AL. The comparisons between the LI and the VIB groups were adjusted for the significant differences in the tumor level of the groups. After adjustment, the LI group experienced longer overall postoperative hospital stay (14.0 days, IQR: 12.0, 16.0 days; $P < 0.001$) and incurred higher costs (\$6300 [IQR: \$5900, \$6600]) than the VIB group (7.0 days, \$4800; $P < 0.05$). Stoma-related complications in the ileostomy group included dermatitis ($n = 2$), stoma bleeding ($n = 1$), and wound infection after closure ($n = 2$). No BAR-related complications occurred. The mean time to Valtrac™ ring loosening was 14.1 ± 3.2 days.

The VIB procedure, as a good partner with the laparoscopic rectal cancer resection, appears to be a safe and effective, but time-limited, diverting technique to protect an elective low colorectal anastomosis.

(*Medicine* 93(29):e224)

Abbreviations: AL = anastomotic leakage, ASA = American Society of Anesthesiologists, BAR = biofragmentable anastomosis ring, BMI = body mass index, IRB = Institutional Review Board,

Editor: Ankush Gosain.

Received: May 29, 2014; revised: September 17, 2014; accepted: September 22, 2014.

From the Department of Colorectal Surgery (FY, DC, DW, JL); and Department of General Surgery, the First Affiliated Hospital, Zhejiang University, No. 79, Qinchun Road, Hangzhou, China (SZ).

Correspondence: Shusen Zheng, Department of General Surgery, the First Affiliated Hospital, Zhejiang University, No. 79, Qinchun Road, Hangzhou 310003, China (e-mail: shusen00001@sina.com).

The authors have no funding or conflicts of interest to disclose.

Copyright © 2014 Wolters Kluwer Health, Inc. All rights reserved.

This is an open access article distributed under the Creative Commons Attribution-NonCommercial-NoDerivatives License 4.0, where it is permissible to download, share and reproduce the work in any medium, provided it is properly cited. The work cannot be changed in any way or used commercially.

ISSN: 0025-7974

DOI: 10.1097/MD.0000000000000224

LI = loop ileostomy, TME = total mesorectal excision, VIB = Valtrac™-secured intracolonic bypass.

INTRODUCTION

At present time, laparoscopic resection of rectal cancer has been performed by skilled laparoscopic surgeons and resulted in acceptable oncologic and functional outcomes.^{1–4} The occurrence of anastomotic leakage (AL) still is a major concern in the early postoperative stage. Among patients undergoing laparoscopic rectal resection, the rate of postoperative AL has been reported to be approximately 6% to 17%,^{5–9} which is similar to open surgery.^{10–13} However, performing laparoscopic rectal cancer excision and an intracorporeal anastomosis has some technical drawbacks, such as the lack of direct tactile sense, inadequate traction, and an ineffective cutting angle of the endo-linear surgical stapler.¹⁴ Therefore, laparoscopy is considered an additional risk factor for leakage in rectal surgery.¹⁵

AL often results in prolonged hospital stays, reoperation, and increased morbidity and mortality.^{16,17} Several operative techniques and methods, such as a diverting ileostomy,^{18,19} tube cecostomy,²⁰ omentoplasty,²¹ and intracolonic bypass,^{22–24} have been used in attempts to reduce the incidence of AL and/or morbidity. Among them, the proximal diverting stomy had reduced leak in patients with anastomotic complications.^{18,19} However, its use results in stoma-related complications and the secondary operation to close the stoma leads to increased patient suffering and cost.²⁵ Besides, ileostomy is usually created at the right lower quadrant because of its vicinity to the ileocecal valve. During the laparoscopic rectal procedure, another wound is required for the stoma procedure, resulting in a scar after take-down.²⁶

We have evaluated the Valtrac™-secured intracolonic bypass (VIB) in open rectal resection; and the effective and safe results were found in protecting the anastomotic site by our and others' studies.^{24,27} A VIB consists of a Valtrac™ ring, that is, biofragmentable anastomosis ring (BAR; United States Surgical, Princeton, NJ) and a condom connected to the BAR. The VIB is positioned in the colon 5 to 7 cm proximal to the anastomotic site. Because its use in laparoscopic rectal resection is not clear, we have introduced a VIB into laparoscopic rectal cancer resection to protect the distal anastomotic site. This study was designed to assess the efficacy and safety of the VIB-laparoscopy procedures in protecting the low rectal anastomosis and to compare the efficacy and complications of the VIB with those of a loop ileostomy (LI).

METHODS

Patients

Institutional Review Board approval was obtained from First Affiliated Hospital, Zhejiang University. All patients were informed about the laparoscopy and LI procedures, and written

consent was obtained from the patient 1 day prior to surgery. Inclusion criteria for the laparoscopy surgery included a localized tumor >5 cm but ≤12 cm from the anal verge, compliance with laparoscopy procedures, and sufficient heart and lung function to withstand laparoscopic surgery. Exclusion criteria for minimally invasive approach were cancers infiltrating contiguous organs (T4) and counter-indications to the pneumoperitoneum. If the long axis of tumor size not larger than 6 cm, it will also be excluded. Preoperative study was based on locoregional staging by transanal ultrasonography or MRI and by contrast enhanced CT scan of the thorax, abdomen and pelvis. Patients with locally advanced rectal carcinomas (T3N0 and all N+ patients) were preoperatively treated by neoadjuvant chemoradiation: 25 fractions of 45 Gy in 5 weeks with oral capecitabine 825 mg/m² twice daily. All patients treated with preoperative chemoradiation were operated within 6 to 8 weeks after completing their neoadjuvant treatment. Appropriate demographic information pertaining to sex, age, BMI, comorbidities, level of tumor, and neoadjuvant therapies was obtained. Outcomes, measured by operating time, length of hospital stay, cost, return of bowel function and complication rates were assessed. Wounds were monitored during daily rounds and follow-up visits for signs of infection.

We retrospectively reviewed the medical records of 43 consecutive rectal cancer patients who had undergone elective laparoscopic low anterior resection with VIB or LI procedure to protect the lower anastomosis in the Department of Colorectal Surgery, the First Affiliated Hospital, Zhejiang University from May 2011 to May 2013.

Surgery

Surgical Technique for Laparoscopic Low Anterior Resection

The patient was placed in a modified lithotomy, right side down, Trendelenburg position. An initial 10-mm port placement was carried out using the open technique, and pneumoperitoneum was accomplished using carbon dioxide. The gas line was connected and the telescope introduced. Then two 5-mm ports were inserted in the upper right and left abdominal quadrants and two more 12-mm ports were placed in the lower right and left abdominal quadrants under laparoscopic guidance.

The procedure permitted the performance of the laparoscopic no-touch isolation technique, the so-called “medial-to-lateral” approach and total mesorectal excision (TME) principles. After mobilization of the left colon, if necessary, mobilization of the splenic flexure was performed; intracorporeal ligation of the inferior mesenteric vessels was performed followed by mobilization of the rectum and the mesorectum. After the completion of full mobilization by cutting the peritoneum from the lateral side, intracorporeal transection of the distal bowel was performed with an Endo GIA stapler (Ethicon Endo-Surgery; Johnson & Johnson, New Brunswick, NJ). The bowel was extracted through a small incision made under a wound protector in the left lower quadrant port and was divided with appropriate proximal bowel. Then, a VIB procedure was performed.

VIB Technique

The VIB technique utilized 6 basic steps, depicted in Figure 1. The BAR consisted of polyglycolic acid (87.5%) and barium sulfate (12.5%) and was biodegradable and radiologically detectable (Sigma–Aldrich, St. Louis, MO, USA). The size of the BAR was selected to accommodate the intestinal diameter and wall thickness: the 25/2.0 and 28/2.0 sizes were

commonly applied in the VIB procedure. A condom Durex (Qingdao London Durex Co., Ltd, Qingdao, Shandong Province, China) was ligated to the BAR (Figure 1A). As shown in Figure 1B, the BAR with attached condom was inserted into the proximal colonic stump more than 5 cm from the colonic verge. The BAR-condom component was sutured in place with a monofilament absorbable thread (3-0 VicrylTM; Johnson & Johnson) that was tightened around the colonic wall at the site of the BAR gap (Figure 1C). After colonic appendices and 1 or 2 straight arteries were cut in the site, the BAR was closed until a click was heard. Supporting stitches were placed in the presence of serosal splits (Figure 1C). Purse string sutures were applied at the proximal stumps using a monofilament absorbable thread with straight needles (3-0 MaxonTM, United States Surgical). A pocket was made near the proximal end of the sigmoid colon and the anvil of an end-to-end anastomotic stapler (Ethicon Endo-Surgery; Johnson & Johnson) was inserted and fixed (Figure 1D). The stapler was inserted through the anus into the pelvic cavity. After stapling, both the anastomotic site and stapler were carefully evaluated and any anastomotic tears were treated by suturing. Figure 1E showed the passing of the whole near end of the sigmoid colon through the auxiliary incision port (left lower abdomen) into the abdominal cavity where the colorectal anastomosis was performed using laparoscopy. As shown in Figure 1F, the distal end of the condom was pulled down through the rectal anastomosis and guided outside the anus. The problems associated with the BAR were the induction of serosal splits in the colonic lumen necessitating replacement with a smaller diameter BAR.

LI Technique

The technical aspects of LI are well known. The stomas are placed on the lower right side of the abdomen, and closed 3 to 6 months later. The problems associated with the stoma usually were caused by drawing the ileum from the stoma and resulted in extensive serosal splits.

Assessment of Bowel Function

Return of bowel function was defined as the first passage of flatus or bowel movement with tolerance of an oral diet. Ileus was defined as delayed return of bowel function; its symptoms included abdominal distention, intolerance of an oral diet, nausea, or radiographic evidence of dilated bowel but no obvious obstruction. Bowel obstruction was defined as the similar symptoms and radiographic evidence of dilated bowel with clear obstruction.

Assessment of Anastomosis, Anastomotic Leakage and Dehiscence

The loosening of a BAR was confirmed by digital rectal palpation.

Routine examination of the anastomosis was performed approximately 9 days postoperatively by digital rectal examination, colonoscopy, and/or colonography (Figure 2). If no AL was detected, ileostomy reversal was performed. Digital palpation was performed routinely and proctoscopy if indicated. All patients were followed up for a minimum of 6 months. Thirty-five patients (20 of the VIB group and 15 of the LI group) received a colonoscopic examination during the follow-up period.

Symptoms of AL were evaluated by digital examination and proctoscopy. Anastomotic dehiscence was confirmed by digital rectal palpation and proctoscopic examination if indicated. Clinical AL was determined by peritonitis caused by leakage,

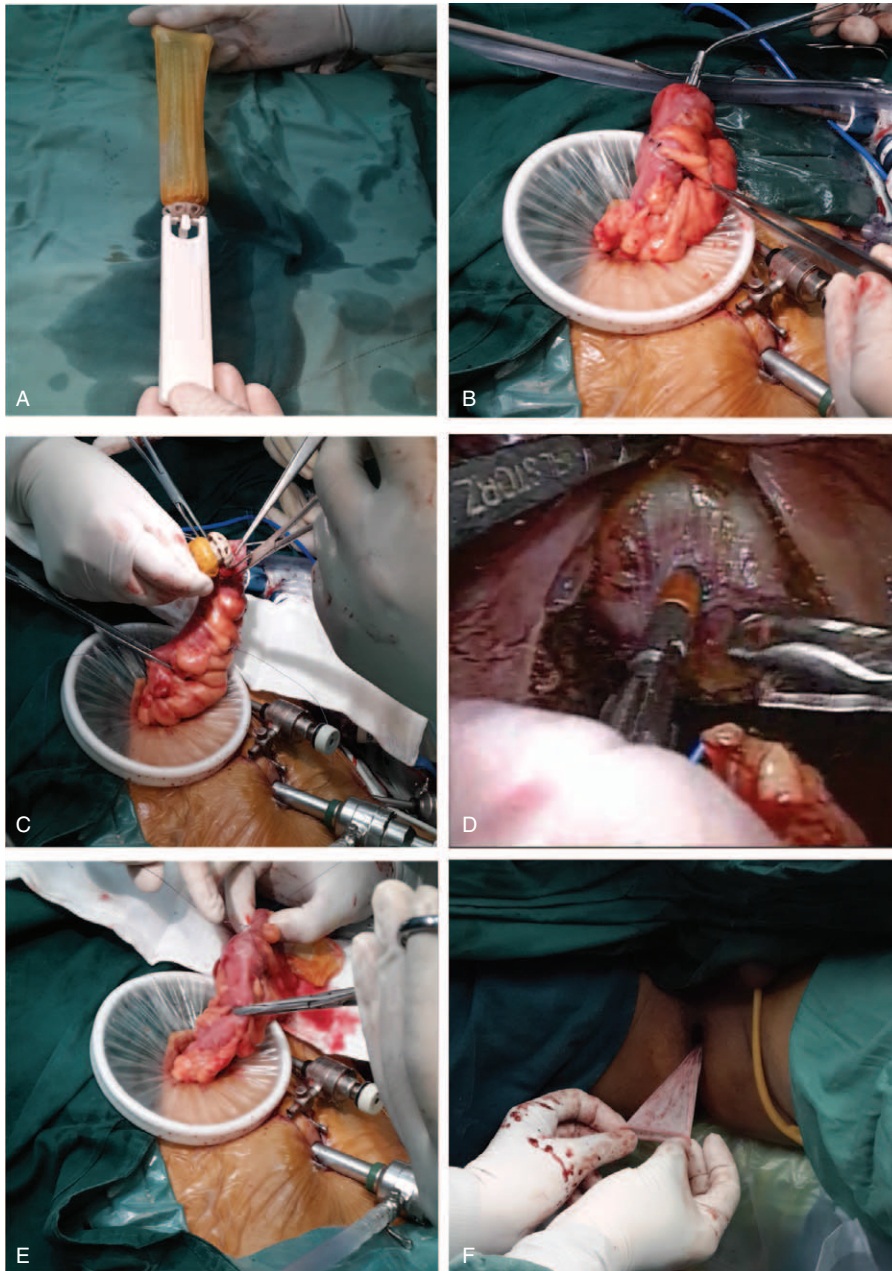


FIGURE 1. A depiction of the VIB procedure. (A) The joining of the Valtrac™ ring—biofragmentable anastomosis ring (BAR)—and the condom. (B) Insertion of the Valtrac™ ring into the sigmoid colon portion. (C) The Valtrac™ ring was fixed at approximately 5 cm apart of transection end and fixed with a monofilament absorbable thread (3-0 Vicryl™; Johnson & Johnson) tightened around the colonic wall at the site of the BAR gap. After colonic appendices and 1 or 2 straight arteries were cut in the site, the BAR was closed until a click was heard. Supporting stitches were placed in the presence of serosal splits. (D) A pocket was made near the proximal end of sigmoid colon and a mushroom head-like stapler was inserted. (E) The whole near end of sigmoid colon was passed through the auxiliary incision port in the left lower abdomen into the abdominal cavity. The colorectal anastomosis was performed at this site. (F) The distal end of the condom was pulled through the rectal anastomosis and guided outside the anus.

pelvic abscess, abdominal drain discharge of feces, pus, or gas, discharge of pus from the rectum, or rectovaginal fistula.

Statistical Analyses

Due to the small sample size of both treatment groups, the continuous data and ordinal data were presented by median with

inter-quartile range (range between the 25th and 75th percentiles). Comparisons between groups with non-parametric data used the Mann–Whitney *U* test. The categorical data were presented as number and percentage of group, and the Fisher’s exact test was performed for their comparisons between groups. The ANCOVA (analysis of covariance) models were performed to compare VIB with LI group with adjustment for tumor level.

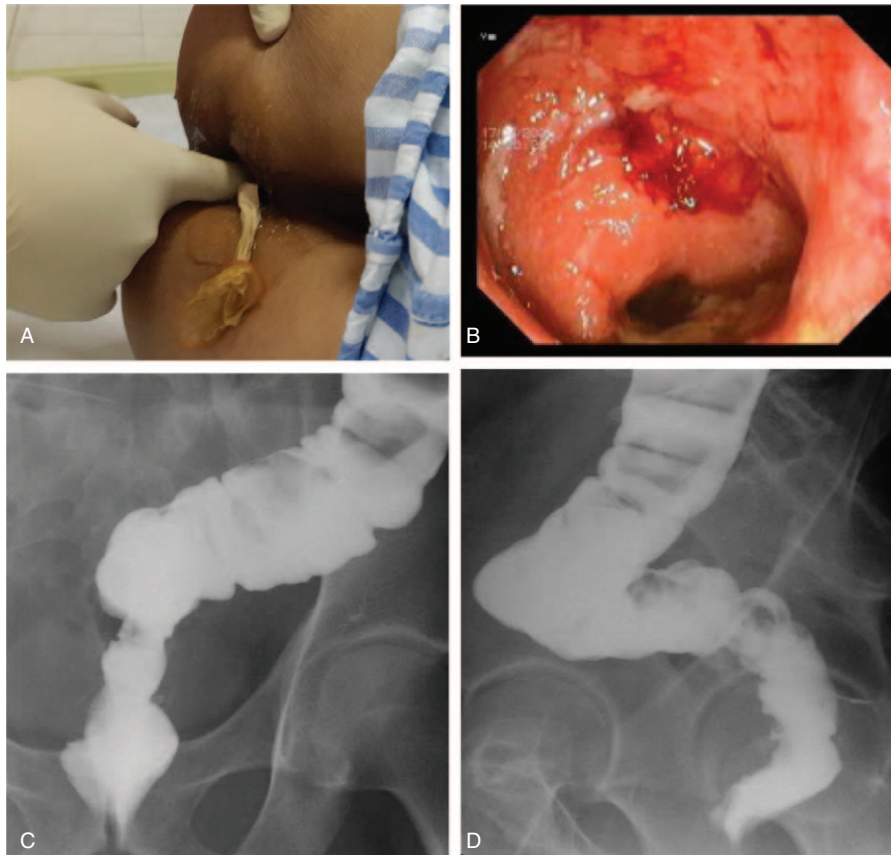


FIGURE 2. Methods for assessing BAR loosening and anastomotic leakage. (A) Rectal examination was used to assess BAR loosening and leakage. (B) Colonoscopy (anteroposterior view). (C) Colonography (x-ray film image, anteroposterior view). (D) Colonography (x-ray film image, lateral view).

A 2 tailed $P < 0.05$ was considered statistically significant. All statistic analyses were accessed by the SPSS statistical software package (Version 15.0, SPSS, Inc., Chicago, IL).

RESULTS

Between May 2011 and May 2013, we performed the VIB technique in 24 cases of laparoscopic low anterior resection and LI technique in 19 cases. The demographic data and pre-operative symptoms of the patients were similar between the 2 groups for most variables, including gender, median age, median body mass index (BMI), and various co-morbidities (Table 1). The median ASA scores between the groups were not significantly different (Table 1). Similar numbers of patients in the 2 groups had been treated with neoadjuvant radiochemotherapy (Table 1). However, patients of VIB group had significantly longer median distance to the lower edge of the tumor above the anal verge than those of LI group (median tumor level: 7.5 cm vs 6.0 cm, $P = 0.029$) (Table 1).

The operative data of the patients are shown in Table 2. The groups showed no significant differences in level of anastomosis, number of linear stapler firings, operation time, and distribution of Dukes stages (Table 2, $P > 0.05$). The following intraoperative and postoperative adverse events were also not significantly different between the 2 groups: Staple-line bleeding, wound infection, and stapled anastomotic stenosis. Anastomotic dehiscence occurred in 2 cases in VIB group and

no case in LI group, but there was no clinical manifestation of leakage. Because of readmission for stoma closure for 1 patient in the LI group, the overall post-operative hospital stay of the LI group was significantly greater than that of the VIB group (medians of 14.0 vs 7.0 days for post-operative stay, respectively, $P < 0.001$); Likewise, the median cost of the LI group was significantly greater than that of the VIB group (median \$6300 vs \$4800, $P < 0.001$). Complications associated with the stoma in the LI group included dermatitis ($n = 2$), stoma bleeding ($n = 1$), and wound infection after closure ($n = 2$). No BAR-related complications occurred. The mean time to BAR loosening was 14.5 ± 3.5 days (data not shown). The mean follow-up time was 1 year. Thirty-five patients (VIB, $n = 20$ and LI, $n = 15$) received a colonoscopic examination.

Since the median distance between the anus and tumor level was significantly longer in the VIB group, the ANCOVA models adjusted for the tumor level during the comparison of outcomes of the VIB with LI groups (Table 3). Patients of the VIB group had significantly shorter length of post-operative stay and lower cost than those of LI group, with the estimated difference of 7.34 days of post-operative stay ($P < 0.001$) and \$1330 cost ($P < 0.001$). However, patients of VIB group took significantly longer time to first flatus (12.67 h, $P < 0.001$), which may reflect that the VIB group had a significantly longer median time before first oral intake (7.31 h, $P < 0.001$) than the LI group. Furthermore, the sustenance of the LI patients did not need to proceed through the colorectal portion before the first flatus is recorded.

TABLE 1. General Characteristics of the Patients

	Total (n = 43)	VIB (n = 24)	LI (n = 19)	P-Value
Age (year) ^b	68.0 (61.0, 75.0)	70.5 (64.0, 75.5)	65.0 (58.0, 72.0)	0.255
Gender ^c				
Female	21 (48.8%)	11 (45.8%)	10 (52.6%)	0.763
Male	22 (51.2%)	13 (54.2%)	9 (47.4%)	
ASA score ^b	3.0 (2.0, 3.0)	2.0 (2.0, 3.0)	3.0 (3.0, 3.0)	0.094
BMI (kg/m ²) ^b	22.0 (20.0, 26.0)	21.5 (20.0, 25.5)	22.0 (20.0, 27.0)	0.961
Diabetes ^c	3 (7.0%)	2 (8.3%)	1 (5.3%)	>0.99
Hypertension ^c	3 (7.0%)	1 (4.2%)	2 (10.5%)	0.575
Uremia ^c	1 (2.3%)	1 (4.2%)	0 (0.0%)	>0.99
Level of tumor (cm) ^{a,b}	7.0 (6.0, 9.0)	7.5 (7.0, 9.5)	6.0 (6.0, 7.0)	0.029
Neoadjuvant radio-chemotherapy ^c	9 (20.9%)	5 (20.8%)	4 (21.1%)	>0.99

ASA = American Society of Anesthesiologists, BMI = body mass index, VIB = Valtrac™-secured intracolonic bypass, LI = loop ileostomy.

^a P < 0.05 indicates a significant difference between 2 groups.

^b Data are presented as median (inter-quartile range) and tested by Mann–Whitney U test.

^c Data are presented as number of patients (percentage) and tested by Fisher’s exact test.

DISCUSSION

AL after rectal cancer resection remains one of the most serious early postoperative complications both in open and laparoscopic surgery.^{5–12} AL has a negative prognostic impact on local recurrence and an association between AL and reduced long-term survival has been reported.^{16,17} Previous studies of laparoscopic and open surgery for rectal cancer have reported no statistical differences in terms of the AL rate.^{10–13} The most important risk factor for AL is the distance of the anastomosis from the anal verge. The high-risk level for AL is reported to be 5 to 7 cm from the anal verge.^{5,7} Other factors that increase the risk for AL are preoperative abdominal and pelvic radiotherapy,

corticosteroid treatment, smoking, obesity, hypertension, male gender, age, and medical conditions, including diabetes, cardiovascular disease, weight loss, hypoproteinemia, anemia, and metabolic disorders.^{5–9} Laparoscopy is considered an additional risk factor for leakage in rectal surgery, because laparoscopic rectal transection utilizes at least 2 linear staplers (in this series, mean number of linear stapler firings was 2.5 ± 1.5), with a cutter, and can lead to an excessively long stapling line with an inadequate cutting angle, which may result in AL.^{14,15}

The relatively high incidence of leakage in the high-risk group indicates the importance of protecting the anastomosis; thus, surgeons are constantly designing diverting methods.

TABLE 2. Operative Data of the Patients

	Total (n = 43)	VIB (n = 24)	LI (n = 19)	P-Value ^a
Level of anastomosis (cm) ^b	4.0 (4.0, 5.0)	4.0 (4.0, 5.0)	4.0 (3.0, 5.0)	0.214
Operative time (min) ^b	150.0 (125.0, 180.0)	147.5 (125.0, 172.5)	150.0 (120.0, 180.0)	0.825
Number of linear stapler firings ^b	2.0 (2.0, 3.0)	2.0 (2.0, 3.0)	2.0 (2.0, 2.0)	0.170
Intraoperative adverse events				
Staple-line bleeding ^c	3 (7.0%)	2 (8.3%)	1 (5.3%)	>0.99
Postoperative adverse event ^c				
Anastomotic dehiscence	2 (4.7%)	2 (8.3%)	0 (0.0%)	0.495
Wound infection	2 (4.7%)	1 (4.2%)	1 (5.3%)	>0.99
Stapled anastomotic stenosis	3 (7.0%)	1 (4.2%)	2 (10.5%)	0.575
Length of post-operative stay (days) ^{a,b,d}	9.0 (7.0, 14.0)	7.0 (6.0, 8.0)	14.0 (12.0, 16.0)	<0.001
Cost (\$1000 U.S. dollars) ^{a,b,d}	5.8 (4.7, 6.4)	4.8 (4.5, 5.6)	6.3 (5.9, 6.6)	<0.001
Dukes stages ^c				
A	7 (16.3%)	4 (16.7%)	3 (15.8%)	0.908
B	25 (58.1%)	13 (54.2%)	12 (63.2%)	
C	11 (25.6%)	7 (29.2%)	4 (21.1%)	
Number of harvested lymph nodes ^b	15.0 (13.0, 17.0)	15.0 (13.5, 16.5)	16.0 (13.0, 18.0)	0.491
Time to first flatus postoperatively (h) ^{a,b}	73.0 (66.0, 80.0)	79.0 (74.0, 88.0)	66.0 (59.0, 69.0)	<0.001
Time to oral intake (h) ^{a,b}	81.0 (78.0, 90.0)	85.5 (80.5, 94.5)	79.0 (76.0, 83.0)	0.002

BAR = biofragmentable anastomosis ring, VIB = Valtrac™-secured intracolonic bypass, LI = loop ileostomy.

^a P < 0.05 indicates a significant difference between the 2 groups.

^b Data are presented as median (inter-quartile range) and tested by Mann–Whitney U test.

^c Data are presented as number of patients (percentage) and tested by Fisher’s exact test.

^d The LI group includes that of the readmission for stoma closure.

TABLE 3. Summary of the Comparisons Between VIB and LI With Adjustment for Tumor Level (cm)

	β (95% CI)	P-Value
Length of post-operative stay (days)		
Intercept	14.26 (11.48, 17.04)	<0.001
Level of tumor (cm)	0.06 (−0.31, 0.43)	0.738
Surgery ^a		
VIB	−7.34 (−8.85, −5.83)	<0.001
LI	Reference group	
Cost (\$1000 U.S. dollars)		
Intercept	6.47 (5.44, 7.50)	<0.001
Level of tumor (cm)	−0.01 (−0.15, 0.13)	0.880
Surgery ^a		
VIB	−1.33 (−1.89, −0.77)	<0.001
LI	Reference group	
Time to first flatus (h)		
Intercept	57.19 (47.18, 67.19)	<0.001
Level of tumor (cm)	1.21 (−0.13, 2.55)	0.075
Surgery ^a		
VIB	12.67 (7.24, 18.10)	<0.001
LI	Reference group	
Time to oral intake (h)		
Intercept	74.05 (64.87, 83.22)	<0.001
Level of tumor (cm)	0.65 (−0.58, 1.88)	0.291
Surgery ^a		
VIB	7.31 (2.33, 12.29)	0.005
LI	Reference group	

VIB = Valtrac™-secured intracolonic bypass, LI = loop ileostomy, CI = confidence interval.

^a $P < 0.05$ indicates a significant influence on the corresponding dependent variable revealed by ANCOVA.

Routine use of defunctioning stoma for low anterior resection has been recommended to decrease the leakage rate.^{18,19} However, its effectiveness in reducing AL has been questioned.^{25,26} Using an intracolonic bypass to protect a low rectal anastomosis avoids problems associated with a defunctioning stoma.^{22–24,27} The VIB procedure was performed in open rectal resection, and it was an effective and safe method for protecting the anastomotic site by our and others' studies.^{24,27}

In this study, a VIB was introduced into laparoscopic rectal cancer resection to protect the distal anastomotic site. First of all, the safety was shown in VIB anastomosis itself. General consensus indicates the safety of BAR procedure used in intestinal anastomosis with nearly no reported occurrence of AL.^{28–30} Similarly, we performed the BAR anastomotic procedures in 186 cases with no clinical AL.³¹ However, we emphasized that the BAR should be selected with appropriate size and used in correct manner. The BAR with larger size may induce colonic serosal splits in smaller caliber colon; conversely, the BAR with narrower gap size could not embrace the colon with larger thickness. Furthermore, although condom usage and benefits had been reported, the surgical details for success had been lacking. Here, we illustrated a method for using a conglomerate BAR-condom component that may provide added safety benefits and cost savings, although a randomized, prospective trial is needed.³²

In this series, no mortality and no serious morbidity pertaining to both the VIB anastomosis and the protected distal anastomosis were found. Hence, we conclude that the VIB procedure is a safe and effective diverting technique to protect an elective low

colorectal anastomosis, although the diverting time is limited because the BAR would loosen after about 2 weeks. Theoretically, if adverse factors that hinder the anastomotic healing persists for longer than 2 weeks, the low rectal anastomosis could suffer from leakage and even serious peritonitis.

Apart from general health status, 3 local factors may alter the healing of the rectal anastomosis. First, sufficient microvascularization, a tension-free anastomosis, and the use of proper anastomotic technique are factors of the bowel itself that help ensure anastomotic healing. Secondly, the impulsive force of flatus or defecation play an adverse role on anastomotic healing, hence, a fecal diverting technique may prevent these adverse intra-bowel factors from destroying anastomotic site.³³ Lastly, infiltrating of pelvic effusion and binding of pelvic floor muscle are among the adverse factors impacting low rectal anastomotic healing under the extra-bowel circumstances.³⁴ Therefore, in the case of adverse general condition or intraoperative adverse events such as pelvic bleeding, intestinal rupture, and contamination, a diverting technique to protect the rectal anastomosis is both a wise choice and an effective method. On the other hand, it is emphasized that the extra-bowel and bowel itself factors should be managed in a good condition perioperatively.

If compared with the results of the LI series and the previous literature, the use of VIB in laparoscopic rectal resection seems easy and effective as shown by the low complication rate and comparable outcomes to those reported in the traditional open surgery.^{24,27} In addition, the laparoscopic use of VIB does not require additional or longer abdominal incisions. In fact, the VIB was introduced into the proximal colon using the same incision required for specimen extraction. Furthermore, the laparoscopy has become a definitive milestone in the history of minimally invasive surgery. Non-stoma is reflected in the concepts of minimally invasive surgical strategy. Therefore, VIB is more suitable for laparoscopic rectal resection and more acceptable for the patients both physically and psychologically, neither no stoma nor additional incision is needed. In our experience, the use of the VIB guarantees protecting an elective low colorectal anastomosis, especially during laparoscopic conditions. The proposed VIB technique permits its use without giving up the benefits of laparoscopic access.

Limitations of our study were several-fold: our study was a small retrospective comparative series in a single institution with a short follow-up. It was a nonrandomized retrospective trial so bias in patient selection may have been present. The study lacked adequate power to determine the superiority of the VIB over other diverting techniques. Thus, the findings of this study need to be confirmed by subsequent controlled prospective, randomized studies.

In conclusion, the VIB procedure was as a good partner with the laparoscopic rectal cancer resection, is a safe, effective, but time-limited, diverting technique to protect an elective low colorectal anastomosis.

REFERENCES

- Guillou PJ, Quirke P, Thorpe H, et al. Short-term endpoints of conventional versus laparoscopic-assisted surgery in patients with colorectal cancer (MRC CLASICC trial): multicentre, randomised controlled trial. *Lancet*. 2005;365:1718–1726.
- Park JS, Choi GS, Jun SH, et al. Long-term outcomes after laparoscopic surgery versus open surgery for rectal cancer: a propensity score analysis. *Ann Surg Oncol*. 2013;20:2633–2640.

3. Boutros M, Hippalgaonkar N, Silva E, et al. Laparoscopic resection of rectal cancer results in higher lymph node yield and better short-term outcomes than open surgery: a large single-center comparative study. *Dis Colon Rectum*. 2013;56:679–688.
4. Balik E, Asoglu O, Saglam S, et al. Effects of surgical laparoscopic experience on the short-term postoperative outcome of rectal cancer: results of a high volume single center institution. *Surg Laparosc Endosc Percutan Tech*. 2010;20:93–99.
5. Yeh CY, Changchien CR, Wang JY, et al. Pelvic drainage and other risk factors for leakage after elective anterior resection in rectal cancer patients: prospective study of 978 patients. *Ann Surg*. 2005;241:9–13.
6. Matthiessen P, Hallböök O, Andersson M, et al. Risk factors for anastomotic leakage after anterior resection of the rectum. *Colorectal Dis*. 2004;6:426–429.
7. Peeters KC, Tollenaar RA, Marijnen CA, et al. Risk factors for anastomotic failure after total mesorectal excision of rectal cancer. *Br J Surg*. 2005;92:211–216.
8. Brannagan G, Finnis D. Prognosis after anastomotic leakage in colorectal surgery. *Dis Colon Rectum*. 2005;48:1021–1026.
9. Park JS, Choi GS, Kim SH, et al. Multicenter analysis of risk factors for anastomotic leakage after laparoscopic rectal cancer excision: the Korean laparoscopic colorectal surgery study group. *Ann Surg*. 2013;257:665–671.
10. Park JS, Choi GS, Jun SH, et al. Laparoscopic versus open intersphincteric resection and coloanal anastomosis for low rectal cancer: intermediate-term oncologic outcomes. *Ann Surg*. 2011;254:941–946.
11. Feliciotti F, Guerrieri M, Paganini AM, et al. Long-term results of laparoscopic versus open resections for rectal cancer for 124 unselected patients. *Surg Endosc*. 2003;17:1530–1535.
12. Zhou ZG, Hu M, Li Y, et al. Laparoscopic versus open total mesorectal excision with anal sphincter preservation for low rectal cancer. *Surg Endosc*. 2004;18:1211–1215.
13. Anthuber M, Fuerst A, Elser F, et al. Outcome of laparoscopic surgery for rectal cancer in 101 patients. *Dis Colon Rectum*. 2003;46:1047–1053.
14. Targarona EM, Balague C, Pernas JC, et al. Can we predict immediate outcome after laparoscopic rectal surgery? Multivariate analysis of clinical, anatomic, and pathologic features after 3-dimensional reconstruction of the pelvic anatomy. *Ann Surg*. 2008;247:642–649.
15. Akiyoshi T, Ueno M, Fukunaga Y, et al. Incidence of and risk factors for anastomotic leakage after laparoscopic anterior resection with intracorporeal rectal transection and double-stapling technique anastomosis for rectal cancer. *Am J Surg*. 2011;202:259–264.
16. Bell SW, Walker KG, Rickard MJ, et al. Anastomotic leakage after curative anterior resection results in a higher prevalence of local recurrence. *Br J Surg*. 2003;90:1261–1266.
17. Jung SH, Yu CS, Choi PW, et al. Risk factors and oncologic impact of anastomotic leakage after rectal cancer surgery. *Dis Colon Rectum*. 2008;51:902–908.
18. Hüser N, Michalski CW, Erkan M, et al. Systematic review and meta-analysis of the role of defunctioning stoma in low rectal cancer surgery. *Ann Surg*. 2008;248:52–60.
19. Matthiessen P, Hallböök O, Rutegård J, et al. Defunctioning stoma reduces symptomatic anastomotic leakage after low anterior resection of the rectum for cancer: a randomized multicenter trial. *Ann Surg*. 2007;246:207–214.
20. Tschmelitsch J, Wykypiel H, Prommegger R, et al. Colostomy vs. tube cecostomy for protection of a low anastomosis in rectal cancer. *Arch Surg*. 1999;134:1385–1388.
21. Tocchi A, Mazzoni G, Lepre L, et al. Prospective evaluation of omentoplasty in preventing leakage of colorectal anastomosis. *Dis Colon Rectum*. 2000;43:951–955.
22. Ravo B, Ger R. Intracolonic bypass by an intraluminal tube: an experimental study. *Dis Colon Rectum*. 1984;27:360–365.
23. Yoon WH, Song IS, Chang ES. Intraluminal bypass technique using a condom for protection of coloanal anastomosis. *Dis Colon Rectum*. 1994;37:1046–1047.
24. Ye F, Wang D, Xu X, et al. Use of intracolonic bypass secured by a biodegradable anastomotic ring to protect the low rectal anastomosis. *Dis Colon Rectum*. 2008;51:109–115.
25. Shiomi A, Ito M, Saito N, et al. Diverting stoma in rectal cancer surgery. A retrospective study of 329 patients from Japanese cancer centers. *Int J Colorectal Dis*. 2011;26:79–87.
26. Yoo SB, Jeong SY, Lim SB, et al. Left-sided ileostomy at specimen extraction site in laparoscopic-assisted low anterior resection for rectal cancer. *J Laparoendosc Adv Surg Tech A*. 2013;23:22–25.
27. Chang D, Zhang Y, Dang C, et al. Prevention of anastomotic leakage after low anterior resection in rectal cancers. *Hepatogastroenterology*. 2010;57:477–481.
28. Ghitulescu GA, Morin N, Jetty P, et al. Revisiting the biofragmentable anastomotic ring: is it safe in colonic surgery? *Can J Surg*. 2003;46:92–98.
29. De Fina S, Franciosi C, Codecasa G, et al. The use of the biofragmentable ring (BAR-Valtrac) in colon surgery. *Minerva Chir*. 2000;55:133–137.
30. Wang SM, Lai IR, Liang JT, et al. Colorectal surgery using a biofragmentable anastomotic ring. *J Formos Med Assoc*. 1996;95:798–801.
31. Ye F, Lin JJ. Clinical application of biofragmentable anastomosis ring for intestinal anastomosis. *J Zhejiang Univ Med Sci*. 2006;35:668–672.
32. Morks AN, Havenga K, Ploeg RJ. Can intraluminal devices prevent or reduce colorectal anastomotic leakage: a review. *World J Gastroenterol*. 2011;17:4461–4469.
33. Ji C, Guo X, Li Z. Advantages of the experimental animal hollow organ mechanical testing system for the rat colon rupture pressure test. *Int J Surg*. 2013;11:1110–1113.
34. Peng J, Lu J, Xu Y, et al. Standardized pelvic drainage of anastomotic leaks following anterior resection without diversionary stomas. *Am J Surg*. 2010;199:753–758.