



Use of a double-lumen cytology brush catheter to allow double-guidewire technique for endoscopic interventions

Kavel H. Visrodia, MD,¹ Todd H. Baron, MD,² Georgios Mavrogenis, MD,³ Mark D. Topazian, MD,⁴
Fateh Bazerbachi, MD¹

Background and Aims: Serial stent placement may be necessary during endoscopic interventions, but the passage of a guidewire alongside an initial stent can be challenging, time-consuming, and sometimes unsuccessful. We describe a modification of a cytology brush catheter to allow simultaneous placement of 2 guidewires to facilitate serial stent placement and demonstrate its application in different scenarios.

Methods: This is a retrospective series of 3 patients with different conditions (acute cholecystitis, pancreas pseudocyst, and severe biliary stricture) in whom placement of a second guidewire facilitated serial stent placement. A step-by-step demonstration of the technique is provided.

Results: Serial stent placement was successful in all patients without adverse events.

Conclusions: A modified cytology brush catheter can be used to deliver 2 guidewires simultaneously during ERCP and EUS procedures. This technique may improve procedural efficiency, maintain a safety track, and augment therapy in certain situations. (VideoGIE 2020;5:688-92.)

Serial stent placement may be necessary during endoscopic interventions, such as transpapillary gallbladder drainage or pseudocyst drainage. However, after initial stent placement, the passage of a guidewire alongside the stent, especially during the index procedure, can be challenging, time-consuming, and sometimes unsuccessful. This may be avoided by preserving access with simultaneous placement of a second guidewire when access is initially achieved.

To facilitate this maneuver, a kit fashioned from a 22-gauge FNA needle and an inner and outer catheter has been described, but this requires assembly and is not applicable to non-EUS-guided interventions.¹ More recently, a double-lumen catheter specifically designed for the simultaneous placement of 2 guidewires has been released, but its distribution is currently limited to Japan (personal communication; Piolax Medical Devices, INC., Yokohama, Kanagawa, Japan; July 8, 2020).² We describe a simple modification of an available cytology brush catheter to facilitate the placement of a second guidewire and demonstrate its application in the management of patients in 3 distinct scenarios (Video 1, available online at www.giejournal.org).

TECHNIQUE

We demonstrate this technique using a wire-guided cytology brush catheter (Rx Cytology Brush, Boston Scien-

tific, Natick, Mass, USA), although other double-/triple-lumen devices have been described for this application.^{3,4} Note that this is an off-label use of this device. The model shown is an 8F (2.7-mm diameter by 200-cm length) catheter with a slightly tapered tip that contains a radiopaque marker (Fig. 1). Because it is wire guided, the catheter has 2 lumens, one for the brush and the other for the guidewire.

In the first step, the brush is advanced using the brush handle, and a wire cutter is used to remove the brush tip. The brush handle and wire are then withdrawn completely. The catheter's 2 lumens can now each accommodate up to a 0.035-inch guidewire. Once access to the desired location (eg, gallbladder, pseudocyst, upstream from a tight stricture) has been achieved, in step 2, the catheter is backloaded onto the existing guidewire. Importantly, this should be done using the wire-guided lumen intended for short exchange and the wires used should be long (≥ 450 cm), especially in drainage procedures, to allow adequate coiling and for exchange when the wire cannot be locked in the endoscope elevator.

The catheter is then passed through the endoscope instrument channel and into the desired location. In step 3, the cap on the back end of the cytology brush port is unscrewed, and the second guidewire is passed (antegrade) in parallel to the existing guidewire and into the desired location. Once both guidewires are




Figure 1. Preparation of the dual-lumen cytology brush catheter with (A) cutting of the cytology brush tip and removal of the remaining wire from the brush lumen, (B) backloading the catheter onto the first guidewire (retrograde through the guiding wire lumen), and (C) unscrewing the brush port cap to pass the second guidewire (antegrade) through the brush lumen parallel to the first guidewire and into the desired location.

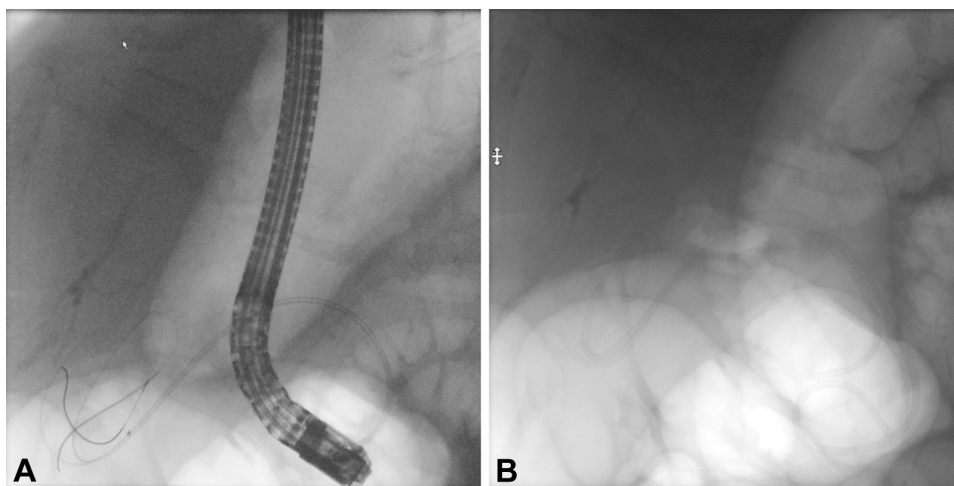


Figure 2. Acute cholecystitis treated with ERCP transpapillary gallbladder stents, facilitated by (A) placement of a cytology brush catheter and second guidewire allowing (B) placement of 2 stents across a tight cystic duct to improve drainage.

confirmed to be in an appropriate position, the cytology brush catheter can be removed by advancing both wires simultaneously using the long exchange technique for the guidewire in the cytology brush lumen and the short exchange technique for the guidewire in the wire-guided lumen.

CASE 1

An 80-year-old woman with dementia presented with recurrent cholecystitis (Fig. 2). Eighteen months earlier, cholecystitis was managed by percutaneous cholecystostomy tube placement. Subsequent cholecystoduodenostomy was not

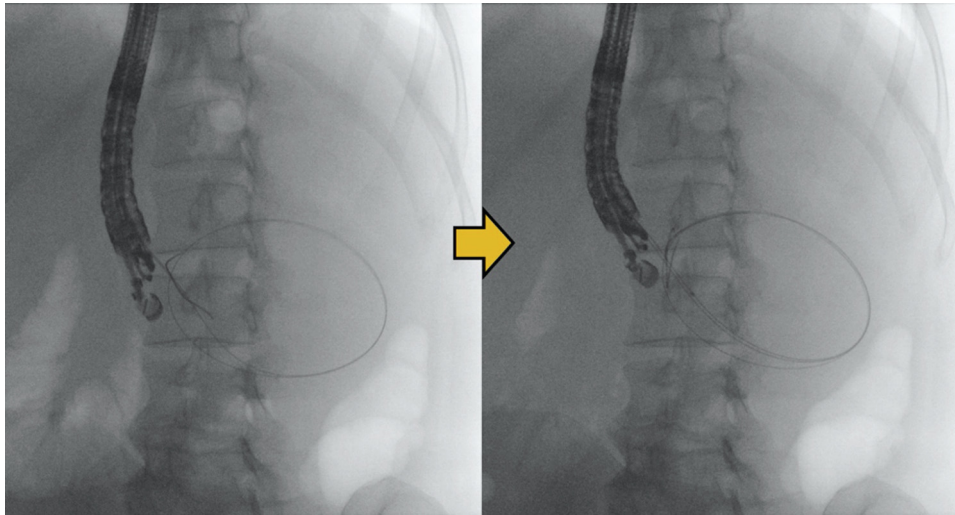


Figure 3. Infected pancreatic pseudocyst (7.5 cm) managed with EUS-guided placement of 2 plastic double-pigtail stents facilitated by use of the cytology brush catheter and double guidewire placement.

feasible for anatomic reasons, so drainage was internalized with ERCP and a single transpapillary 7F plastic stent. On readmission, she was started on antibiotics, and after a multidisciplinary discussion it was decided to repeat ERCP for stent exchange for probable stent occlusion.

Initial attempts were made to pass a 0.035-inch and then a 0.025-inch guidewire alongside the existing transpapillary gallbladder stent, but deep access to the gallbladder was unsuccessful because of a tight cystic duct. This demonstrates the difficulty of passing a guidewire along an existing stent. The cystic duct was partially accessed with the guidewire while the existing stent was carefully removed. The guidewire was then advanced deeply into the gallbladder. The cystic duct was dilated with a 4-mm biliary balloon. A cytology brush catheter was then prepared and passed over the existing guidewire. A second guidewire was then passed easily into the gallbladder. The first 7F double-pigtail plastic stent was deployed. A second identical stent was then successfully passed, albeit with significant difficulty, and deployed with the intention to prolong time to reintervention by allowing drainage between the 2 stents via the wicking effect.

CASE 2

A 43-year-old woman with a history of polysubstance abuse and recurrent acute alcoholic pancreatitis presented with *Escherichia coli* bacteremia and a 7.5-cm pseudocyst in the pancreas tail (Fig. 3). EUS-guided drainage was performed. The pseudocyst was punctured through the gastric wall with a 19-gauge FNA needle, and after aspiration for fluid studies, a 0.035-inch guidewire was coiled in the cyst cavity. A 4-mm biliary balloon was used to dilate the cystgastrostomy tract. The cytology brush catheter was advanced over the first guidewire into the cyst cavity. A

second 0.035-inch guidewire was coiled in the cyst cavity. The guidewires were then used to sequentially deploy 7F and 10F double-pigtail plastic stents.

CASE 3

A 43-year-old man with pancreas head adenocarcinoma was admitted with cholangitis secondary to stent occlusion 2 months after uncovered biliary metal stent placement (Fig. 4). Repeat ERCP showed severe tumor ingrowth and a very tight stricture in the midportion of the stent. Passing an angled 0.035-inch hydrophilic guidewire into the proximal bile duct was challenging, given stricture severity and intervening stent interstices. After the eventual passage of the guidewire, dilation of the stricture was considered but ultimately deferred because of the risk of intraprocedural bleeding and the inability to place a covered metal stent for fear of jailing the cystic duct of an in situ gallbladder. To allow placement of 2 parallel stents, 2 guidewires were introduced via the cytology brush catheter, and two 8.5F Amsterdam-type plastic stents were sequentially deployed across the stricture.

DISCUSSION

When performing therapeutic endoscopy, the ability to place 2 or more guidewires at once provides advantages from an efficiency standpoint, maintenance of safe access, and ability to deliver augmented therapy that may not otherwise be feasible. For example, a recent study of ERCP-guided gallbladder drainage demonstrated that almost a third of patients undergo a second procedure to upsize and add a second stent when only a single stent is

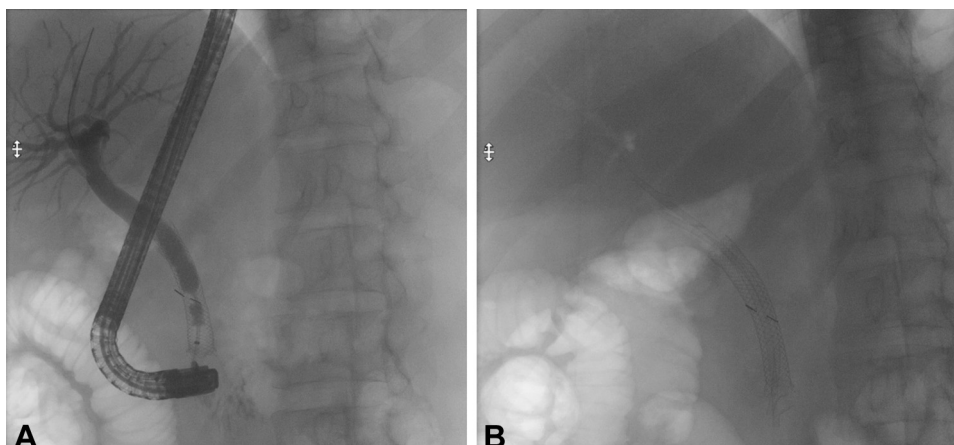


Figure 4. Acute cholangitis secondary to (A) severe stricture from ingrowth of an uncovered metal stent for pancreas adenocarcinoma (B) with the use of the cytology brush catheter to facilitate serial stent placement.

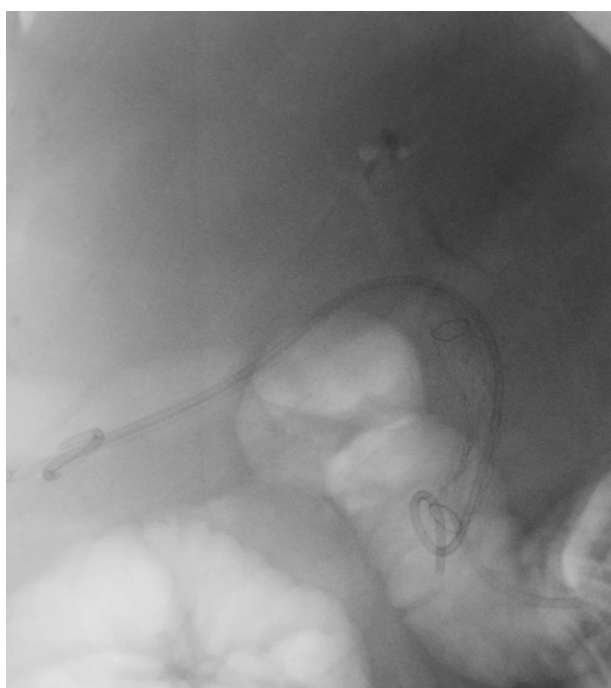


Figure 5. Distal cholangiocarcinoma and cholecystitis treated with transpapillary gallbladder drainage using the modified brush technique, followed by fully covered metal stent placement in the common bile duct to alleviate jaundice.

placed.⁵ Another example is to mitigate the risk of iatrogenic cholecystitis when a fully covered metal stent is placed across the common bile duct and a low-lying cystic duct insertion is present. In such a scenario, we have attempted to place 2 protective stents into the gallbladder using this technique, followed by deploying a parallel, fully covered metal stent (Fig. 5). We have also found that the use of this technique is essential in certain EUS-guided interventions such as pancreaticogastrostomies, where placement of an additional guidewire through the

gastric wall and pancreatic parenchyma into the pancreatic duct would otherwise not be possible.

It must be recognized that the method presented here is not as versatile as using a dedicated uneven double-lumen cannula, especially for EUS-guided interventions. The catheter presented is 8F, compared with the 3.6F cannula. However, the catheter tapers to a single lumen in the approximately 1-cm tip to facilitate crossing of tight strictures/tracts. Moreover, the brush will accommodate two 0.035-inch wires, unlike the cannula, which accommodates a 0.035-inch wire and a 0.025-inch wire.² Nonetheless, the availability of endoscopic accessories is center-dependent, and this is a motivation for the off-label modification of available equipment to address complex clinical scenarios.

In conclusion, we demonstrate different scenarios wherein a modified cytology brush can be used to deliver 2 guidewires simultaneously during ERCP and EUS procedures. This may improve procedural efficiency, maintain a safety track, and augment therapy delivered in certain situations. The Food and Drug Administration approval of new tools for ERCP and EUS should be further streamlined and investigated, and the cost-effectiveness of these devices should also be examined.

DISCLOSURE

Dr Baron is a consultant for Boston Scientific, Cook Endoscopy, Medtronic, and Olympus. All other authors disclosed no financial relationships.

REFERENCES

1. Seewald S, Thonke F, Ang TL, et al. One-step, simultaneous double-wire technique facilitates pancreatic pseudocyst and abscess drainage (with videos). *Gastrointest Endosc* 2006;64:805-8.
2. Nakai Y, Oyama H, Kanai S, et al. Double guidewire technique using an uneven double lumen catheter for endoscopic ultrasound-guided interventions. *Dig Dis Sci*. Epub 2020 May 20.

3. Khashab MA, Lennon AM, Singh VK, et al. Endoscopic ultrasound (EUS)-guided pseudocyst drainage as a one-step procedure using a novel multiple-wire insertion technique (with video). *Surg Endosc* 2012;26:3320-3.
4. Evans JA, Conway JD, Mishra G. A novel method for performing multiple wire insertions during endoscopic cyst gastrostomy. *Gastrointest Endosc* 2010;71:612-4.
5. Kaura K, Bazerbachi F, Sawas T, et al. Surgical outcomes of ERCP-guided transpapillary gallbladder drainage versus percutaneous cholecystostomy as bridging therapies for acute cholecystitis followed by interval cholecystectomy. *HPB (Oxford)* 2020;22:996-1003.

Division of Gastroenterology, Massachusetts General Hospital, Boston, Massachusetts (1), Division of Gastroenterology and Hepatology, Univer-

sity of North Carolina, Chapel Hill, North Carolina (2), Department of Gastroenterology, Mediterraneo Hospital, Athens, Greece (3), Division of Gastroenterology and Hepatology, Mayo Clinic, Rochester, Minnesota (4).

Copyright © 2020 American Society for Gastrointestinal Endoscopy. Published by Elsevier Inc. This is an open access article under the CC BY-NC-ND license (<http://creativecommons.org/licenses/by-nc-nd/4.0/>).

<https://doi.org/10.1016/j.vgie.2020.08.016>

If you would like to chat with an author of this article, you may contact Dr Bazerbachi at FBAZERBACHI@mg.harvard.edu.

Read Articles in Press Online Today!
Visit www.videogie.org

VideoGIE posts in-press articles online in advance of their appearance in a monthly edition of the journal. These articles are available on the *VideoGIE* website by clicking on the “Articles in Press” tab. Articles in Press represent the final edited text of articles that are accepted for publication but not yet scheduled to appear in a specific issue. They are considered officially published as of the date of Web publication, which means readers can access the information and authors can cite the research months prior to its availability in an issue. To cite Articles in Press, include the journal title, year, and the article’s Digital Object Identifier (DOI), located in the article footnote. Visit the website today to stay current on the latest research in the field of gastrointestinal endoscopy.