

# Evaluate the Results at Minimum 2-Years of Treating Rotator Cuff Tear by Arthroscopic Surgery

Dung Tran Trung<sup>1,2,3\*</sup>, Duc Nguyen Anh<sup>4</sup>, Tuan Tran Duc<sup>5</sup>, Van Nguyen Trung<sup>6</sup>, Thien Chu Dinh<sup>7</sup>

<sup>1</sup>Saint Paul General Hospital, Hanoi, Vietnam; <sup>2</sup>Hanoi Medical University Hospital, Hanoi, Vietnam; <sup>3</sup>Hanoi Medical University, Hanoi, Vietnam; <sup>4</sup>198 Hospital, Hanoi, Vietnam; <sup>5</sup>Ha Tinh General Hospital, Ha Tinh, Vietnam; <sup>6</sup>Nam Dinh General Hospital, Nam Dinh, Vietnam; <sup>7</sup>Institute for Research and Development, Duy Tan University, 03 Quang Trung, Danang, Vietnam

## Abstract

**Citation:** Trung DT, Anh DN, Duc TT, Trung VN, Chu Dinh T. Evaluate the Results at Minimum 2-Years of Treating Rotator Cuff Tear by Arthroscopic Surgery. Open Access Maced J Med Sci. 2019 Dec 30; 7(24):4199-4203. <https://doi.org/10.3889/oamjms.2019.358>

**Keywords:** Rotator cuff tear; Shoulder arthroscopy; UCLA; Quality of life

**\*Correspondence:** Tran Trung Dung, Hanoi Medical University, Hanoi, Vietnam; E-mail: [dungbacsy@dungbacsy.com](mailto:dungbacsy@dungbacsy.com)

**Received:** 10-Sep-2019; **Revised:** 20-Nov-2019; **Accepted:** 21-Nov-2019; **Online first:** 15-Oct-2019

**Copyright:** © 2019 Dung Tran Trung, Duc Nguyen Anh, Tuan Tran Duc, Van Nguyen Trung, Thien Chu Dinh. This is an open-access article distributed under the terms of the Creative Commons Attribution-NonCommercial 4.0 International License (CC BY-NC 4.0)

**Funding:** This research did not receive any financial support

**Competing Interests:** The authors have declared that no competing interests exist

**BACKGROUND:** Rotator cuff tear (RCT) is a common injury of the shoulder, especially middle-aged people. Nonoperative treatment, cortisone injections are only effective at an early stage. Open surgery causes postoperative atrophy of the deltoid muscle, so results are limited. Arthroscopic rotator cuff repair surgery has been performed in Vietnam for about ten years, with many advantages such as the ability to accurately assess the lesions and less invasive procedure. In order to have a clearer view, we performed a mid-term assessment of the effectiveness of this surgery.

**AIM:** Evaluate results over 2 years of patients with rotator cuff tears treated with arthroscopic surgery and their quality of life.

**METHOD:** A group of 30 patients were diagnosed with RCT and surgery by arthroscopy to treat at Hanoi Medical University Hospital and Saint Paul Hospital between Jun 2015 and April 2017. The results of the surgeries were assessed by the degree of pain, muscle power, motion of the shoulder joint according to UCLA shoulder score. Evaluate the quality of life through the Rotator Cuff-Quality of Life (RC-QoL) index.

**RESULTS:** The average age was 60.7 years. Female / male ratio was 1.3. Thirty-six months  $\pm$  6.41 was the average follow-up time (min 27 – max 50 months). The shoulder function is recorded according to UCLA has an average score of 30.9, therein good and excellent result were 90 %. The mean RC-QoL index was 91.5%.

**CONCLUSION:** Treatment of RCT by arthroscopic surgery that has been evaluated for a minimum of 2 years follow-up showed good results and high quality of patient's life.

## Introduction

Rotator cuff (RC) is a muscle-tendon group that attaches to the head of the humerus, includes 4 muscles (in order from anterior to posterior) which are the supraspinatus, subscapularis, infraspinatus and teres minor. Rotator cuff tear (RCT) is a common injury of the shoulder [1], especially middle-aged people. The characteristic of a rotator cuff tear injury is that once it is torn, it cannot heal by itself, so if the suture is not performed, the progression of the torn tendon will be more and more widespread so that it cannot be stitched recover again [2]. The final consequence is that the head of the humerus will be migrated superiorly lead to limit shoulder movement

and degeneration [3].

Arthroscopic rotator cuff repair surgery has been performed in Vietnam for a decade; it has many advantages such as the ability to accurately assess the lesions and minimally invasive procedure, so it facilitates patients to recover after surgery earlier [4], [5]. Previously, the authors had performed open surgery to treat rotator cuff tear, but it caused postoperative atrophy of the deltoid muscle, so the results were still limited [6]. Nonoperative measures such as rest, physical therapy, NSAIDs [7] or cortisone injections are only effective at an early stage [8]. Thus, with the current surgery trend, the gold standard for RCT treatment is arthroscopic surgery [9].

In Vietnam, there has not been any

assessment focusing on the mid-term outcomes of arthroscopic surgery for the treatment of RCT. Therefore, for a clearer view of the effectiveness of this surgery in Vietnam, we chose the time to assess the outcomes is at least 2 years after surgery, especially considering the quality of patient's life.

## Materials and Method

### Research method

A retrospective descriptive study.

### Inclusion criteria

Thirty patients were diagnosed with RCT from partial-thickness tear grade 3 (Ellman's classification) to large tear (De Orto and Cofield classification) and surgery by arthroscopy to treat at Hanoi Medical University Hospital and Saint Paul Hospital between Jun 2015 and April 2017.

Patients with complete records of research content and re-examination after at minimum 2-years of surgery.

### Exclusion criteria

*Massive and irreparable RCTs. RCTs but no tendon suture indication, just debridement of the lesion, acromioplasty.* Patients lost follow-up and did not re-examination after at minimum 2-years of surgery.

### Operative technique

We placed the patient in the "Beach Chair" position. Probing the shoulder joint through a posterior portal, the corresponding point between the infraspinatus and teres minor. Then we opened the lateral portal to view into subacromial space and anterior-lateral portal for working. Performed debride of the lesion, acromioplasty (especially at one – third anterior-lateral position of acromion), identify rotator cuff tear.

Refreshing the tendons tear, release and mobilise the tendons, prepare footprint. RCTs were repaired by single-row suture anchor technique.

Place a hemovac drain into the shoulder joint, after that patient was worn the sling with a small pillow to abductor 20 degrees of their shoulder and keep it up to 4 weeks. All patients after surgery are rehabilitated at the same facility with a team of experts agreed on the viewpoint and practice method.

### Evaluation

Patients were invited to re-examination, then they were assessed according to the UCLA score and RC-QoL index [10].

### Statistic

Data were processed by SPSS 20.0 software. Comparing the average values of the groups, we used the Student's t-test. A significant difference was defined as  $p < 0.05$ .

## Result

The mean age of 30 patients in the study group was 60.7 years old (36-79). In which, the age group over 65 accounts for the highest rate, 46.66%. Female: male ratio is 1.3:1. The average follow-up time is 36 months  $\pm$  6.41 months (min 27 – max 50 months). Tearing partial-thickness RC tendon is 4 cases, accounted for 13.33%. Tearing full-thickness RC tendon is 26 cases (86.66%), among all sizes of total tear, medium-sized tears prevail 11 / 26 or 42%.

All of the patients had subacromial impingement syndrome, and they all proceed an acromioplasty, the tendon tears were repaired by single-row suture anchor technique (Figure 1). No patients with trauma to the shoulder had surgery lead to re-tear.

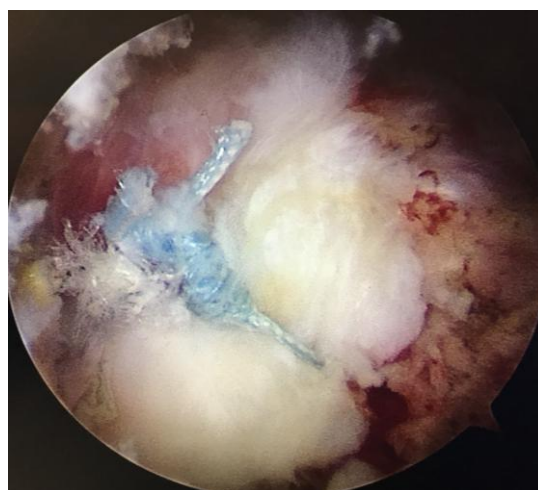


Figure 1: Single-row technique

The mean UCLA score is 30.9 (range 23-35), therein good and excellent result is 90 %. Particularly for pain assessment, the rate of painless patients was 86.66%; the remaining 13.33% were occasional and slight pain. The rate of patients satisfied with the current situation is 29 / 30 patients (96.66%).

The mean RC-QoL index at the final of the study was 91.5%  $\pm$  5.6 (78.33 – 99.1%). The rate of

patients returning to previous work is 100%.

Comparing the correlation of UCLA and RC-QoL average score with the characteristics of study subjects such as gender, age, trauma factor or between sizes of complete tear were the surgical results did not depend on the above factors. The p-value in these tests was all > 0.05. Details are recorded according to Table 1.

**Table 1: Correlation of UCLA and RC-QoL average score with the characteristics of study subjects**

Characteristics	Patients (n)	UCLA score	P (UCLA)	RC – QoL index	P (RC – QoL)
Gender					
Male	13	30.69 ± 3.83		91.62 ± 5.46	
Female	17	31.06 ± 2.83	0.76	91.45 ± 5.87	0.93
Age					
< 55	8	31.88 ± 3.64		92.07 ± 7.23	
55 – 65	8	31.13 ± 3.37	0.518	92.41 ± 4.80	0.762
≥ 65	14	30.21 ± 3.04		90.70 ± 5.30	
Trauma factor					
Yes	12	30.42 ± 3.96		91.33 ± 5.30	
No	18	31.22 ± 2.75	0.51	91.65 ± 5.94	0.879
Sizes of total tear					
Small	6	31.0 ± 4.33		92.29 ± 6.04	
Medium	11	31.36 ± 2.58	0.17	92.23 ± 4.2	0.86
Large	9	28.78 ± 3.17		87.37 ± 5.46	

However, the correlation of both UCLA and RC-QoL mean between the partial-tear group and the total-tear group found a statistically significant difference. The p-value of the two tests was all > 0.05 (table2). In other words, the type of tear is the impact factor on the outcome of shoulder function after surgery. This means that the quality of a patient’s life with partial-thickness tear has significantly better postoperative results than the group with a full-thickness tear.

**Table 2: Correlation of UCLA and RC-QoL average score with the type of tear**

Characteristics	Patients (n)	UCLA score	P (UCLA)	RC – QoL index	P (RC – QoL)
Type of tear					
Partial-thickness	4	34.25 ± 0.95		97.75 ± 0.83	
Full-thickness	26	30.38 ± 3.17	0.024	90.56 ± 5.40	0.00

At the last re-examination, none of the patients had delta muscle atrophy, no patients had numbness of the shoulder injury, no cases of shoulder stiffness, but there was a common point in patients with large tear is limited hand movements behind the back.

## Discussion

The mean age in this study was 60.7 years, with most of the participants were in the over 65 groups. This observation was in line with the etiologies in which the intrinsic causes are the tendon degeneration due to reduced vascularisation, thinning of the collagen fibres while the extrinsic causes are subacromial impingement syndrome and microtrauma [3]. Besides, 17 patients had rotator cuff tear without the history of trauma; they suffered from progressive

shoulder pain in many years. Only 13 patients had a traumatic factor, but some of them are even minor trauma. As a result, trauma is a positive factor which helps deteriorate the existing rotator cuff degeneration or tear. Therefore, age is a bad prognosis factor to heal of RC tendon. This idea is also supported by several authors [11], [12]. However, this is not the only factor involves the outcome of shoulder joint function because, when comparing the scores of UCLA and RC-QoL between the under 55 group, 55 to 65 group and over 65 groups, there was no statistical significance. The mean satisfaction reached 96.66% because the elderly subjects only need the shoulder joint to perform basic daily activities. Additionally, the traumatic factor does not influence the final result of the surgery.

The average UCLA score for the whole group is 30.9, which belongs to the group with good results; this result is similar to some domestic studies [13]. When compared with the results of other international authors such as Marrero [14] who showed the average UCLA score of 31.8 (33 patients, regardless of tear size) or Castagna [15] with the score of 30.8 (29 patients, with minimum 24 months follow-up), one thing must be pointed out that the above results were the scores of the affected shoulder joint. However, when examining the unaffected shoulder joint with both scales, the maximum score could not be reached. The reason is the rotator cuff of the unaffected shoulder is also degenerative and starts to hurt. Many patients even complained that the unaffected shoulder is more painful than the operated shoulder. The pain reduction or pain elimination is the main factor determining the quality of life of the patient (this assertion is also postulated by many authors, typically Arrigoni [16]), which is consistent with the average RC-QoL score in this study of 91.5%. Some patients have forgotten which side has been operated until being called for follow-up.

The mean score of both UCLA and RC-QoL between the partial-thickness tear group and the full-thickness tear group found a statistically significant difference. Thus, the type of tear is the prognostic factor affecting the outcome of shoulder joint function. Some studies by Park [17] or Marrero [14] do not support this view, saying that the results of these two groups were equal. Perhaps, there is no randomisation in term of quantity, age and gender in these 2 groups in our study. More studies with larger sample sizes are needed to assess this judgment accurately. However, in the total tear type, all authors agreed that the grade 2 rotator cuff is the most common. Haviv [18] conducted a study on 607 patients and found that small and medium tear accounted for 69%; this proportion in our study was 65.38% (17/26). This study has the limitation that does not evaluate the time before surgery, the early results after surgery but focusing on assessing at least the minimum 2 years, so it is not possible to compare the level of improvement before and after the

surgery, or whether good results are maintained up to mid-term.

We used the Beach-chair position to surgery for all patients in our research. This position has the advantage of not needing to use a commercially available arm supporter like a lateral decubitus position, and importantly it objectively assesses the extent of *subacromial impingement* and easily identifies whether *the* subacromial space after acromioplasty has been suitable. We selected a single-row suturing method for all groups of patients in this study with the reason that although there have been a lot of investigations arguing about different suturing techniques, in the long-term study of Spennacchio [19], no difference in clinical results between single-row suture anchor technique and double-row. Also, a systematic review [20] concluded that there was no statistically significant difference in the shoulder joint function different suturing techniques. Moreover, this option is suitable for the financial conditions of many patients in Vietnam and still delivers acceptable outcomes.

Following the analysis results of this research, we recommend that if the patient has been diagnosed with rotator cuff tear (even if they are older patient) and nonoperative measures do not improve; it does not need to wait for sufficient time, number of treatment sessions that should proactively conduct surgery early (when still in the partial-tear grade) to solve the current symptoms, causes, reduce and overcome the consequences of rotator cuff tear injury.

In conclusion, through research 30 patients who have undergone arthroscopic repair of RCTs, can be determined that in addition to the advantages such as small incision the advantages of small incision, minimally invasive, accurately assess the lesions, after over 2 years (the average evaluation time was 36 months) arthroscopic surgery to repair RC tendon give good results of shoulder function and high quality of patient life. Patients satisfaction reached 96.66%.

## Ethical Approval

The medical ethics committee of Hanoi Medical University agreed to approve this study in Decision No. 4235.

## Informed consent

The consent and commitment were signed by the patients in this research.

## References

- White J, et al. An epidemiological study of rotator cuff pathology using The Health Improvement Network database. *The bone & joint journal*. 2014; 96(3):350-353. <https://doi.org/10.1302/0301-620X.96B3.32336> PMID:24589790
- Nho SJ, et al. Rotator cuff degeneration: etiology and pathogenesis. *The American journal of sports medicine*. 2008; 36(5):987-993. <https://doi.org/10.1177/0363546508317344> PMID:18413681
- Angelo RL, Esch J, Ryu RK. AANA Advanced Arthroscopy: The Shoulder E-Book: Expert Consult: Online, Print and DVD. Elsevier Health Sciences; 2010.
- Gartsman GM, Khan M, Hammerman SM. Arthroscopic repair of full-thickness tears of the rotator cuff. *JBJS*. 1998; 80(6):832-40. <https://doi.org/10.2106/00004623-199806000-00007> PMID:9655101
- Miyazaki AN, et al. Avaliação dos resultados das reoperações de pacientes com lesões do manguito rotador. *Rev Bras Ortop*. 2011; 46(1):45-50. <https://doi.org/10.1590/S0102-36162011000100009> PMID:27026985
- Hata Y, et al. Atrophy of the deltoid muscle following rotator cuff surgery. *JBJS*. 2004; 86(7):1414-1419. <https://doi.org/10.2106/00004623-200407000-00008> PMID:15252087
- Mantone JK, Burkhead Jr WZ, Noonan Jr J. Nonoperative treatment of rotator cuff tears. *Orthopedic Clinics of North America*. 2000; 31(2):295-311. [https://doi.org/10.1016/S0030-5898\(05\)70149-8](https://doi.org/10.1016/S0030-5898(05)70149-8)
- CHARLES S NEER II. Anterior acromioplasty for the chronic impingement syndrome in the shoulder: a preliminary report. *JBJS*. 1972; 54(1):41-50. <https://doi.org/10.2106/00004623-197254010-00003>
- Duquin TR, Buyea C, Bisson LJ. Which method of rotator cuff repair leads to the highest rate of structural healing? A systematic review. *Am J Sports Med*. 2010; 38(4):835-41. <https://doi.org/10.1177/0363546509359679> PMID:20357403
- Hollinshead RM, et al. Two 6-year follow-up studies of large and massive rotator cuff tears: comparison of outcome measures. *J Shoulder Elbow Surg*. 2000; 9(5):373-81. <https://doi.org/10.1067/mse.2000.108389> PMID:11075319
- Dung TT. Corticoid injection for subacromial impingement syndrome treatment. *J Practical Medicine*. 2014; 1:32-34.
- Chung SW, et al. Quality of life after arthroscopic rotator cuff repair: evaluation using SF-36 and an analysis of affecting clinical factors. *The American journal of sports medicine*. 2012; 40(3):631-639. <https://doi.org/10.1177/0363546511430309> PMID:22190415
- Anh THN. Result of arthroscopic rotator cuff repair. Ho Chi Minh City Medicine and Pharmacy University: Ho Chi Minh City, 2014.
- Marrero LG, Nelman KR, Nottage WM. Long-term follow-up of arthroscopic rotator cuff repair. *Arthroscopy*. 2011; 27(7):885-8. <https://doi.org/10.1016/j.arthro.2011.02.019> PMID:21620635
- Castagna A, et al. Arthroscopic repair of rotator cuff tear with a modified Mason-Allen stitch: mid-term clinical and ultrasound outcomes. *Knee Surg Sports Traumatol Arthrosc*. 2008; 16(5):497-503. <https://doi.org/10.1007/s00167-007-0461-2> PMID:18273602
- Arrigoni P, et al. Functional repair in massive immobile rotator cuff tears leads to satisfactory quality of living: results at 3-year follow-up. *Musculoskelet Surg*. 2013; 97(1):73-7. <https://doi.org/10.1007/s12306-013-0252-5> PMID:23588825
- Park JY, Chung KT, Yoo MJ. A serial comparison of arthroscopic repairs for partial-and full-thickness rotator cuff tears. *Arthroscopy: The Journal of Arthroscopic & Related Surgery*. 2004; 20(7):705-711. [https://doi.org/10.1016/S0749-8063\(04\)00598-5](https://doi.org/10.1016/S0749-8063(04)00598-5)
- Haviv B, et al. Arthroscopic rotator cuff repair: clinical outcome

of 607 patients. *Knee Surg Sports Traumatol Arthrosc.* 2010; 18(12):1707-11. <https://doi.org/10.1007/s00167-010-1091-7>  
PMid:20217391

19. Spennacchio P, et al. Long-term outcome after arthroscopic rotator cuff treatment. *Knee Surg Sports Traumatol Arthrosc.* 2015; 23(2):523-9. <https://doi.org/10.1007/s00167-014-3234-8>  
PMid:25145945

20. Saridakis P, Jones G. Outcomes of single-row and double-row arthroscopic rotator cuff repair: a systematic review. *J Bone Joint Surg Am.* 2010; 92(3):732-42. <https://doi.org/10.2106/JBJS.I.01295>  
PMid:20194334