



Contents lists available at ScienceDirect

International Journal of Surgery Case Reports

journal homepage: www.casereports.com

Nematode infection: A rare mimic of acute appendicitis



Andrew Hotchen*, Kian Chin, Mahzar Raja

Department of Surgery, Milton Keynes General Hospital, Milton Keynes MK65LD, UK

ARTICLE INFO

Article history:

Received 6 April 2014

Accepted 14 May 2014

Available online 24 June 2014

Keywords:

Appendicitis

Right iliac fossa pain

Nematode

Helminth

Laparoscopy

ABSTRACT

INTRODUCTION: Acute appendicitis is a common condition seen in all surgical units. One rare condition that can mimic acute appendicitis is a nematode infection of the bowel. There have been few reported cases of nematode infection within the appendix and none that have been accompanied by intra-operative pictures.

PRESENTATION OF CASE: A 16-year-old female presented with a 12 h history of right iliac fossa pain and mild pyrexia. Bloods showed a neutrophilia and normal C-reactive protein. Laparoscopy was performed which revealed a non-inflamed appendix. The appendix was dissected and a live nematode was visualised exiting the base of the appendix. Anti-helminthics were given and the infection resolved.

DISCUSSION: Nematode infection is most commonly seen in Africa, Asia and South America. When seen within the United Kingdom (UK), it is seen most commonly within high-risk populations. Testing for these infections is not routine within the UK and when they are performed, the results take a considerable amount of time to return. These tests should be considered within high-risk populations so that unnecessary surgery can be avoided.

CONCLUSION: This case highlights the importance of considering rare causes of right iliac fossa pain including nematode infection in a young patient. The case highlights this by giving intra-operative pictures of live nematodes upon dissection of the appendix.

© 2014 The Authors. Published by Elsevier Ltd. on behalf of Surgical Associates Ltd. This is an open access article under the CC BY-NC-SA license (<http://creativecommons.org/licenses/by-nc-sa/3.0/>).

1. Introduction

Acute appendicitis is commonly encountered in most, if not all general surgical units and can be challenging to diagnose. Knowledge regarding other possible differentials and subsequent management is important. Only a handful of cases have shown nematode infections to mimic the presentation of acute appendicitis.¹ Although nematode infection in the United Kingdom is rare, the most common nematode parasite worldwide is *Enterobius vermicularis* with an estimated 200 million people affected.¹

Here, we present a case of nematode infection mimicking acute appendicitis in a 16-year-old female with intra-operative pictures showing the parasite within the lumen of the appendix.

2. Presentation of case

A 16-year-old female was admitted with a 12 h history of generalised abdominal pain that localised to the right iliac fossa. The onset of pain was sudden, initially colicky in nature and faded away after several hours. Approximately 6 h later, the pain had suddenly returned. It was sharp and stabbing in nature and was localised

to the right iliac fossa. The pain was exacerbated by movement and relieved by simple analgesia. She did not experience nausea or vomiting. She had no other medical or surgical problems and was otherwise fit and well.

On examination the patient had a soft, non-distended abdomen that was tender in the right iliac fossa with guarding. Bowel sounds were normal. On admission, the patient had a temperature of 37.4 °C and all bedside observations were normal. Plain abdominal and erect chest films revealed no obvious abnormalities. Haematological investigations demonstrated a neutrophilia of 9.6 and leucocytosis of 15,000/cmm. All other biochemical tests were normal including c-reactive protein, urea and electrolytes, liver function tests and amylase.

There is a high-false positive rate for the clinical diagnosis of acute appendicitis where a normal appendix is removed in 25% of cases.² Despite this, laparoscopy was performed. A non-inflamed appendix was found and dissected from the meso-appendix. After loop tying the base and another tie distally, the appendix was dissected. However, surprisingly, at the appendix stump, a live nematode appeared from the lumen and this is shown in Fig. 1. Suction was applied to the stump in order to capture the nematode.

Histological analysis described a normal looking appendix of 95 mm in length and 5 mm in diameter with no significant pathological abnormality. The patient was discharged the following day with a course of anti-helminthics. No further follow up was arranged.

* Corresponding author. Tel.: +44 01908 660033.

E-mail addresses: andrew.hotchen@mkhospital.nhs.uk, andy.hotchen@gmail.com (A. Hotchen).

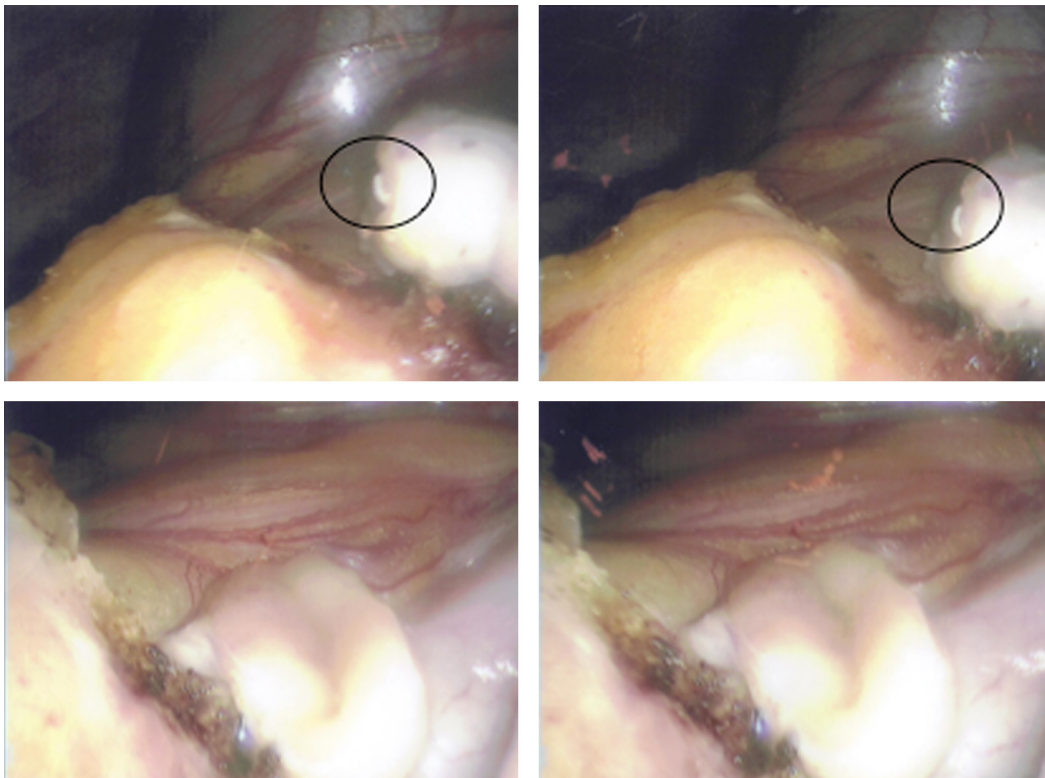


Fig. 1. Laparoscopic view of nematode exiting the lumen of the base of the appendix – seen within highlighted circle.

3. Discussion

Accurate prevalence figures for gastrointestinal parasites within the UK and other European countries are almost impossible to obtain. The vast majority of research and literature has concentrated on areas of high prevalence including Asia, South America, and Africa.²

Gastrointestinal parasite infections are most prevalent in areas of poverty, in low and middle-income countries. However, they still affect many countries in Europe including the UK. Here, the infection is highest amongst the immigrant and refugees communities, but other communities may not be immune.³ Studies have shown outbreaks of infection in the UK and USA have been associated with recreational waters.⁴ Often, it is faecal accidents that occur in swimming pools that have been implicated in a number of the cases. However, contamination of other water sources, such as water slides, fountains and water parks can also increase the risk and spread of infection.⁴

The mimicking of acute appendicitis by nematode infection has been reported, with some case reports providing histological evidence. However, this is one of the first instances of actual images taken during diagnostic laparoscopy capturing the nematode within the lumen of the appendiceal base being published (Fig. 1).

Testing for nematode infection in a patient with suspected appendicitis is not routine within the UK and there is no definite test where results can be obtained immediately. Often stool culture results take time to produce, and waiting for these results may put the patient at a high risk of appendiceal perforation.⁵ Despite the high false-positive rate, surgery is often justified due to the morbidity and mortality associated with appendiceal perforation.⁶ Secondly, there is minimal literature suggesting eosinophilia and elevated serum immunoglobulin E levels as features of nematode infections, this may or may not be true,

but these are non-specific markers and our patient had normal levels.⁵

In a paediatric or adolescent patient the differential diagnosis for abdominal pain is wide and varied. Therefore, research into a non-invasive test to detect nematode infection may provide us with a tool to avoid unnecessary surgery and optimise medical management of these patients.

Conflict of interest

The authors disclose no conflicts of interest financial or otherwise.

Funding

There was no funding for this research project.

Consent

Written consent of the patient is available upon request from the editor.

Authors' contributions

Andrew Hotchen involved in planning, writing and completed the manuscript. Kian Chin involved in data collection and writing the manuscript. Mahzar Raja involved in data collection and preparation of the manuscript.

Key learning points

- Nematode infection can mimic acute appendicitis.
- There should be a high index of suspicion for high-risk groups within the UK.
- A viable nematode screening test could prevent unnecessary surgery.

References

1. Carter J, Nelson K, Mizell M. Case study: abdominal pain in an 8-year-old male. *Lab Med* 2007;**38**(June (6)):357–60.
2. Bundy D, Chan M, Medley G, Jamison D, Saviol L. *Intestinal nematode infections: global epidemiology of infectious disease*. World Health Organisation; 2004. p. 243–300.
3. Harhay M, Horton J, Olliaro P. Epidemiology and control of human gastrointestinal parasites in children. *Expert Rev Anti-Infect Ther* 2010;**8**(2):219–34.
4. Pond K. *Water recreation and disease plausibility of associated infections: acute effects, sequelae and mortality*. World Health Organisation; 2005. p. 147–82.
5. Morrison D, Hoglund J. Testing the hypothesis of recent population expansions in nematode parasites of human-associated hosts. *Heredity* 2005;**94**(4):426–34.
6. Harswick C, Uyenishi A, Kordick M. Clinical guidelines, computerised tomography scan and negative appendectomies: a case series. *Am J Emerg Med* 2006;**24**:68–72.

Open Access

This article is published Open Access at scimedirect.com. It is distributed under the [IJSCR Supplemental terms and conditions](#), which permits unrestricted non commercial use, distribution, and reproduction in any medium, provided the original authors and source are credited.