



## Case report

## Left atrial reverse remodeling improves sinus restoration following mitral valve replacement: A case report

Jayarasti Kusumanegara<sup>a,b,\*</sup>, Muhammad Nuralim Mallapasi<sup>a,b</sup>, Peter Kabo<sup>c</sup>, Umar Usman<sup>a</sup>, Deni Syamsuddin<sup>c</sup>, Muhammad Faruk<sup>d</sup>

<sup>a</sup> Division of Thoracic and Cardiovascular Surgery, Department of Surgery, Faculty of Medicine, Hasanuddin University, Makassar, Indonesia

<sup>b</sup> Division of Thoracic and Cardiovascular Surgery, Department of Surgery, Wahidin Sudirohusodo Hospital, Makassar, Indonesia

<sup>c</sup> Department of Cardiology and Vascular Medicine, Faculty of Medicine, Hasanuddin University, Makassar, Indonesia

<sup>d</sup> Department of Surgery, Faculty of Medicine, Hasanuddin University, Makassar, Indonesia

## ARTICLE INFO

## Keywords:

Heart valve  
Rheumatic heart disease  
Mitral valve replacement  
Echocardiography  
Cardiomegaly

## ABSTRACT

**Introduction:** Mitral stenosis is one of the most common abnormalities in rheumatic heart disease (RHD). These patients often experience atrial fibrillation, due to left atrial dilatation, causing a high risk of thromboembolic events; rhythm or heart rate control are thus important treatment strategies. In patients undergoing surgery, sinus rhythm restoration is not fully understood, and not all surgical patients return to sinus rhythm. We report an adult woman with mitral regurgitation who experienced sinus restoration after mitral valve replacement (MVR) surgery.

**Case presentation:** A 44-year-old woman presented with chief complaints of orthopnea and shortness of breath during activity for 2 months. Electrocardiography (ECG) revealed atrial fibrillation with normal ventricular response, and echocardiography showed severe mitral stenosis with Wilkins score of 10 (3-2-3-2), moderate mitral and aortic regurgitation due to RHD, moderate tricuspid regurgitation with probable pulmonary hypertension, normal left ventricular systolic function, ejection fraction of 60.5% (biplane). MVR surgery was performed using a mechanical mitral valve. Postoperative ECG found sinus rhythm and first-degree AV block. Postoperative echocardiography found a decreased left Atrial volume index of 70.8 mL/m<sup>2</sup>, indicating further remodeling of the patient's heart.

**Conclusion:** Sinus restoration sometimes occurs in patients after MVR. The correction procedure causes minimal anatomical changes, particularly the loss of non-conductive and pathological tissue, followed by hemodynamic changes that eventually lead to the left atrial reverse remodeling mechanism.

## 1. Introduction

Rheumatic heart disease (RHD) is a systemic immune process that is a sequela of beta-hemolytic streptococcal infections common in the respiratory tract and most commonly seen in developing countries [1,2]. However, RHD is responsible for 250,000 deaths at a young age worldwide each year, and more than 15 million cases of RHD are currently recorded [2].

Mitral valve stenosis is one of the most common abnormalities in RHD [3]. In general, patients develop heart rhythm disorders, particularly atrial fibrillation, due to left atrial dilatation that occurs as a result

of mitral stenosis; patients are thus at high risk of experiencing thromboembolic events, necessitating treatment strategies for rhythm or heart rate control [4]. In surgical treatment strategies, sinus rhythm restoration is not fully understood, and not all patients who undergo surgery return to sinus rhythm [5].

We report the first case of mitral regurgitation (MR) with sinus restoration after mitral valve replacement (MVR) surgery in Indonesia according to the 2020 Surgical Case Report guidelines [6].

\* Corresponding author at: Division of Thoracic and Cardiovascular Surgery, Department of Surgery, Faculty of Medicine, Hasanuddin University, Jalan Perintis Kemerdekaan KM 11, Makassar 90245, Indonesia.

E-mail addresses: [jayarasti@gmail.com](mailto:jayarasti@gmail.com) (J. Kusumanegara), [nuralim811@gmail.com](mailto:nuralim811@gmail.com) (M.N. Mallapasi), [drpeterkabo@gmail.com](mailto:drpeterkabo@gmail.com) (P. Kabo), [justumarusman@gmail.com](mailto:justumarusman@gmail.com) (U. Usman), [deni.itachi@gmail.com](mailto:deni.itachi@gmail.com) (D. Syamsuddin), [faroex8283@gmail.com](mailto:faroex8283@gmail.com) (M. Faruk).

<https://doi.org/10.1016/j.ijscr.2021.106305>

Received 7 July 2021; Received in revised form 7 August 2021; Accepted 8 August 2021

Available online 11 August 2021

2210-2612/© 2021 The Authors. Published by Elsevier Ltd on behalf of IJS Publishing Group Ltd. This is an open access article under the CC BY-NC-ND license

(<http://creativecommons.org/licenses/by-nc-nd/4.0/>).

## 2. Case presentation

A 44-year-old Buginese woman presented with a chief complaint of progressive dyspnea (New York Heart Association [NYHA] Class II) for 2 months. The patient reported no chest pain, fever, cough, or cold. The patient stated a history of high fever accompanied by joint pain causing difficulty walking when she was 14 years old. The patient had a 2-year history of severe mitral stenosis, and was advised to have surgery, though she refused surgery at the time. The patient had no family history of hypertension and diabetes mellitus. The patient was followed monthly in the outpatient cardiology department and was prescribed furosemide 40 mg, bisoprolol 2.5 mg, and warfarin 2 mg.

Vital signs were within normal limits, except respiratory rate was 22 breaths/min, and body mass index was 22 (normal weight). Cardiac physical examination revealed irregularity of heart sounds S1 and S2, with a fine S1 and hard S2 without splitting; holosystolic murmur (grade 4/6) and mid-diastolic murmur (grade 3/4) at the cardiac apex radiating to the axilla; mid-diastolic murmur (grade 2/4) at the right second intercostal space at the parasternal line; and holosystolic murmur (grade 3/6) at the left lower sternal border. Mild rhonchi of bilateral lung bases was present on auscultation. Other physical checks were within normal limits.

Electrocardiography (ECG) examination revealed atrial fibrillation with normal ventricular response (Fig. 1). Echocardiography (Fig. 2) found severe mitral stenosis with a Wilkins score of 10 (3-2-3-2); moderate MR and moderate aortic regurgitation due to RHD; moderate tricuspid regurgitation with high probability of pulmonary hypertension; normal left ventricle (LV) systolic function; ejection fraction (EF) of 60.5% (biplane method); normal right ventricle (RV) systolic function; Tricuspid annular plane systolic excursion of 1.87 cm; left atrium (LA), right atrium (RA), and RV dilatation; LA volume index (LAVI) of 95.9 mL/m<sup>2</sup>; and global normokinetic LV wall movement. Laboratory examination was within normal limits, and chest X-rays showed cardiomegaly (Fig. 3).

Based on anamnesis, physical examination, and support examination, the patient was diagnosed with congestive heart failure (NYHA Class II), severe mitral stenosis, moderate MR, moderate tricuspid regurgitation, and atrial fibrillation with normal ventricular response. The patient was prescribed oral furosemide (40 mg/24 h), oral bisoprolol (2.5 mg/24 h), and oral warfarin (2 mg/24 h).

Furthermore, our team of thoracic and cardiovascular surgeons performed MVR surgery with a transseptal approach (Fig. 4). During the operation, evaluation of mitral valve restriction and calcification was

first performed before the decision was made to perform MVR with a St. Jude Medical mechanical valve with 25 mm size. Evaluation of the mechanical valve post implantation with transesophageal echocardiography showed good valve function and movement.

The patient was transferred to the postoperative intensive care unit (ICU) with stable hemodynamics, and ECG was performed in the ICU with the following results: sinus rhythm, regular heart rate of 75 beats/min, normal axis, and a PR interval of 0.32 indicating first-degree atrioventricular (AV) block. We delayed the administration of beta-blockers.

During ICU treatment, the patient continued to demonstrate first-degree AV block on ECG. The patient excreted after 24 h and had continuous administration of heparin 10,000 IU/24 h intravenously and warfarin 4 mg/24 h orally with inotropic support slowly titrated down. The patient was transferred to the high care unit with stable hemodynamics without support and continued first-degree AV block on ECG.

Based on postoperative echocardiography, the mechanical mitral valve was well-seated with normal valve opening, no paravalvular leakage, and no thrombus or vegetation; normal LV systolic function, EF of 60.3% (biplane), LA dilatation with LAVI of 70.8 mL/m<sup>2</sup>, and global normokinetics were also seen.

At the 3-month postoperative follow-up, the patient had no complaints related to heart disease. ECG showed regular heart rhythm with first-degree AV block (Fig. 5). Echocardiography indicated the mechanical mitral valve was working well with EF of 62% (biplane), LA dilatation with LAVI of 68.2 mL/m<sup>2</sup>, and global normokinetics.

## 3. Discussion

Rheumatic carditis encompasses a spectrum of conditions, including pericarditis and valvulitis, in clinical or subclinical acute rheumatic fever [1,7]. The transition of rheumatic carditis to RHD involves chronic changes in the valves that develop more than a year after acute rheumatic fever [7]. This progressive valve disease is not connected to a clear history of acute rheumatic fever in 30%–50% of cases [2,7]. A prospective study of 258 pediatric patients with acute rheumatic fever in Brazil observed for 2 to 15 years found that 72% progressed to chronic valvular disease, with 16% developing severe aortic or mitral valve disorders [7,8]. However, acute rheumatic fever is often not diagnosed or recorded correctly, limiting the establishment of a pseudo causal relationship explaining the incidence of valve disease in adults [9]. RHD causes an increasing number of valve replacement procedures, though some of these procedures have limited long-term outcomes, even in

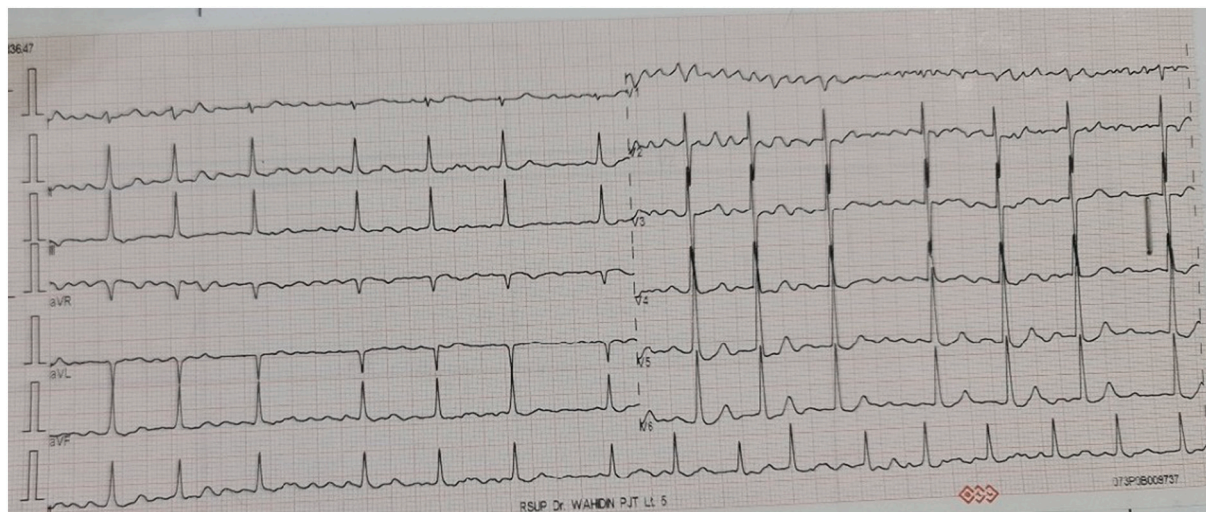


Fig. 1. Electrocardiography indicated atrial fibrillation with normal ventricular response (supraventricular rhythm, heart rate 60–100 beats/min, irregular, normal axis).

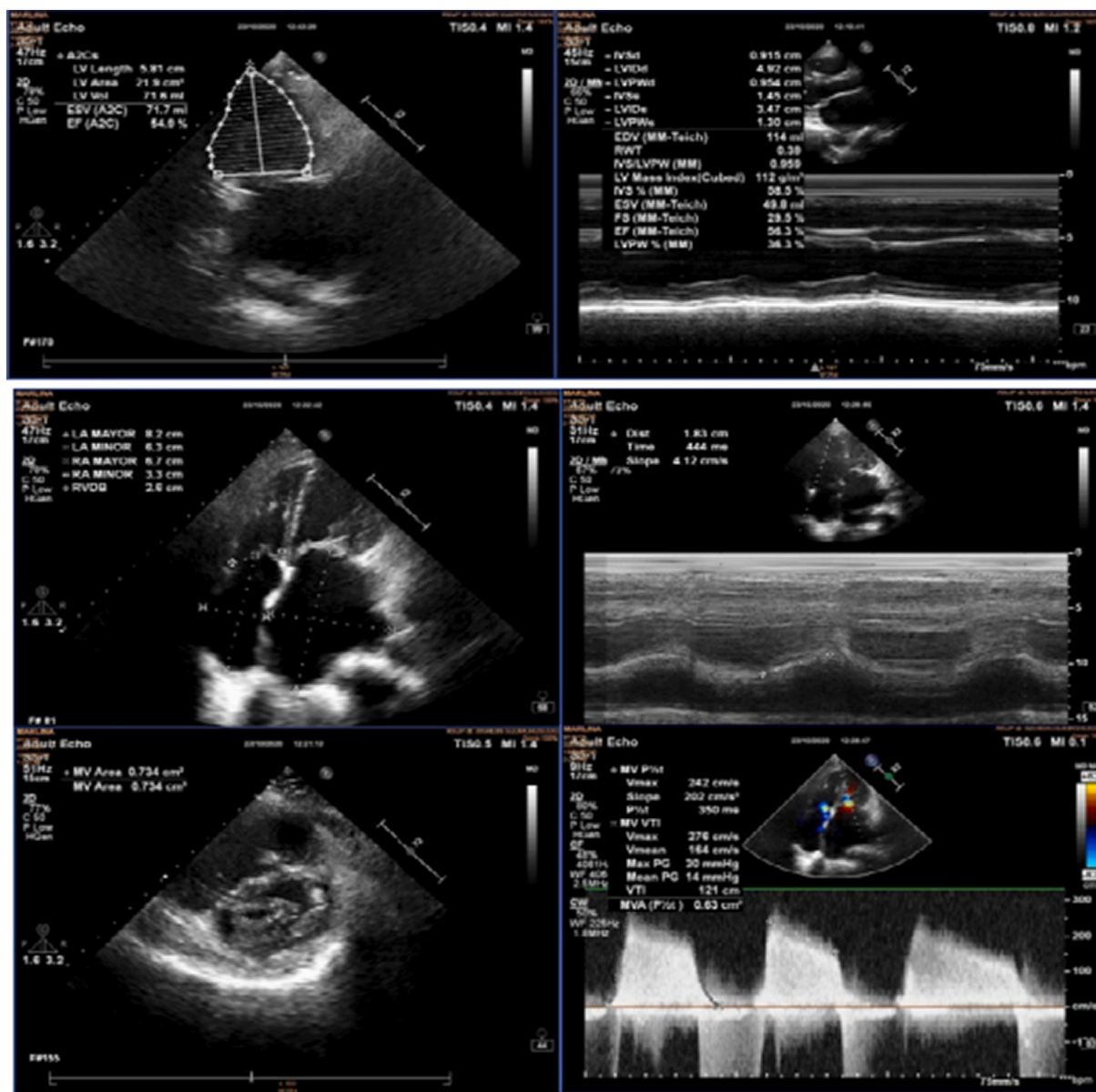


Fig. 2. Echocardiography indicated severe mitral stenosis noted on four-chamber apical view.

cases of mild RHD [10].

Many factors must be considered to determine that a case is RHD. Some risk factors are associated with the incidence of RHD preceded by acute rheumatic fever, including gender, age, history of infections related to streptococcus, and other comorbidities [7]. These risk factors may at least help explain the possibility of valve disorders resulting from a history of rheumatic fever [11].

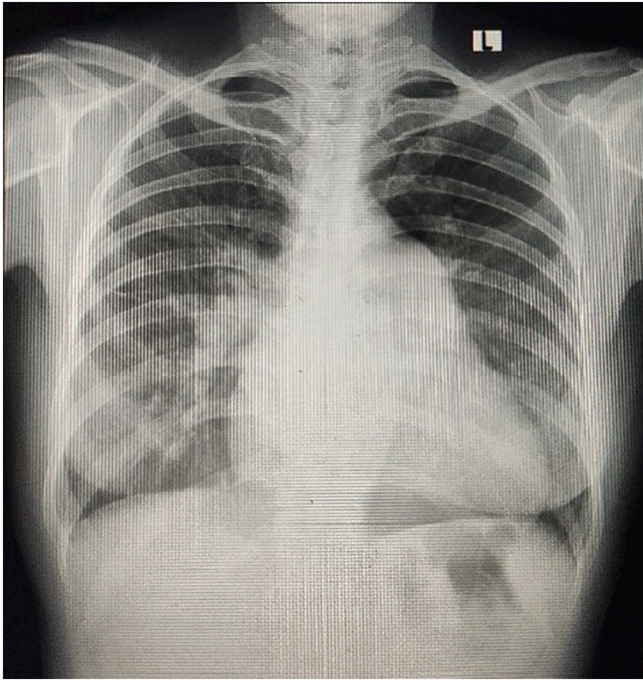
Jones' criteria is one method of diagnosing acute rheumatic fever, requiring the presence of two major symptoms or one major symptom with two minor symptoms [12]. Confirmation of the patient's history of disease in search of possible rheumatic fever was required in this case [13]. Based on anamnesis, the patient was never diagnosed with acute rheumatic fever but had a history of high fever and joint pain causing difficulty walking as a teenager. The history of fever with polyarthralgia and the finding of valve disorders met Jones' criteria, making it likely that the patient had a history of acute rheumatic fever.

Echocardiography is indicated in patients who have a suspected history of acute rheumatic fever or patients with new murmur findings to detect the presence of valve disorders [13]. Echocardiography is also

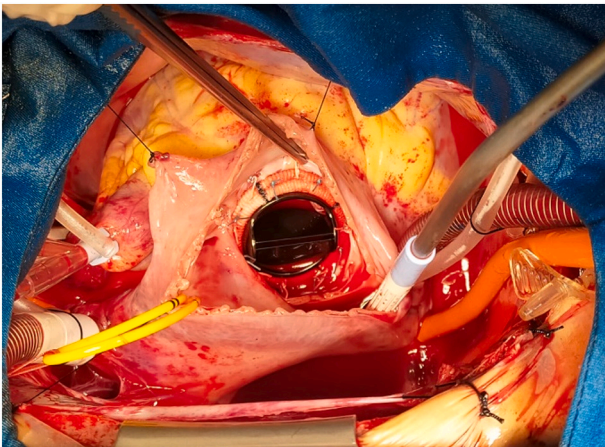
one of the routine procedures used in Jones' criteria to assess for a history of rheumatic fever when carditis is a major symptom. Valve examination in these patients is focused on evaluating morphology, including possible images of vegetation in mitral and aortic valves, and performing Doppler analysis to visualize pathological valve regurgitation [12]. Based on the World Heart Federation echocardiographic criteria [7,12] for RHD, which uses the parameters of valve morphological abnormalities and pathological valvular regurgitation, this patient was diagnosed with RHD involving multivalvular heart disease.

Our patient had heart valve abnormalities encompassing a combination of MR and mitral stenosis due to RHD. Mitral regurgitation increases the mitral valve flow rate. The transvalvular pressure gradient is a function of a square transvalve flow rate, so that in patients with combined mitral valve abnormalities left atrial pressure can be significantly increased leading to serious activity intolerance through increased pneumonic venous and capillary pressures. Signs and symptoms of heart failure can be due to increased preload, pulmonary hypertension, and dilatation of the LV causing changes in the left ventricular compound.





**Fig. 3.** Posterior-anterior chest X-rays demonstrated markedly enlarged cardiac silhouette and a cardiothoracic ratio greater than 0.5.



**Fig. 4.** Mitral valve replacement with mechanical prosthetic valve.

Surgery in this case is indicated by the presence of heart failure symptoms in chronic mitral valve stenosis. The patient was unable to undergo percutaneous mitral balloon valvuloplasty due to the presence of moderate mitral valve regurgitation. The valve anatomy has thickened and become unsuitable for mitral valve repair, resulting in the patient meeting the criteria for mitral valve replacement as defined by the European Society of Cardiology and the European Society of Thoracic Surgeons [14]. No corrections were performed for aortic regurgitation because its degree was moderate.

Sinus restoration usually occurs after surgery. A study involving patients with mitral stenosis and chronic atrial fibrillation undergoing surgery showed sinus restoration lasting more than 3 months in 60% of participants. The primary characteristics of successful patients were younger age (mean 38 years), shorter symptom duration (mean 3 years), and smaller preoperative left atrium size (<4.9 cm) on echocardiography [15].

Left atrial remodeling (LAR) is one of the compensatory mechanisms

in mitral valve abnormalities, which occurs to accommodate the increased volume of the LA without increasing pressure, as dilatation of the LA is a marker of cardiovascular events such as atrial fibrillation, stroke, and death in patients with heart disease. Left atrial reverse remodeling (LARR) can occur postoperatively after heart valve replacement, where the occurrence of LARR is a component of the mechanism of restoration of sinus rhythm and improvement of diastolic conditions [16].

Sinus restoration following LARR after mitral valve replacement might be associated with LARR due to two possible mechanisms, structural remodeling (reduced LA size) and LA electrical changes. In a previous study, LA dilatation was directly correlated with the duration of AF [17]. Hence, reducing LA size is associated with the reduction of AF duration or occurrence or even sinus restoration.

In terms of histological changes, the possibility of myopathy in the atrium might cause electrical remodeling of the atria, including depressed excitability, increased refractoriness, and slowed or blocked conduction. When congestive heart failure does exist, it is also associated with abnormalities of cell electrophysiology such as cellular uncoupling and anisotropy [18]. The surgical procedure may remove this non-conductive tissue; it is assumed that persistent sinus restoration depends on how extensive the removal was. In terms of electrical changes, increased LA size causes a prolongation of the total depolarization time of the LA. A study shows an association between LA volume, P wave dispersion, and P terminal force on surface ECG in idiopathic dilated cardiomyopathy. Another study shows that P wave dispersion is associated with atrial fibrillation. Furthermore, a prolonged P terminal force is correlated with paroxysmal atrial fibrillation [19]. Hence, LARR might reduce these abnormal electrical parameters by reducing LA size and, eventually, promoting sinus restoration.

Acute postoperative hemodynamic changes and LARR lead to increased cardiac output, reduced risk of embolization, lower heart rate at rest and during activity, reduced palpitations, and subjective improvement in most patients, and these conditions further encourage the restoration of sinus rhythm and improved AV synchronicity [17]. With hemodynamic improvement due to LARR, sinus restoration can be permanent and the incidence of new chronic atrial fibrillation is reduced. A study showed that in patients with LARR, the incidence of chronic atrial fibrillation was 51% compared to 72% in patients who did not experience LARR [18].

There are several explanations for why sinus restoration is often not permanent and atrial fibrillation reemerges. The key component is differences in the atrial remodeling process. Older age becomes a very important factor due to impaired cell regeneration (e.g., changes in fibroblast and cardiomyocyte function) [18]. In addition, the longer the patient experiences symptoms of anatomical disorders, more extensive pathological tissue changes occur, including cardiomyocyte lengthening, hypertrophy or loss of myocyte tissue, collagen accumulation, and ventricular wall depletion [19].

#### 4. Conclusion

One of the most common abnormalities in RHD is mitral valve stenosis. These patients may develop abnormal heart rhythms, most notably atrial fibrillation. Treatment of mitral valve stenosis with mitral valve replacement may result in sinus restoration, as demonstrated in our patient, although this is a very rare occurrence. One of the factors contributing to sinus restoration is the emergence of the LARR mechanism. The two most important LARR mechanisms are structural remodeling (reduced LA size) and electrical changes in the LA. Loss of LA volume is associated with a decrease in the duration or occurrence of AF, as well as with sinus restoration. The correction procedure results in minimal anatomical changes, most notably the excision of non-conductive and pathological tissue, which expedites sinus restoration. The LARR mechanism, particularly with sinus restoration, has been shown to improve hemodynamics in patients.

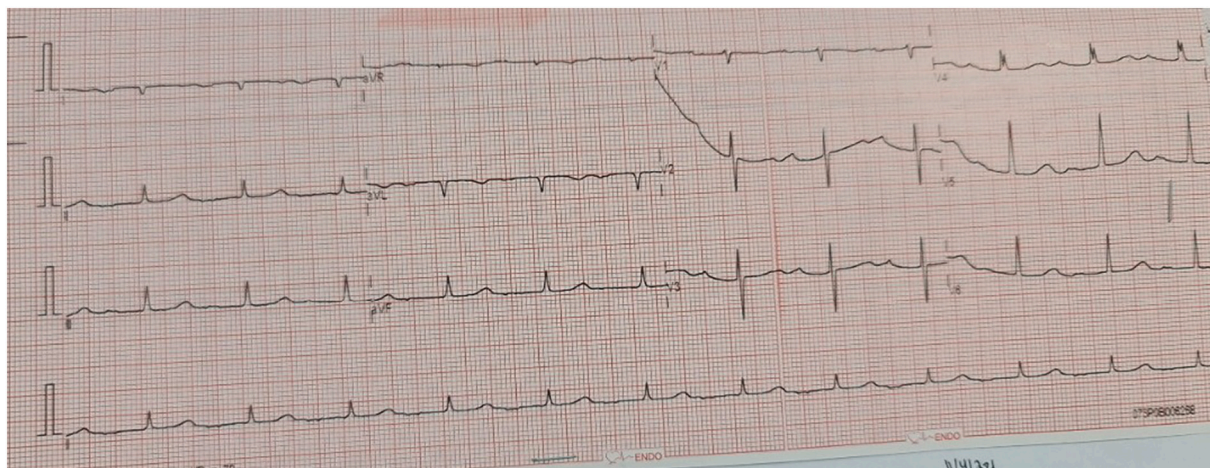


Fig. 5. ECG evaluation performed 3 months postoperatively found first-degree AV block.

### Provenance and peer review

Not commissioned, externally peer-reviewed.

### Please state any sources of funding for your research

No funding or sponsorship

### Ethical approval

The study is exempt from ethical approval in our institution.

### Consent

Written informed consent was obtained from the patient for publication of this case report and accompanying images. A copy of the written consent is available for review by the Editor-in-Chief of this journal on request.

### CRedit authorship contribution statement

Jayarasti Kusumanegara, Muhammad Nuralim Mallapasi, Umar Usman, and Peter Kabo: study concept and surgical therapy for this patient. Jayarasti Kusumanegara, Deni Syamsuddin, and Muhammad Faruk: Data collection and Writing-Original draft preparation. Muhammad Nuralim Mallapasi and Peter Kabo: senior author and the manuscript reviewer. Jayarasti Kusumanegara and Muhammad Faruk: Editing and Writing. All authors read and approved the final manuscript.

### Registration of research studies

Not applicable – single case report

### Guarantor

Jayarasti Kusumanegara

### Declaration of competing interest

Nothing to declare.

### Acknowledgment

We would like to express our appreciation to Manwan Basra, Ahmad, Amran Nurfataillah, Nurkamar, and Ernawati Abbas of the operating theater staff at Wahidin Sudirohusodo Hospital, Makassar, Indonesia.

### References

- [1] J.R. Carapetis, Rheumatic heart disease in developing countries, *N. Engl. J. Med.* 357 (2007) 439–441, <https://doi.org/10.1056/NEJMp078039>.
- [2] M.D. Seckeler, T. Hoke, The worldwide epidemiology of acute rheumatic fever and rheumatic heart disease, *Clin. Epidemiol.* (2011) 67, <https://doi.org/10.2147/CLEP.S12977>.
- [3] S. Nulu, G. Bukhman, G.F. Kwan, Rheumatic heart disease, *Cardiol. Clin.* 35 (2017) 165–180, <https://doi.org/10.1016/j.ccl.2016.08.006>.
- [4] T. Kemaloglu öz, New perspectives by imaging modalities for an old illness: rheumatic mitral stenosis, *Anatol. J. Cardiol.* (2020), <https://doi.org/10.14744/AnatolJCardiol.2020.01575>.
- [5] A. Yalcinkaya, A. Diken, E. Aksoy, G. Lafci, O. Cicek, E. Kadirogullari, U. Ulsar, K. Cagli, Effect of left atrial reduction on restoration and maintenance of sinus rhythm in patients undergoing mitral valve replacement: a pilot study, *Thorac. Cardiovasc. Surg.* 64 (2015) 441–446, <https://doi.org/10.1055/s-0035-1558993>.
- [6] R.A. Agha, T. Franchi, C. Sohrabi, G. Mathew, A. Kerwan, A. Thoma, A.J. Beamish, A. Noureldin, A. Rao, B. Vasudevan, B. Challacombe, B. Perakath, B. Kirshstein, B. Ekser, C.S. Pramesh, D.M. Laskin, D. Machado-Aranda, D. Miguel, D. Pagano, F. H. Millham, G. Roy, H. Kadioglu, L.J. Nixon, I. Mukhejee, J.A. McCaul, J. Chi-Yong Ngu, J. Albrecht, J.G. Rivas, K. Raveendran, L. Derbyshire, M.H. Ather, M. A. Thorat, M. Valmasoni, M. Bashashati, M. Chalkoo, N.Z. Teo, N. Reason, O. J. Muensterer, P.J. Bradley, P. Goel, P.S. Pai, R.Y. Affi, R.D. Rosin, R. Coppola, R. Klappenbach, R. Wynn, R.L. De Wilde, S. Surani, S. Giordano, S. Massarut, S. G. Raja, S. Basu, S.A. Enam, T.G. Manning, T. Cross, V.K. Karanth, V. Kasivisvanathan, Z. Mei, S.C.A.R.E. The, Guideline: updating consensus surgical CAse REport (SCARE) guidelines, *Int. J. Surg.* 84 (2020) (2020) 226–230, <https://doi.org/10.1016/j.ijsu.2020.10.034>.
- [7] R.K. Kumar, M.J. Antunes, A. Beaton, M. Mirabel, V.T. Nkomo, E. Okello, P. R. Regmi, B. Reményi, K. Sliwa-Hähnle, L.J. Zühlke, C. Sable, Contemporary diagnosis and Management of Rheumatic Heart Disease: implications for closing the gap: a scientific statement from the American Heart Association, *Circulation* 142 (2020), <https://doi.org/10.1161/CIR.0000000000000921>.
- [8] Z.M.A. Meira, E.M.A. Goulart, E.A. Colosimo, C.C.C. Mota, Long term follow up of rheumatic fever and predictors of severe rheumatic valvar disease in Brazilian children and adolescents, *Heart* 91 (2005) 1019–1022, <https://doi.org/10.1136/hrt.2004.042762>.
- [9] L. Zühlke, M.E. Engel, G. Karthikeyan, S. Rangarajan, P. Mackie, B. Cupido, K. Mauff, S. Islam, A. Joachim, R. Daniels, V. Francis, S. Ogendo, B. Gitura, C. Mondo, E. Okello, P. Lwabi, M.M. Al-Kebsi, C. Hugo-Hamman, S.S. Sheta, A. Haileamlak, W. Daniel, D.Y. Goshu, S.G. Abdissa, A.G. Desta, B.A. Shasho, D. M. Begna, A. ElSayed, A.S. Ibrahim, J. Musuku, F. Bode-Thomas, B.N. Okeahialam, O. Ige, C. Sutton, R. Misra, A. Abul Fadl, N. Kennedy, A. Damasceno, M. Sani, O. S. Ogah, T. Olunuga, H.H.M. Elhassan, A.O. Mocumbi, A.M. Adeoye, P. Mntla, D. Ojji, J. Mucumbitsi, K. Teo, S. Yusuf, B.M. Mayosi, Characteristics, complications, and gaps in evidence-based interventions in rheumatic heart disease: the global rheumatic heart disease registry (the REMEDY study), *Eur. Heart J.* 36 (2015) 1115–1122a, <https://doi.org/10.1093/eurheartj/ehu449>.
- [10] J. Cannon, K. Roberts, C. Milne, J.R. Carapetis, Rheumatic heart disease severity, progression and outcomes: a multi-state model, *J. Am. Heart Assoc.* 6 (2017), e003498, <https://doi.org/10.1161/JAHA.116.003498>.
- [11] E.F. Bland, T. Duckett Jones, Rheumatic fever and rheumatic heart disease: a twenty year report on 1000 patients followed since childhood, *Circulation* 4 (1951) 836–843, <https://doi.org/10.1161/01.cir.4.6.836>.
- [12] M.H. Gewitz, R.S. Baltimore, L.Y. Tani, C.A. Sable, S.T. Shulman, J. Carapetis, B. Reményi, K.A. Taubert, A.F. Bolger, L. Beerman, B.M. Mayosi, A. Beaton, N. G. Pandian, E.L. Kaplan, Revision of the Jones criteria for the diagnosis of acute rheumatic fever in the era of doppler echocardiography, *Circulation* 131 (2015) 1806–1818, <https://doi.org/10.1161/CIR.0000000000000205>.

- [13] J. Alqanatish, A. Alfadhel, A. Albelali, D. Alqahtani, Acute rheumatic fever diagnosis and management: review of the global implications of the new revised diagnostic criteria with a focus on Saudi Arabia, *J. Saudi Heart Assoc.* 31 (2019) 273–281, <https://doi.org/10.1016/j.jsha.2019.07.002>.
- [14] H. Baumgartner, V. Falk, J.J. Bax, M.De Bonis, C. Hamm, P.J. Holm, B. Iung, P. Lancellotti, E. Lansac, D.Rodríguez Muñoz, R. Rosenhek, J. Sjögren, P. Tornos Mas, A. Vahanian, T. Walther, O. Wendler, S. Windecker, J.L. Zamorano, 2017 ESC/EACTS guidelines for the management of valvular heart disease, *Eur. Heart J.* 38 (2017) 2739–2791, <https://doi.org/10.1093/eurheartj/ehx391>.
- [15] M.Y. Flugelman, Y. Hasin, N. Katznelson, M. Kriwisky, A. Shefer, M.S. Gotsman, Restoration and maintenance of sinus rhythm after mitral valve surgery for mitral stenosis, *Am. J. Cardiol.* 54 (1984) 617–619, [https://doi.org/10.1016/0002-9149\(84\)90260-1](https://doi.org/10.1016/0002-9149(84)90260-1).
- [16] L.R. Machado, Z.M. Meneghelo, D.C.S. Le Bihan, R.B.M. Barretto, A.C. Carvalho, V. A. Moises, Preoperative left ventricular ejection fraction and left atrium reverse remodeling after mitral regurgitation surgery, *Cardiovasc. Ultrasound* 12 (2014) 45, <https://doi.org/10.1186/1476-7120-12-45>.
- [17] H. Semer, H. Hultgren, R. Kleiger, B. Braniff, Cardioversion following prosthetic mitral valve replacement, *Circulation* 35 (1967) 523–529, <https://doi.org/10.1161/01.cir.35.3.523>.
- [18] S. Hyllén, S. Nozohoor, C. Meurling, P. Wierup, J. Sjögren, Left atrial reverse remodeling following valve surgery for chronic degenerative mitral regurgitation in patients with preoperative sinus rhythm: effects on long-term outcome, *J. Card. Surg.* 28 (2013) 619–626, <https://doi.org/10.1111/jocs.12215>.
- [19] J.N. Cohn, R. Ferrari, N. Sharpe, Cardiac remodeling—concepts and clinical implications: a consensus paper from an international forum on cardiac remodeling. Behalf of an International Forum on Cardiac Remodeling, *J. Am. Coll. Cardiol.* 35 (2000) 569–582, [https://doi.org/10.1016/s0735-1097\(99\)00630-0](https://doi.org/10.1016/s0735-1097(99)00630-0).