

Urological Oncology

# Usefulness of the Ice-Cream Cone Pattern in Computed Tomography for Prediction of Angiomyolipoma in Patients With a Small Renal Mass

Kwang Ho Kim, Bu Hyeon Yun, Seung Il Jung, In Sang Hwang, Eu Chang Hwang, Taek Won Kang, Dong Deuk Kwon, Kwangsung Park, Jin Woong Kim<sup>1</sup>

Departments of Urology and <sup>1</sup>Diagnostic Radiology, Chonnam National University Medical School, Gwangju, Korea

**Purpose:** A morphologic contour method for assessing an exophytic renal mass as benign versus malignant on the basis of the shape of the interface with the renal parenchyma was recently developed. We investigated the usefulness of this morphologic contour method for predicting angiomyolipoma (AML) in patients who underwent partial nephrectomy for small renal masses (SRMs).

**Materials and Methods:** From January 2004 to March 2013, among 197 patients who underwent partial nephrectomy for suspicious renal cell carcinoma (RCC), the medical records of 153 patients with tumors (AML or RCC)  $\leq 3$  cm in diameter were retrospectively reviewed. Patient characteristics including age, gender, type of surgery, size and location of tumor, pathologic results, and specific findings of the imaging study ("ice-cream cone" shape) were compared between the AML and RCC groups.

**Results:** AML was diagnosed in 18 patients and RCC was diagnosed in 135 patients. Gender ( $p=0.001$ ), tumor size ( $p=0.032$ ), and presence of the ice-cream cone shape ( $p=0.001$ ) showed statistically significant differences between the AML group and the RCC group. In the multivariate logistic regression analysis, female gender (odds ratio [OR], 5.20; 95% confidence interval [CI], 1.45 to 18.57;  $p=0.011$ ), tumor size (OR, 0.34; 95% CI, 0.12 to 0.92;  $p=0.034$ ), and presence of the ice-cream cone shape (OR, 18.12; 95% CI, 4.97 to 66.06;  $p=0.001$ ) were predictors of AML.

**Conclusions:** This study confirmed a high incidence of AML in females. Also, the ice-cream cone shape and small tumor size were significant predictors of AML in SRMs. These finding could be beneficial for counseling patients with SRMs.

**Keywords:** Angiomyolipoma; Diagnostic imaging; Kidney; Nephrectomy; Renal cell carcinoma

This is an Open Access article distributed under the terms of the Creative Commons Attribution Non-Commercial License (<http://creativecommons.org/licenses/by-nc/3.0>) which permits unrestricted non-commercial use, distribution, and reproduction in any medium, provided the original work is properly cited.

**Article History:**

received 2 May, 2013  
accepted 11 June, 2013

**Corresponding Author:**

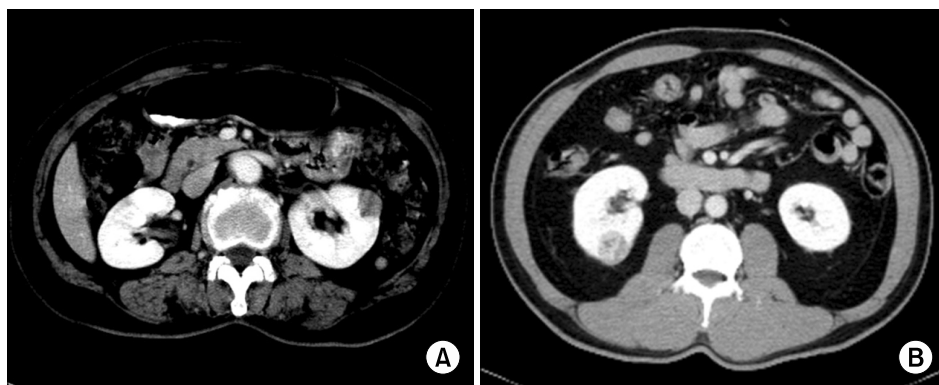
Seung Il Jung  
Department of Urology,  
Chonnam National University  
Hwasun Hospital, Chonnam  
National University Medical  
School, 322 Seoyang-ro, Hwasun  
519-763, Korea  
TEL: +82-61-379-8160  
FAX: +82-61-379-7750  
E-mail: drjsi@yahoo.co.kr

## INTRODUCTION

Small renal masses (SRMs) are defined as solid renal tumors that are enhanced on computed tomographic (CT) scan and magnetic resonance imaging and that are suspected as renal cell carcinomas (RCCs). With the introduction of sonographic and CT examinations, the number of SRMs detected has been greater than previously reported [1,2]. The number of renal masses  $< 3$  cm in diame-

ter detected in a period of 5 years during the 1980s was five times greater than that in a similar period during the 1970s owing to the increased number of abdominal imaging studies carried out [1]. Tumors  $< 3$  cm in diameter may be more likely to be benign, whereas the aggressive potential of RCC increases dramatically beyond this size [3,4].

Over 70% of renal masses are diagnosed incidentally and have a small volume with the standard of treatment being partial or radical nephrectomy [5,6]. However, more re-



**FIG. 1.** Transverse abdominal computed tomography images showing two types of renal masses. A peripheral renal mass makes (A) an ice-cream cone pattern (angiomyolipoma) in the left kidney and (B) a round interface with the renal parenchyma (renal cell carcinoma) in the right kidney.

cently, nephron-sparing surgery has become the gold standard for most SRMs. While refined detection technologies have led to the treatment of smaller and earlier-stage malignancies, the percentage of benign lesions discovered has also increased. Although most masses prove to be RCC on final histology, a high proportion of benign disease has also been identified (up to 46% for SRMs) [7]. Because of this, urologists need more preoperative predictors of pathology to aid in decision-making. Several studies have linked the likelihood of benign pathology with preoperative factors, such as age, sex, smoking history, and tumor size [7-11]. However, making a definitive diagnosis in SRM remains difficult. Angiomyolipoma (AML) is typically a solid benign lesion that exhibits fat density on CT scans [12]. However, some renal lesions may contain a very small amount of fat ("minimal fat AML") with microscopic fat and without demonstrable macroscopic fat; these lesions cannot be differentiated from RCCs.

Recently, Verma et al. [13] noted that some exophytic renal masses have a uniform rounded interface with the renal parenchyma, whereas others have a tapering, almost pyramidal, interface, with a definable apex within the parenchyma and an exophytic bulging of the mass beyond the renal capsule. Those authors reported a higher proportion of benign disease for renal masses shaped as an angular interface in the periphery of the kidney compared with renal cancer [13]. We term this renal mass shape with an angular interface in the periphery of the kidney an "ice-cream cone" shape. In the present study, we evaluated the ice-cream cone shape as a predictor of AML in patients who underwent partial nephrectomy of renal masses presumed to be RCC.

## MATERIALS AND METHODS

### 1. Patients

The study was carried out in accordance with the Declaration of Helsinki. Data from patients who underwent partial nephrectomy for a renal mass between January 2004 and March 2013 were reviewed retrospectively. Patients were eligible for inclusion in the study if they met the following criteria: 1) histologically diagnosed AML or malignant renal tumor after partial nephrectomy, 2) exophytic or pe-

ripheral renal mass, and 3) tumor  $\leq 3$  cm in diameter. Patients for whom pathologic data were missing, who had multiple renal masses or fat density in renal imaging, or who had tumors larger than 3 cm were excluded from the study. Also, patients with a pathologic diagnosis, such as simple cyst, Wilms tumor, oncocytoma, metastatic tumor, and adenoma, were excluded. By use of these criteria, 153 patients were enrolled in the present study.

All patients had a solitary renal mass presumed to be RCC on preoperative imaging and had no demonstrable fat on imaging. Treatments included laparoscopic and open partial nephrectomies. Patient charts and imaging data were reviewed and clinicopathological data were collected. Patient characteristics including age, gender, size and location of tumor, pathologic results, and specific findings of the CT imaging study (ice-cream cone shape or angular interface) were compared between the AML group and the RCC group (Fig. 1). All patients were scanned in the supine position by use of CT (Lightspeed VCT, GE Healthcare, Milwaukee, WI, USA). CT images, including axial and coronal images, were reviewed by a radiologist and a urologist who were aware of the study design but were blinded to the clinical information.

We examined the sensitivity, specificity, positive predictive value (PPV), and negative predictive value (NPV) of the ice-cream cone shape for detection of AML by use of the results obtained by the final pathology.

### 2. Histopathological analysis

For RCC and AML, histopathologic diagnosis after partial nephrectomy was the reference standard. Histologic subtypes of RCC were classified according to the 2004 World Health Organization classification.

From postoperative histology reports, renal masses were broadly categorized as malignant (RCC) or benign. Malignant lesions included clear cell, papillary, and chromophobe tumors. Benign lesions included oncocytomas, AMLs, and renal cysts.

### 3. Statistical analyses

Statistical analyses of data used SPSS ver. 17.0 (SPSS Inc., Chicago, IL, USA). The distribution of clinicopathological covariates between the two patient groups was evaluated

**TABLE 1.** Baseline characteristics of the patients

Characteristic	AML (n=18)	RCC (n=135)	Total	p-value
Age (y)	54.28±12.2	54.53±12.5	54.50±12.4	0.935 <sup>a</sup>
Gender				0.001 <sup>b</sup>
Male	5 (27.8)	93 (68.9)	98 (64.1)	
Female	13 (72.2)	42 (31.1)	55 (35.9)	
Laterality				0.625 <sup>b</sup>
Left kidney	10 (55.6)	66 (48.9)	76 (49.7)	
Right kidney	8 (44.4)	69 (51.1)	77 (50.3)	
Tumor location				0.488 <sup>c</sup>
Upper	4 (22.2)	26 (19.3)	30 (19.6)	
Mid	5 (27.8)	57 (42.2)	62 (40.5)	
Lower	9 (50.0)	52 (38.5)	61 (39.9)	
Tumor size (cm)				0.032 <sup>c</sup>
0.1-1.0	4 (22.2)	8 (5.9)	12 (7.8)	
1.1-2.0	10 (55.6)	67 (49.6)	77 (50.3)	
2.1-3.0	4 (22.2)	60 (44.4)	64 (41.8)	
Ice-cream cone shape <sup>d</sup>				0.001 <sup>c</sup>
Present	14 (77.8)	21 (15.6)	35 (22.9)	
Absent	4 (22.2)	114 (84.4)	118 (77.1)	
Surgical methods				
Open PN	1 (5.6)	13 (9.6)	14 (9.2)	
Laparoscopic PN	17 (94.4)	122 (90.4)	139 (90.8)	

Values are presented as mean±standard deviation or number (%).

AML, angiomyolipoma; RCC, renal cell carcinoma; PN, partial nephrectomy.

<sup>a</sup>:Student t-test. <sup>b</sup>:Chi-square test. <sup>c</sup>:Fisher exact test. <sup>d</sup>:Nonround shape of tumors by parenchymal compression (intrarenal portion: compressed by parenchyma vs. extrarenal portion: not compressed, grows freely).

by independent-sample t-test, chi-squared test, and Fisher exact test for categorical variables. Univariate and multivariate logistic regression analyses were performed to determine the correlation between clinicoradiologic findings and AML. A p-value < 0.05 was considered statistically significant.

## RESULTS

### 1. Patient characteristics

The mean age of the entire cohort was 54.50±12.4 years and 98 patients (64.1%) were male. Table 1 shows the patient characteristics by postoperative histology reports. Of 153 exophytic renal masses, 18 (11.7%) were AML and 135 (88.3%) were RCCs; 5 were cystic RCC, 111 were clear cell RCC, 15 were papillary RCC, and 4 were chromophobe RCC. There was no demonstrable fat on imaging in the AML cases.

Gender (p=0.001), tumor size (p=0.032), and presence of the ice-cream cone shape (p=0.001) showed statistically significant differences between the AML group and the RCC group. The sensitivity, specificity, PPV, and NPV of the ice-cream cone shape for AML were 77.7%, 84.4%, 40.0%, and 96.6%, respectively. Mean age (p=0.935), laterality (p=0.625), and location (p=0.488) of the tumor were not significantly different.

### 2. Comparison of radiologic variables of patients in the AML and RCC groups

The ice-cream cone shape was identified in 77.8% of AMLs and 15.6% of RCCs (p=0.001) (Table 1). The mean diameters of the exophytic AML and RCC tumors were 1.61±0.65 cm and 2.01±0.59 cm, respectively (independent-sample t-test; p=0.010). The ice-cream cone shape was identified in 21 cases of RCC. The subtypes of RCC in these 21 cases were 17 (81.0%) clear cell RCC, 3 (14.3%) papillary RCC, and 1 cystic RCC (4.8%).

### 3. Pathological variables of RCC patients

Pathologic subtype analysis by the size criteria showed no significant differences. Fuhrman nuclear grade analysis of the RCCs by the size criteria also showed no significant differences (Table 2).

### 4. Subgroup analysis of SRM patients with ice-cream cone shape

In the subgroup analysis of the 35 patients with tumors showing the ice-cream cone shape, there was no significance difference (p=0.260, Fisher exact test) by the size criteria between 14 patients with AML (0.1-1.0 cm, 2 patients [14.3%]; 1.1-2.0 cm, 8 patients [57.1%]; 2.1-3.0 cm, 4 patients [28.6%]) and 21 patients with RCC (0.1-1.0 cm, 1 patient [4.8%]; 1.1-2.0 cm: 8 patients [38.1%]; 2.1-3.0 cm: 12 patients [57.1%]).

**TABLE 2.** Pathologic subtypes and Fuhrman nuclear grade of RCCs according to size

	Subtypes, n (%)				p-value	Grade, n (%)				p-value
	Clear cell	Papillary	Chromophobe	Others <sup>a</sup>		I	II	III	IV	
Tumor size (cm)					0.847 <sup>b</sup>					0.154 <sup>b</sup>
0.1-1.0	8 (7.2)	0 (0.0)	0 (0)	0 (0)		3 (23.1)	5 (5.0)	0 (0)	0 (0)	
1.1-2.0	52 (46.8)	10 (66.7)	2 (50.0)	3 (60.0)		6 (46.2)	50 (49.5)	11 (52.4)	0 (0)	
2.1-3.0	51 (45.9)	5 (33.3)	2 (50.0)	2 (40.0)		4 (30.8)	46 (45.5)	10 (47.6)	0 (0)	
Total	111 (100)	15 (100)	4 (100)	5 (100)		13 (100)	101 (100)	21 (100)	0 (0)	

RCC, renal cell carcinoma.

<sup>a</sup>:Cystic RCC. <sup>b</sup>:Fisher exact test.

**TABLE 3.** Logistic regression analysis for the predictors of AML vs. RCC

	OR (95% CI)	p-value
Gender (female vs. male)	5.20 (1.45-18.57)	0.011
Tumor size <sup>a</sup>	0.34 (0.12-0.92)	0.034
Ice-cream cone shape <sup>b</sup> (present vs. absent)	18.12 (4.97-66.06)	0.001

AML, angiomyolipoma; RCC, renal cell carcinoma; OR, odds ratio; CI, confidence interval.

<sup>a</sup>:Continuous variable. <sup>b</sup>:Nonround shape of tumors by parenchymal compression (intrarenal portion: compressed by parenchyma vs. extrarenal portion: not compressed, grows freely).

**5. Correlation between clinicoradiologic findings and AML**

For the parameters showing differences between the groups in the univariate analysis (gender, tumor size, and specific radiologic finding), multivariate logistic regression analysis was done. Female gender (odds ratio [OR], 5.20; 95% confidence interval [CI], 1.45 to 18.57; p=0.011), tumor size (OR, 0.34; 95% CI, 0.12 to 0.92; p=0.034), and presence of the ice-cream cone shape (OR, 18.12; 95% CI, 4.97 to 66.06; p=0.001) were predictors of AML rather than RCC (Table 3).

**DISCUSSION**

The morphologic contour method for assessing exophytic renal masses as benign versus malignant on the basis of the shape of the interface with the renal parenchyma is a recently developed concept [13]. Although the angular interface (which we referred to here as the ice-cream cone shape) could be speculated to be caused by differences in growth pattern between benign and malignant masses, which might influence the shape of their interfaces with the renal parenchyma, there is no convincing pathophysiologic explanation for the angular interface. We supposed that the ice-cream cone shape could be caused by characteristics of AML, such as a softer renal parenchyma. If this parameter could distinguish AML from RCC, it would be useful for reducing potentially unnecessary surgical interventions. The high incidence of the ice-cream cone shape caused by AML would be beneficial for distinguishing AML from RCC

among SRMs, particularly in SRMs without a definitive fat component.

Clinical clues can help to distinguish AML from RCC. Sporadic AML, which accounts for about 80% of tumors, is typically small and asymptomatic and is an incidental finding in middle-aged women. This study also confirmed a high incidence of AML in females. The tumor is usually well-defined, and calcification or necrosis within the tumor is rare [14]. Although the fat content of an AML is often evident on thin-section unenhanced CT, about 5% of AMLs have insufficient fat to allow an unequivocal diagnosis [15,16].

When encountering an incidental SRM, AMLs should be excluded. Most AMLs can be diagnosed by identifying regions of fat within a noncalcified renal mass during unenhanced CT [17]. Chemical shift magnetic resonance imaging may also be used to diagnose an AML [18]. However, the clear cell subtype of RCC may lose signal intensity on out-of-phase images because the cells of this tumor, like fat cells, may also contain intracellular lipid [19].

Traditionally, tumor size has been highlighted as the only reliable preoperative factor for prediction of malignant histology. For tumors ≤ 4 cm in size, the percentage of benign masses has been reported to be 19.8% to 23% [20-22]. The smaller the mass, the greater the chance that it is benign. In a report on 2,770 surgically excised solid renal masses stratified according to size, 46% of masses < 1 cm in diameter were benign, as were 22% of those that were 1 to 2.9 cm and 20% of those that were 3 to 3.9 cm [7]. Consistent with the latter study, our data highlighted tumor size as a reliable preoperative factor for prediction of malignant histology in univariate and multivariate logistic regression analysis.

Better preoperative diagnostic methods for SRMs are needed to reduce the number of major surgeries performed unnecessarily. One option is to use preoperative needle core biopsy for selected lesions, which has been shown to be an accurate method for pathological diagnosis [23,24]. It appears to be safe, and new techniques provide more accurate biopsy material [25,26]. Another option is initial active surveillance as part of the management of incidentally detected SRMs followed by treatment only for those that show progression [27]. However, the cost and burden of serial imaging is significant and others have expressed con-

cern that local progression might require radical nephrectomy rather than nephron-sparing treatment. On the basis of the findings from the present study in which peripheral renal lesions with an ice-cream cone shape were associated with a significant probability of having AML pathology, we suggest that these data could be helpful in patient counseling concerning active surveillance or preoperative biopsy.

Several possible limitations of this study warrant discussion. The choice of 3 cm as a cutoff size may seem unusual. This was chosen because, from our experience, tumors smaller than 3 cm are difficult to classify by AML owing to the absence of a gross fat component and because tumors less than 3 cm in size may be more likely to be benign [3]. Thus, there is the question of whether a similar pattern would be found in larger masses. According to a previous report [13], the angular interface is also a useful predictor of benignity in exophytic renal masses larger than 3 cm in diameter. Another potential limitation of this study is that selection bias might result from the selection of all consecutive patients who underwent only partial nephrectomy for SRMs during the study period, but might be diminished by a study based on pathologic reports after partial nephrectomy.

## CONCLUSIONS

Parameters that can distinguish AML from RCC would be useful for reducing unnecessary surgical interventions. This study confirmed a high incidence of AML in females. Also, tumor size and the ice-cream cone shape in CT imaging are beneficial for distinguishing AML from RCC among SRMs. Thus, a simple assessment of the ice-cream cone shape can be used as an additional parameter in patient counseling.

## CONFLICTS OF INTEREST

The authors have nothing to disclose.

## REFERENCES

- Bosniak MA. The small (less than or equal to 3.0 cm) renal parenchymal tumor: detection, diagnosis, and controversies. *Radiology* 1991;179:307-17.
- Chow WH, Devesa SS. Contemporary epidemiology of renal cell cancer. *Cancer J* 2008;14:288-301.
- Pahernik S, Ziegler S, Roos F, Melchior SW, Thuroff JW. Small renal tumors: correlation of clinical and pathological features with tumor size. *J Urol* 2007;178:414-7.
- Remzi M, Ozsoy M, Klingler HC, Susani M, Waldert M, Seitz C, et al. Are small renal tumors harmless? Analysis of histopathological features according to tumors 4 cm or less in diameter. *J Urol* 2006;176:896-9.
- Schlomer B, Figenschau RS, Yan Y, Venkatesh R, Bhayani SB. Pathological features of renal neoplasms classified by size and symptomatology. *J Urol* 2006;176(4 Pt 1):1317-20.
- Touijer K, Jacqmin D, Kavoussi LR, Montorsi F, Patard JJ, Rogers CG, et al. The expanding role of partial nephrectomy: a critical analysis of indications, results, and complications. *Eur Urol* 2010;57:214-22.
- Frank I, Blute ML, Cheville JC, Lohse CM, Weaver AL, Zincke H. Solid renal tumors: an analysis of pathological features related to tumor size. *J Urol* 2003;170(6 Pt 1):2217-20.
- Lane BR, Babineau D, Kattan MW, Novick AC, Gill IS, Zhou M, et al. A preoperative prognostic nomogram for solid enhancing renal tumors 7 cm or less amenable to partial nephrectomy. *J Urol* 2007;178:429-34.
- Murphy AM, Buck AM, Benson MC, McKiernan JM. Increasing detection rate of benign renal tumors: evaluation of factors predicting for benign tumor histologic features during past two decades. *Urology* 2009;73:1293-7.
- Glassman D, Chawla SN, Waldman I, Johannes J, Byrne DS, Trabulsi EJ, et al. Correlation of pathology with tumor size of renal masses. *Can J Urol* 2007;14:3616-20.
- Thompson RH, Kurta JM, Kaag M, Tickoo SK, Kundu S, Katz D, et al. Tumor size is associated with malignant potential in renal cell carcinoma cases. *J Urol* 2009;181:2033-6.
- Marhuenda A, Martin MI, Deltoro C, Santos J, Rubio Briones J. Radiologic evaluation of small renal masses (I): pretreatment management. *Adv Urol* 2008;415848.
- Verma SK, Mitchell DG, Yang R, Roth CG, O'Kane P, Verma M, et al. Exophytic renal masses: angular interface with renal parenchyma for distinguishing benign from malignant lesions at MR imaging. *Radiology* 2010;255:501-7.
- Wagner BJ, Wong-You-Cheong JJ, Davis CJ Jr. Adult renal hamartomas. *Radiographics* 1997;17:155-69.
- Jinzaki M, Tanimoto A, Narimatsu Y, Ohkuma K, Kurata T, Shinmoto H, et al. Angiomyolipoma: imaging findings in lesions with minimal fat. *Radiology* 1997;205:497-502.
- Kim JK, Park SY, Shon JH, Cho KS. Angiomyolipoma with minimal fat: differentiation from renal cell carcinoma at biphasic helical CT. *Radiology* 2004;230:677-84.
- Bosniak MA, Megibow AJ, Hulnick DH, Horii S, Raghavendra BN. CT diagnosis of renal angiomyolipoma: the importance of detecting small amounts of fat. *AJR Am J Roentgenol* 1988;151:497-501.
- Israel GM, Hindman N, Hecht E, Krinsky G. The use of opposed-phase chemical shift MRI in the diagnosis of renal angiomyolipomas. *AJR Am J Roentgenol* 2005;184:1868-72.
- Outwater EK, Bhatia M, Siegelman ES, Burke MA, Mitchell DG. Lipid in renal clear cell carcinoma: detection on opposed-phase gradient-echo MR images. *Radiology* 1997;205:103-7.
- Duchene DA, Lotan Y, Cadeddu JA, Sagalowsky AI, Koeneman KS. Histopathology of surgically managed renal tumors: analysis of a contemporary series. *Urology* 2003;62:827-30.
- Filipas D, Fichtner J, Spix C, Black P, Carus W, Hohenfellner R, et al. Nephron-sparing surgery of renal cell carcinoma with a normal opposite kidney: long-term outcome in 180 patients. *Urology* 2000;56:387-92.
- McKiernan J, Yossepowitch O, Kattan MW, Simmons R, Motzer RJ, Reuter VE, et al. Partial nephrectomy for renal cortical tumors: pathologic findings and impact on outcome. *Urology* 2002;60:1003-9.
- Shannon BA, Cohen RJ, de Bruto H, Davies RJ. The value of preoperative needle core biopsy for diagnosing benign lesions among small, incidentally detected renal masses. *J Urol* 2008;180:1257-61.
- Volpe A, Mattar K, Finelli A, Kachura JR, Evans AJ, Geddie WR, et al. Contemporary results of percutaneous biopsy of 100 small renal masses: a single center experience. *J Urol* 2008;180:2333-7.

25. Volpe A, Kachura JR, Geddie WR, Evans AJ, Gharajeh A, Saravanan A, et al. Techniques, safety and accuracy of sampling of renal tumors by fine needle aspiration and core biopsy. *J Urol* 2007;178:379-86.
26. Schmidbauer J, Remzi M, Memarsadeghi M, Haitel A, Klingler HC, Katzenbeisser D, et al. Diagnostic accuracy of computed tomography-guided percutaneous biopsy of renal masses. *Eur Urol* 2008;53:1003-11.
27. Rendon RA. Active surveillance as the preferred management option for small renal masses. *Can Urol Assoc J* 2010;4:136-8.