

Analysis of the presence or absence of atrophy of the subgenual and subcallosal cingulate cortices using voxel-based morphometry on MRI is useful to select prescriptions for patients with depressive symptoms

Akira Niida¹
Richi Niida²
Hiroshi Matsuda³
Makoto Motomura⁴
Akihiko Uechi⁵

¹Department of Radiology, Nanbu Hospital, Itoman City, Okinawa, Japan;

²Department of Psychiatry, Nanto Clinic, Urasoe City, Okinawa, Japan;

³Integrative Brain Imaging Center, National Center of Neurology and Psychiatry, Kodaira City, Tokyo, Japan;

⁴Department of Human Sciences, University of the Ryukyus, Nakagami County, Okinawa, Japan; ⁵Cognitive Neuroscience Research Project, Kansai Gaidai University, Hirakata City, Osaka, Japan

Objective: We objectively evaluated the presence or absence of atrophy of the subgenual anterior cingulate cortex (sgACC) and the subcallosal anterior cingulate cortex (scACC), using new voxel-based morphometry (VBM) software employing Statistical Parametric Mapping software v8 and diffeomorphic anatomic registration through an exponentiated lie algebra. We prepared a database covering young-mature adulthood and investigated the clinical usefulness of the evaluation.

Subjects and methods: One hundred seven patients with major depressive disorder (MDD), 74 patients with bipolar disorder (BD), and 240 healthy control subjects underwent 1.5T magnetic resonance imaging scanning. Using new VBM software and databases covering young-mature adults and the elderly, target volumes of interest were set in the sgACC and scACC, four indicators (severity, extent, ratio, and whole-brain extent) were determined, and the presence or absence of atrophy of the sgACC and scACC was evaluated on the basis of the indicators. In addition, the relationships between the presence or absence of atrophy of the sgACC and scACC and performance of diagnosing MDD and BD and therapeutic drugs were investigated.

Results: It was clarified that the disease is likely to be MDD when atrophy is detected in the sgACC, and likely to be BD when no atrophy is detected in the sgACC but is detected in the scACC. Regarding the relationship with therapeutic drugs, it was clarified that, when atrophy is detected in both the sgACC and the scACC, concomitant administration of mood stabilizers and atypical antipsychotics acting as dopamine-system stabilizers is necessary in many cases.

Conclusion: VBM on magnetic resonance imaging enabled automatic analysis of atrophy in the sgACC and scACC, and findings obtained by this procedure are useful not only for differentiation of MDD and BD patients but also for selection of prescriptions.

Keywords: major depressive disorder, bipolar disorder, MRI, subgenual anterior cingulate cortex, subcallosal anterior cingulate cortex, voxel-based morphometry

Introduction

Major depressive disorder (MDD) is a common, socially problematic mental illness. No useful biomarkers are available, and it is diagnosed by interview and observation of psychological symptoms. However, depressive symptoms similar to those of MDD develop in other mental diseases, such as the depressive phase of bipolar disorder (BD) and the early stage of cognitive disorder, and inappropriate treatment due to

Correspondence: Akira Niida
Department of Radiology, Nanbu Hospital, 870 Maezato, Itoman City, Okinawa, 901-0362, Japan
Tel +81 98 994 0501
Fax +81 98 994 0525
Email aniida@nirai.ne.jp

an inaccurate diagnosis has aggravated symptoms in some patients.^{1,2} Studies on the brain structure using magnetic resonance imaging (MRI)^{3–13} and functional studies using functional MRI and positron emission tomography^{14–18} have recently been actively performed, and MDD-related local cerebral regions are getting clarified.^{19,20} However, these are not actively applied clinically, and no useful auxiliary diagnostic method for MDD has been established. We previously reported that evaluation of the presence or absence of atrophy of the subgenual anterior cingulate cortex (sgACC; part of Brodmann's areas 24 and 33) in the elderly using voxel-based morphometry (VBM) on MRI is useful to diagnose MDD.^{21,22} However, the results may vary among examiners because it involves visual evaluation, leaving a problem regarding objectivity. Moreover, young-mature adult subjects were not evaluated because the database was limited to the elderly from 54–84 years old.

In this study, we set a target volume of interest (VOI) in local cerebral regions using published Statistical Parametric Mapping software v8 (SPM8; Wellcome Department of Imaging Neuroscience, London, UK). We objectively evaluated the presence or absence of atrophy of the sgACC by setting the target VOI in the sgACC using a method automatically determining values of four indicators of atrophy evaluation in the region.²³ At the same time, the target VOI in the subcallosal anterior cingulate cortex (scACC; part of Brodmann's area 25) was set to observe its association with MDD and BD, because it is the target region of deep-brain stimulation for intractable depression adjacent to the rostral side of the sgACC,²⁴ volume reduction of this region in BD has been reported,^{25,26} and atrophy was frequently observed in our BD patients. It was clarified that this region is related to both MDD and BD. Then, a database covering young-mature adulthood was prepared for each generation, and evaluation using this method was applied to young-mature adult subjects.

Finally, we investigated the usefulness of this method to diagnose MDD and BD in patients followed for 1 year or longer. It was clarified that analysis of the presence or absence of atrophy of the sgACC and scACC is useful to diagnose these diseases. Since therapeutic drugs administered to MDD and BD patients were not standardized, and effective drugs varied among patients, we investigated the relationship between cerebral local atrophy and therapeutic drugs. Responses of each disease could be divided into two groups on the basis of the relationship between the therapeutic effects of serotonin stabilizers related to depression, dopamine stabilizers related to intractable depression and BD,² and

mood stabilizers and the presence or absence of atrophy of the sgACC and scACC detected by this method.

Therefore, this method is expected to be a useful objective auxiliary diagnostic tool to diagnose depression in a broad age group, which was previously difficult.

Subjects and methods

This study was performed after approval by the Ethics Committee of Nanbu Hospital, Okinawa, Japan. Informed consent was obtained from all subjects.

The subjects were 181 patients who visited psychosomatic clinics for depressive symptoms characterized by continuous and overwhelming emotions of guilt, sadness, anhedonia, worthlessness, and despair and who underwent MRI examination between January 2010 and July 2013. There were 107 MDD patients (12 males and 95 females aged 20–90 years [mean: 60.2±14.7 years]) and 74 BD patients (19 males and 55 females aged 17–89 years [mean: 48.0±15.2 years]). MDD and BD were definitively diagnosed after course observation for 1 year or longer by psychiatrists, on the basis of structured clinical interviews following the *Diagnostic and Statistical Manual of Mental Disorders* (4th edition) criteria.²⁷ Patients with a serious somatic disease, cardiovascular and neurological disorders, or alcohol- or drug-induced disorders were excluded. The grade of depression was evaluated using the Hamilton Depression Rating Scale comprising 17 items.²⁸ In the MDD patients, ≥50% improvement on this scale was achieved by treatment. Patients diagnosed with BD were evaluated using the Young Mania Rating Scale.²⁹ As healthy controls, 240 healthy volunteers (76 males and 164 females aged 19–77 years [mean: 44.4±15.8 years]) were recruited for comparison of the target VOI setting, preparation of a database covering young-mature adulthood, and comparison with MDD and BD patients. They had no psychoneurological disease, serious somatic disease, or alcohol- or drug-induced disorders.

We performed MRIs of the brain with a 1.5T magnetic resonance imager (Achieva Nova; Koninklijke Philips Electronics NV, Amsterdam, the Netherlands) using an eight-channel sensitivity-encoding head coil. The structural data were provided in three-dimensional T1-weighted fast field echo sequence (repetition time/echo time/flip angle: 9.3 msec/4.3 msec/10°). Images were acquired with a 256×256 matrix with a 240×240 mm field of view. The reconstruction voxel size was 0.94×0.94×0.94 mm. A total of 160 sagittal sections of 2 mm slice thickness with 1 mm slices superimposed were acquired. Two measurements were obtained and averaged. The total acquisition time was 3 minutes 35 seconds.

First, to define the target VOI of the sgACC for diagnosis of MDD, we performed group comparisons between 30 patients (two men and 28 women; mean age, 66.0 ± 6.8 years) randomly chosen in the present MDD group and 30 healthy controls (six men and 24 women; mean age, 64.5 ± 4.4 years) randomly chosen in the present healthy volunteer group. Next, to define the target VOI of the scACC for diagnosis of BD, we performed group comparisons between 31 patients (seven men and 24 women; mean age, 67.9 ± 8.8 years) randomly chosen in the present BD group and the previously mentioned 30 healthy controls. Using SPM8, we segmented MRIs into gray matter, white matter, and cerebrospinal fluid images by a unified tissue-segmentation procedure after image-intensity nonuniformity correction. These segmented gray matter images were then spatially normalized to the customized template in the standardized anatomic space by using diffeomorphic anatomic registration through an exponentiated lie algebra (DARTEL, Wellcome Department of Imaging Neuroscience).³⁰ The customized template for DARTEL was created from the 25 healthy young subjects. To preserve gray matter volume within each voxel, we modulated the images by the Jacobean determinants derived from the spatial normalization by DARTEL and then smoothed them by using an 8 mm full width at half maximum Gaussian kernel. Group comparisons by SPM8 were assessed by using the familywise error at a threshold of $P < 0.05$, corrected for multiple comparisons.

A standalone software program running on Windows for VBM analysis by SPM8 plus DARTEL was developed to discriminate patients with MDD and BD from healthy controls. First, MRIs were spatially normalized with only a 12-parameter affine transformation to the SPM8 template so as to correct differences in brain size. These linearly transformed images were nonlinearly transformed and then modulated to the customized template for DARTEL, followed by smoothing by using an 8 mm full width at half maximum kernel. Each processed gray matter image of 82 patients with MDD, 25 patients with BD, and 43 healthy controls in the elderly was compared with the mean and SD of gray matter images of the 80 healthy volunteers chosen in the group comparison, using voxel-by-voxel z -score analysis: $z \text{ score} = ([\text{control mean}] - [\text{individual value}]) / (\text{control SD})$. These z -score maps were displayed by overlay on tomographic sections and surface rendering of the standardized brain. This program registered the target VOI defined by the aforementioned group comparison.

We determined four indicators for characterizing atrophy in a target VOI and in the whole brain: first, “severity,” the severity of atrophy obtained from the averaged positive z score in the

target VOI; second, “extent,” the extent of a region showing significant atrophy in the target VOI – that is, the percentage rate of the coordinates with a z score exceeding the threshold value of 2 in the target VOI; third, “whole-brain extent,” the extent of a region showing significant atrophy in the whole brain – that is, the percentage rate of the coordinates with a z score exceeding the threshold value of 2 in the whole brain; and fourth, “ratio,” the ratio of the extent of a region showing significant atrophy in the target VOI to the extent of a region showing significant atrophy in the whole brain.²³

Using the values of the four indicators as the thresholds, we determined receiver operating characteristic (ROC) curves for discrimination of patients with MDD and patients with BD from healthy volunteers. The program calculates the area under the ROC curve (AUC), sensitivity, specificity, and accuracy. The sensitivity, specificity, and accuracy were compared on the basis of these values and visual evaluation of overlay regions displayed when atrophy was present in the target VOI in tomographic sections.

To prepare databases as comparison references for young-mature adult generations, 42 healthy volunteers aged 20–29 years (15 males and 27 females, mean age: 25.7 ± 1.7 years), 44 healthy volunteers aged 30–39 years (15 males and 29 females, mean age: 34.1 ± 2.3 years), and 43 healthy volunteers aged 40–53 years (17 males and 26 females, mean age: 45.5 ± 3.4 years) were recruited (note that the elderly database comprises data on those aged ≥ 54 years). Processed images of the gray matter of 25 MDD patients aged ≤ 53 years (two males and 23 females, mean age: 38.5 ± 8.9 years) were compared with the mean and SD of images of the gray matter of 38 healthy volunteers of each generation (12 males and 26 females, mean age 36.1 ± 9.3 years) selected for z -score analysis. Similar comparison was performed with 49 BD patients (12 males and 37 females, mean age: 39.2 ± 9.0 years).

Using the values of the four indicators described above as the thresholds, an ROC curve was prepared to differentiate MDD and BD patients from healthy volunteers. The AUC, sensitivity, specificity, and accuracy were calculated and compared with those of visual observation of overlay regions in the target VOI in tomographic sections.

In the 181 young-mature adult and elderly patients who could be followed for 1 year or longer and definitively diagnosed, the association between the disease name and effective drugs was investigated in patients with sgACC atrophy, patients with scACC atrophy, patients with both sgACC and scACC atrophy, and patients without atrophy based on the four indicators described above.

Results

Target VOI

Using SPM8 and DARTEL, we noted a significant reduction of the gray matter volume of the sgACC (Talairach coordinates 0,25,-3, x,y,z; z=infinite) in elderly MDD patients aged ≥ 54 years compared with the healthy controls, and it was possible to draw a contour as a target VOI that may be useful to diagnose depression (Figures 1 and 2). A significant reduction in the gray matter volume of the scACC (Talairach coordinates 0,9,-10, x,y,z; z=5.89) in BD patients was also confirmed, and it was possible to draw a contour as a target VOI that may be useful to diagnose BD.

Four indicators characterizing sgACC and scACC atrophy in the elderly

Three indicators (severity, extent, and ratio) in the sgACC and scACC were significantly higher in the elderly MDD patients than in the healthy controls ($P < 0.001$), and the whole-brain extent was also significantly higher ($P < 0.001$) (Table 1). In BD patients, the three indicators (severity, extent, and ratio) in the scACC were significantly higher than those in the healthy controls ($P < 0.001$). In addition, the three indicators in the sgACC were significantly higher in the MDD patients than in the BD patients ($P < 0.001$). These findings indicated that the disease is likely to be MDD when the three indicators are high in the sgACC, and likely to be BD when the three indicators are high in scACC but not in the sgACC.

Performance of diagnosing MDD in the elderly

On ROC analysis to distinguish MDD patients from healthy controls, of the four indicators, the accuracy based on severity,

extent, and ratio in the sgACC was 93.6%, 91.2%, and 88.0%, respectively, whereas that of diagnosis made by visual evaluation was 96.8% (Table 2). Since sgACC atrophy was frequently noted in MDD, the cutoff value for MDD, 1.1, was used. Regarding conditions with the severity exceeding the cutoff value for MDD with the extent exceeding 0 as atrophy, that is, regarding cases with visually observable atrophy as atrophy, the accuracy was 96.8%. In the scACC, the accuracy based on severity, extent, and ratio was 76.8%, 60.0%, and 56.0%, respectively, whereas accuracy by visual evaluation was 69.6%. Since the scACC plays the major role in differentiating BD, the cutoff value for BD, 0.9, was used. Regarding conditions with the severity exceeding the cutoff value for BD with the extent exceeding 0 as atrophy, that is, regarding cases with visually observable atrophy as atrophy, the accuracy was 69.6%.

Performance of diagnosing BD in the elderly

On ROC analysis to distinguish BD patients from healthy controls, the accuracy based on severity, extent, and ratio in the sgACC was 63.2%, 58.8%, and 58.8%, respectively, and accuracy by visual evaluation was 57.4% (Table 2). When conditions with the severity exceeding the cut-off value for MDD, 1.1, with the extent exceeding 0 as atrophy, that is, regarding cases with visually observable atrophy as atrophy, the accuracy was 57.4%. In the scACC, the accuracy based on the three indicators was 76.5%, 76.5%, and 73.5%, respectively, and accuracy by visual evaluation was 80.9%. Regarding conditions with the severity exceeding the cutoff value for BD, 0.9, with the extent exceeding 0 as atrophy, that is, regarding cases with visually observable atrophy as atrophy, the accuracy was 80.1%.

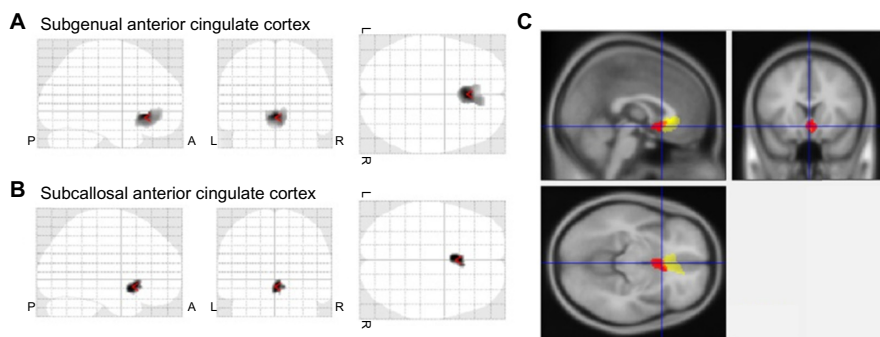


Figure 1 Target VOIs in typical cases.

Notes: (A) Group comparison of gray matter volume in the sgACCs by SPM8 plus DARTEL between 30 patients with MDD and 30 healthy age-matched volunteers. The SPM8 plus DARTEL analysis demonstrates significant decline of gray matter volume in the sgACCs in patients with MDD. (B) Group comparison of gray matter volume in the scACCs by SPM8 plus DARTEL between 31 patients with BD and 30 healthy age-matched volunteers. The SPM8 plus DARTEL analysis demonstrates significant decline in gray matter volume in the scACCs in patients with BD. (C) The SPM8 analysis indicates that two target VOIs of the sgACC (yellow area) and scACC (red area) did not overlap each other.

Abbreviations: A, anterior; BD, bipolar disorder; DARTEL, diffeomorphic anatomic registration through an exponentiated lie algebra; L, left; MDD, major depressive disorder; P, posterior; R, right; scACC, subcallosal anterior cingulate cortex; sgACC, subgenual anterior cingulate cortex; SPM8, Statistical Parametric Mapping software v8; VOI, volume of interest.

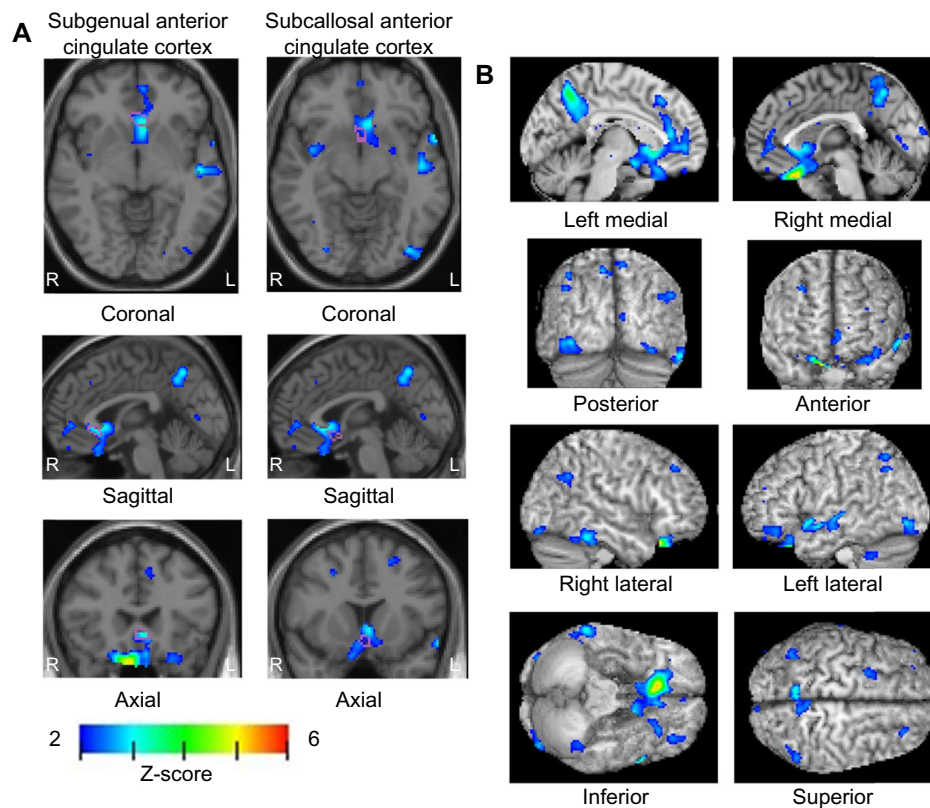


Figure 2 Cross-sectional VBM study of a 62-year-old woman with MDD.

Notes: SPM8 plus DARTel analysis reveals a significant decrease of gray matter volume in the sgACC and the scACC. Colored areas with z-scores >2 are overlaid as significantly atrophied regions on tomographic sections (A) and cortical surface (B) of the standardized MRI templates. A target VOI in the sgACC and the scACC is demarcated with purple lines on tomographic sections (A).

Abbreviations: DARTel, diffeomorphic anatomic registration through an exponentiated lie algebra; L, left; MDD, major depressive disorder; R, right; scACC, subcallosal anterior cingulate cortex; sgACC, subgenual anterior cingulate cortex; SPM8, Statistical Parametric Mapping software v8; VBM, voxel-based morphometry; VOI, volume of interest.

Four indicators characterizing sgACC and scACC atrophy in young-mature adults

Using the young-mature adulthood database covering subjects aged 20–53 years, three indicators (severity, extent, and ratio) in sgACC and scACC were significantly higher in young-mature adult MDD patients than in the young healthy controls ($P < 0.001$) (Table 3). In young-mature adult BD patients, the three indicators in scACC were significantly higher than those in the young healthy controls ($P < 0.001$). In addition, the three indicators in sgACC were significantly

higher in young-mature adult MDD patients than in young-mature adult BD patients ($P < 0.001$). These findings indicate the usefulness of this method for young-mature adults similarly to that for the elderly.

Performance of diagnosing MDD in young-mature adults

On ROC analysis to distinguish young-mature adult MDD patients from young healthy controls, the accuracy based on the severity, extent, and ratio in the sgACC was 92.1, 81.0,

Table 1 Four indicators characterizing sgACC and scACC atrophy in the elderly (54–90 years of age)

Group	Whole-brain extent, %	Subgenual anterior cingulate cortex			Subcallosal anterior cingulate cortex		
		Target VOI			Target VOI		
		Severity	Extent, %	Ratio	Severity	Extent, %	Ratio
HC (n=43)	2.00±0.86	0.69±0.40	0.48±1.69	0.38±1.60	0.56±0.31	0.10±0.54	0.03±0.20
MDD (n=82)	2.79±1.20 ^a	1.84±0.42 ^{ab}	26.54±21.05 ^{a*,b*}	10.85±9.80 ^{a*,b*}	1.14±0.56 ^{a*}	12.46±23.05 ^{a*}	5.03±9.96 ^{a*}
BD (n=25)	2.51±1.07	0.86±0.40	1.00±6.32	0.23±1.45	0.90±0.48 ^c	5.67±11.03 ^{c*}	2.30±4.26 ^{c*}

Notes: ^aMDD versus HC, $P < 0.001$; ^bMDD versus BD, $P < 0.001$; ^cBD versus HC, $P < 0.001$ (Student's *t*-test); ^{a*}MDD versus HC, $P < 0.001$ (Welch's *t*-test); ^{a*}MDD versus HC, $P < 0.001$; ^{b*}MDD versus BD, $P < 0.001$; ^{c*}BD versus HC, $P < 0.001$ (Mann-Whitney *U* test).

Abbreviations: BD, bipolar disorder; HC, healthy controls; MDD, major depressive disorder; sgACC, subcallosal anterior cingulate cortex; sgACC, subgenual anterior cingulate cortex; VOI, volume of interest.

Table 2 Performance of diagnosing MDD and BD in the elderly (54–90 years of age)

Group	Subgenual anterior cingulate cortex				Subcallosal anterior cingulate cortex					
	Indicators for evaluation		Target VOI		Indicators for evaluation		Target VOI			
	Cut off	Sensitivity, %	Specificity, %	Accuracy, %	AUC	Cut off	Sensitivity, %	Specificity, %	Accuracy, %	AUC
MDD	Severity	≥ 1.1	100.0	81.4	93.6	≥ 0.7	79.2	72.1	76.8	0.831
	Extent (%)	≥ 3	90.2	93.0	91.2	≥ 3	40.2	97.7	60.0	0.693
	Ratio	≥ 2	85.4	93.0	88.0	≥ 2	32.9	100.0	56.0	0.665
	Visual	-	100.0	90.7	96.8	-	56.1	95.3	69.6	-
	Severity ≥ 1.1 plus extent (%) > 0	-	100.0	90.7	96.8	-	56.1	95.3	69.6	-
BD	Severity	≥ 0.6	84.0	51.2	63.2	≥ 0.9	56.0	88.4	76.5	0.754
	Extent (%)	≥ 3	0.0	93.0	58.8	≥ 3	40.0	97.7	76.5	0.691
	Ratio	≥ 2	0.0	93.0	58.8	≥ 2	28.0	100.0	73.5	0.640
	Visual	-	0.0	90.7	57.4	-	56.0	95.3	80.9	-
	Severity ≥ 1.1 plus extent (%) > 0	-	0.0	90.7	57.4	-	52.0	97.7	80.1	-

Abbreviations: AUC, area under the receiver operating characteristic curve; BD, bipolar disorder; MDD, major depressive disorder; VOI, volume of interest.

and 82.5%, respectively, and that by visual evaluation was 88.9% (Table 4). Regarding conditions with the severity exceeding the cutoff value for MDD, 0.8, with the extent exceeding 0 as atrophy, that is, regarding cases with visually observable atrophy as atrophy, the accuracy was 88.9%. In the scACC, the accuracy based on the three indicators were 82.5%, 79.4%, and 82.5%, respectively, and that by visual evaluation was 82.5%. Regarding conditions with the severity exceeding the cutoff value for BD, 0.5, with extent exceeding 0 as atrophy, the accuracy was 82.5%.

Performance of diagnosing BD in young-mature adults

On ROC analysis to distinguish young-mature adult BD patients and young healthy controls, the accuracy based on the three indicators in the sgACC was 62.1%, 43.7%, and 43.7%, respectively, and accuracy by visual evaluation was 43.7% (Table 4). Regarding conditions with the severity exceeding the cutoff value for MDD, 0.8, with the extent exceeding 0 as atrophy, the accuracy was 43.7%. In the scACC, the accuracy based on the three indicators was 75.9% 65.5%, and 64.4%, respectively, and accuracy by visual evaluation was 70.1%. Regarding conditions with the severity exceeding the cutoff value for BD, 0.5, with the extent exceeding 0 as atrophy, the accuracy was 70.1%.

Relationship between cerebral local atrophy and diagnoses of MDD and BD

On the basis of ROC analysis, for the elderly, a condition with the severity exceeding 1.1 with the extent exceeding 0% in the sgACC was defined as atrophy. In the scACC, to identify BD, a condition with the severity exceeding 0.9 with the extent exceeding 0% was defined as atrophy. For young-mature adults, a condition with the severity exceeding 0.8 with the extent exceeding 0% in the sgACC was defined as atrophy. To identify BD, a condition with the severity exceeding 0.5 with the extent exceeding 0% in the scACC was defined as atrophy.

Regarding the association between the presence or absence of atrophy in each region and diagnosis in the 181 patients, 46 patients with MDD were judged as having atrophy only in sgACC (Table 5). Fifty four patients with MDD were judged as having atrophy in both the sgACC and the scACC. Thirty-seven patients with BD were judged as having atrophy only in the scACC. No atrophy was noted in either the sgACC or the scACC in 44 patients, and the diagnosis was MDD in seven and BD in 37. These findings indicate that the disease is likely to be MDD when atrophy

Table 3 Four indicators characterizing sgACC and scACC atrophy in young-mature adults (17–53 years of age)

Group	Whole-brain extent, %	Subgenual anterior cingulate cortex			Subcallosal anterior cingulate cortex		
		Target VOI			Target VOI		
		Severity	Extent, %	Ratio	Severity	Extent, %	Ratio
HC (n=38)	1.70±0.75	0.33±0.36	0±0	0±0	0.35±0.36	0±0	0±0
MDD (n=25)	1.95±0.94	1.39±0.45 ^{ab}	11.64±17.08 ^{ab}	5.66±8.60 ^{ab}	1.25±0.82 ^a	21.76±31.23 ^a	11.13±15.13 ^a
BD (n=49)	1.90±0.78	0.48±0.40	0±0	0±0	1.04±0.61 ^c	10.38±18.61 ^c	5.28±10.73 ^c

Notes: ^aMDD versus HC, $P<0.001$; ^bMDD versus BD, $P<0.001$; ^cBD versus HC, $P<0.001$ (Mann–Whitney U test).

Abbreviations: BD, bipolar disorder; HC, healthy controls; MDD, major depressive disorder; scACC, subcallosal anterior cingulate cortex; sgACC, subgenual anterior cingulate cortex; VOI, volume of interest.

is detected in the sgACC, and likely to be BD when atrophy is detected in the scACC without atrophy in the sgACC.

Case presentation

Typical cases are shown in Figure 3. The first case is MDD in a 55-year-old female. Atrophy represented by the colored region was noted only in the target VOI in the sgACC in the median sagittal image. No colored region was noted in the target VOI in the scACC. The patient was diagnosed with MDD and treated with antidepressants, and symptoms improved. The patient now has favorable living activities under antidepressant treatment at a low maintenance dose (Figure 3A). The second case is MDD in a 32-year-old female. A colored region was noted in the target VOI in both the sgACC and scACC in the median sagittal image. Antidepressant treatment for MDD induced manic/hypomanic switch, but symptoms were improved by reduction of the antidepressant dose and concomitant administration of mood stabilizers and atypical antipsychotics (Figure 3B). The third case is BD in a 62-year-old female. A colored region was noted in the target VOI only in the scACC in the median sagittal image. No colored region was noted in the target VOI in the sgACC. The patient was diagnosed with BD and received atypical antipsychotic treatment, and symptoms improved (Figure 3C). The fourth case is a 68-year-old healthy male subject. No colored region was noted in the target VOI in either the sgACC or scACC in the median sagittal image (Figure 3D).

Relationship between cerebral local atrophy and treatment of MDD and BD patients

Regarding the association between the presence or absence of atrophy in each region and therapeutic drugs, antidepressants were mainly prescribed for 45 of the 46 patients only with the sgACC atrophy, and the drugs were effective. Antidepressants improved symptoms, but maintenance administration at a low dose was necessary in 39 of

the 45 patients (Table 6). Mood stabilizers and atypical antipsychotics were concomitantly administered with antidepressants in six patients. Tranquilizer was administered to one of the 46 patients, and symptoms improved.

Of the 54 patients with atrophy in both the sgACC and scACC, antidepressants were mainly prescribed and effective in 53. Symptoms improved, but maintenance administration at a low dose was necessary in 25 of the 53 patients. Mood stabilizers and atypical antipsychotics were concomitantly administered with antidepressants in 28 patients. Herbal medicine was administered to the remaining patient, and symptoms improved. It should be noted that antidepressant-associated manic/hypomanic switch occurred in eight patients.

In the 37 patients with atrophy only in the scACC, antidepressants were prescribed to some extent in ten, and antidepressant was administered to eight patients for a short time. Antidepressants, mood stabilizers, and atypical antipsychotics were concomitantly administered to two patients. Of the 37 patients, mood stabilizers and atypical antipsychotics were prescribed and effective in 22, and anti-anxiety and hypnotics, and herbal medicine were administered to five patients.

Of the 44 patients with no atrophy in either the sgACC or scACC, antidepressants were prescribed and effective in seven. In two of them, antidepressants improved symptoms and the drugs are now administered at a low maintenance dose. In the remaining five patients, antidepressants were administered for a short time. Of the 44 patients with no atrophy, mood stabilizers and atypical antipsychotics were prescribed and effective in 34. In the remaining three patients, anti-anxiety and hypnotics, and herbal medicine improved symptoms.

Discussion

Development of the new software enabled VBM analysis using SPM8 and DARTEL and automatic determination of the severity and extent of sgACC atrophy. When the usefulness of these values as indicators was investigated,

Table 4 Performance of diagnosing MDD and BD in young-mature adults (17–53 years of age)

Group	Subgenual anterior cingulate cortex				Subcallosal anterior cingulate cortex									
	Indicators for evaluation		Target VOI		Indicators for evaluation		Target VOI							
	Severity	Extent (%)	Cut off	Sensitivity, %	Specificity, %	Accuracy, %	AUC	Severity	Extent (%)	Cut off	Sensitivity, %	Specificity, %	Accuracy, %	AUC
MDD	Severity	≥0.8	≥0.8	96.0	89.8	92.1	0.966	Severity	≥0.5 plus extent (%) >0	≥0.1	68.0	92.1	82.5	0.854
	Extent (%)	≥3	≥3	52.0	100.0	81.0	0.760	Extent (%)	≥3	≥3	48.0	100.0	79.4	0.740
	Ratio	≥2	≥2	56.0	100.0	82.5	0.780	Ratio	≥2	≥2	56.0	100.0	82.5	0.780
	Visual	-	-	72.0	100.0	88.9	-	Visual	-	-	56.0	100.0	82.5	-
	Severity ≥0.8 plus extent (%) >0	-	-	72.0	100.0	88.9	-	Severity ≥0.5 plus extent (%) >0	-	-	56.0	100.0	82.5	-
BD	Severity	≥0.8	≥0.8	59.2	65.8	62.1	0.623	Severity	≥0.5 plus extent (%) >0	≥0.5	75.5	76.3	75.9	0.836
	Extent (%)	≥3	≥3	0.0	100.0	43.7	0.500	Extent (%)	≥3	≥3	38.8	100.0	65.5	0.694
	Ratio	≥2	≥2	0.0	100.0	43.7	0.500	Ratio	≥2	≥2	36.7	100.0	64.4	0.684
	Visual	-	-	0.0	100.0	43.7	-	Visual	-	-	46.9	100.0	70.1	-
	Severity ≥0.8 plus extent (%) >0	-	-	0.0	100.0	43.7	-	Severity ≥0.5 plus extent (%) >0	-	-	46.9	100.0	70.1	-

Abbreviations: AUC, area under the receiver operating characteristic curve; BD, bipolar disorder; MDD, major depressive disorder; VOI, volume of interest.

Table 5 Relationship between cerebral local atrophy and diagnoses of MDD and BD (17–90 years of age)

Diagnosis	Sites of atrophic region			
	Subgenual ACC n=46	Subgenual ACC and subcallosal ACC n=54	Subcallosal ACC n=37	No atrophy n=44
MDD	46	54	0	7
BD	0	0	37	37

Abbreviations: ACC, anterior cingulate cortex; BD, bipolar disorder; MDD, major depressive disorder.

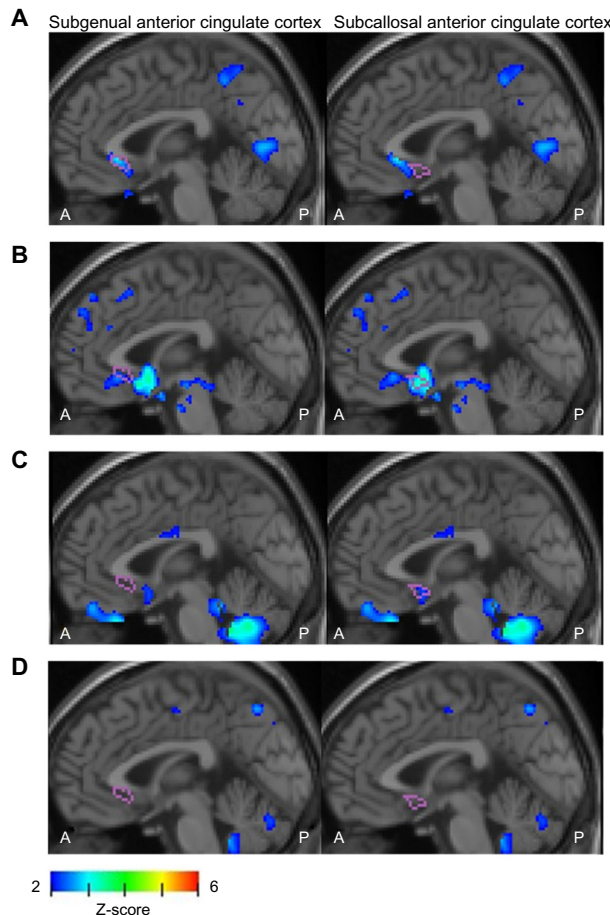


Figure 3 Median sagittal images from typical cases.

Notes: (A) Median sagittal image of a 55-year-old female with MDD. A colored region was present in the target VOI in the sgACC. No colored region was noted in the target VOI in the scACC. Antidepressant treatment for MDD improved symptoms. The patient now has favorable living activities under antidepressant treatment at a low maintenance dose. (B) Median sagittal image of a 32-year-old female with MDD. A colored region was noted in the target VOI in both the sgACC and scACC. Antidepressant treatment for MDD induced manic/hypomanic switch, but symptoms were improved by reduction of the antidepressant dose and concomitant administration of mood stabilizers and atypical antipsychotics. (C) Median sagittal image of a 62-year-old female with BD. A colored region was noted in the target VOI in the scACC. No colored region was noted in the target VOI in the sgACC. The patient was diagnosed with BD and received atypical antipsychotic treatment, and symptoms improved. (D) Median sagittal image of a 68-year-old healthy male. No colored region was noted in the target VOI in either the sgACC or scACC.

Abbreviations: A, anterior; BD, bipolar disorder; MDD, major depressive disorder; P, posterior; scACC, subcallosal anterior cingulate cortex; sgACC, subgenual anterior cingulate cortex; VOI, volume of interest.

Table 6 Relationship between cerebral local atrophy and treatment of MDD and BD patients (17–90 years of age)

Medication	Progress of the medication	Sites of atrophic region			
		Subgenual ACC n=46	Subgenual ACC and subcallosal ACC n=54	Subcallosal ACC n=37	No atrophy n=44
Antidepressant	A little maintenance dosage of the antidepressant	39	25	0	2
	The dosage ended after the antidepressant short-term dosage	0	0	8	5
	The combination of mood stabilizer, atypical antipsychotic	6	28	2	0
Mood stabilizer, atypical antipsychotic	No dosage of the antidepressant	0	0	22	34
Other agents	No dosage of the antidepressant	1	1	5	3

Abbreviations: ACC, anterior cingulate cortex; BD, bipolar disorder; MDD, major depressive disorder.

their usefulness was similar to that of visual evaluation of overlay regions on tomographic sections with regard to their differentiation of the elderly MDD and BD patients from the healthy control subjects.

When the severity and extent of the scACC, newly paid attention to, was used as an indicator, the sensitivity, specificity, and accuracy were similar to those of visual evaluation, for differentiation between the elderly BD patients and healthy controls.

Using the newly developed database covering young-mature adulthood for VBM analysis employing SPM8 and DARTEL, when the severity and extent of the sgACC and scACC were used as indicators, the sensitivity, specificity, and accuracy were similar to those of elderly patients for differentiation between the young-mature adult MDD patients and healthy controls.

By using two indicators, ie, severity and extent, and the database covering young-mature adulthood, objective evaluation of atrophy in the sgACC and scACC with an accuracy similar to that of visual evaluation became possible. This can facilitate sharing and comparison of information on local cerebral atrophy among multiple facilities, which had previously been difficult,^{21,22} further increasing the clinical usefulness of this method.

Summarizing the relationship between the presence or absence of atrophy of the sgACC and scACC and diagnoses of MDD and BD, sgACC atrophy was noted in most of the MDD patients. In contrast, no sgACC atrophy was detected in BD patients, while scACC atrophy was noted in half of them. On the basis of these findings, the sgACC is strongly associated with MDD. scACC atrophy was noted in both MDD and BD in some cases. Thus, differentiation of the diseases based on atrophy alone is not possible, but it may be useful to differentiate BD patients from healthy subjects to some extent.

Summarizing the relationship between the presence or absence of atrophy of the sgACC and scACC and effective therapeutic drugs, the 46 patients with sgACC atrophy alone were mainly treated with antidepressants, but many patients, particularly elderly patients, required low-dose maintenance administration after the remission of symptoms.

The 54 MDD patients with both sgACC and scACC atrophy were treated with antidepressants similarly to the patients with sgACC atrophy alone, but combination with atypical antipsychotics acting as dopamine-system stabilizers³¹ was effective for many patients. It should be mentioned that manic/hypomanic switch was induced by antidepressants in eight patients in this group.

For many of the 37 BD patients with scACC atrophy alone, mood stabilizers and atypical antipsychotics acting as dopamine-system stabilizers were prescribed.

The characteristics of BD with scACC atrophy alone were as follows. 1) Manic/hypomanic switch was induced by treatment with antidepressants alone, indicating that the symptoms were due to manic depressive psychosis, but the depressive phase accounted for the majority. For treatment, symptoms were improved by concomitant administration of dopamine-related drugs at a low dose, such as olanzapine, aripiprazole, quetiapine, and pramipexole. Mood stabilizers acting on dopamine through the glutamate system, such as lamotrigine, were also effective.^{32–36} 2) Complications by somatic diseases, such as asthma, rheumatism, collagen disease, allergic rhinitis, and complex regional pain syndrome, were frequently noted (many complications required steroid treatment). 3) Detailed adjustment of prescription was necessary due to drug sensitivity in many patients, and the disease was intractable in many of them.

It has recently been clarified that latent bipolar disorder is the main cause of intractable MDD, and involvement of the dopaminergic system in the pathology and treatment of both

intractable MDD and BD was suggested.² In our study, drugs acting on the dopaminergic system were effective for patients with the scACC atrophy, clarifying the association between the scACC and dopamine. On the basis of the above findings, we consider that, when only scACC atrophy is detected, the patient should be treated for BD, not for intractable MDD for which antidepressants are ineffective, and drugs acting on the dopaminergic system should be prescribed without antidepressants, as a rule. Concomitant antidepressants may be necessary depending on the case. Anatomically, the scACC is interrelated with the amygdala, thalamus, hypothalamus, orbitofrontal cortex, and insula, and close association with the pathologies of MDD and BD has been suggested, being an interesting region related to the oxytocin and glutamate pathways.

In the group without atrophy in either the sgACC or scACC, short-term antidepressant administration improved symptoms in patients with MDD. For BD, mood stabilizers and atypical antipsychotics mainly were prescribed and improved symptoms.

Regarding the relationship between the presence or absence of atrophy in each region and effective therapeutic drugs, serotonergic antidepressants were effective for many patients with the sgACC atrophy, and atypical antipsychotics acting as dopamine-system stabilizers were effective for many patients with the scACC atrophy. This suggests that the sgACC is related to serotonin regulation, and the scACC is related to dopamine regulation. Neural circuits including the anterior cingulate gyrus have been assumed for MDD and BD, but further studies are awaited with regard to the roles of the sgACC and scACC.^{37–39}

The results of the pharmacological effects were summarized by region as follows. 1) Antidepressants were very effective for patients complaining of depressive symptoms with atrophy only in the sgACC, but once the condition became a depressive state, continuation of administration at a low dose was necessary for most patients. 2) For patients with atrophy in both the sgACC and scACC, antidepressants are basic treatment, but drug-induced manic/hypomanic switch may occur, and concomitant mood stabilizers and atypical antipsychotics acting as dopamine-system stabilizers may be necessary in some cases. 3) For patients in a depressive state with atrophy noted only in the scACC, antidepressants are administered for a short time as a rule because manic/hypomanic switch is induced, and concomitant administration of mood stabilizers and atypical antipsychotics acting as dopamine-system stabilizers are necessary. However, there are many intractable cases. 4) When no atrophy is noted

in either sgACC or scACC, improvement of symptoms by antidepressants is observed within a short time in many cases. When symptoms are not improved within a short time, investigation of BD and other diseases is necessary.

It was suggested that distinguishing MDD treatment strategies between cases with sgACC atrophy alone and sgACC and scACC atrophy is useful. It was also suggested that distinguishing BD treatment strategies between cases with and without scACC atrophy is useful.

It was confirmed that analysis of the sgACC and scACC using this simple VBM in routine medical practice can not only be utilized for auxiliary diagnoses of MDD and BD, but also provide useful information for deciding on a treatment strategy, suggesting the effectiveness of this differentiation method as an auxiliary diagnostic method.

There remain several problems, however. Firstly, the possibility of including subjects with latent MDD before onset and those vulnerable to BD development in the database of normal cases, particularly the database of normal young-mature adults, cannot be ruled out. Atrophies of the sgACC and scACC are not diseases of MDD and BD, and these are considered to represent vulnerability to disease development.⁴⁰ The mental conditions of patients before onset are the same as those of normal individuals, and differentiation is impossible. Actually, the cutoff values of the indicators of sgACC and scACC atrophies differed between the elderly and young-mature adults and tended to be lower in the latter group. The MDD and BD diagnosis rates were also slightly lower. These may have been evidence of a mixture of subjects vulnerable to MDD and BD development in whom the score should be essentially higher than in healthy individuals. It may be necessary to verify the difference by measuring the local cerebral volumes.

Secondly, although three different generations in young-mature adulthood should have been individually evaluated, evaluation by generation was difficult because of the small number of young-mature adult patients. Calculation was performed using the individual databases of the three age groups, but the results were evaluated as a single group representing young-mature adults. Accordingly, the results may have been slightly different from those compared in each age group, and this may have had an influence on the differences in the findings between the young-mature adults and the elderly. It is necessary to verify the results by increasing the number of young-mature adult patients and evaluating each generation.

Last but not least, this method is just an auxiliary diagnostic method, and it cannot be used while overlooking

interviews about mental symptoms and observation of patients. A depressive state occurs in menopause with rapid changes in hormones, even though there is no atrophy, and antidepressants were effective for some patients. It should be emphasized that, in terms of the pharmacological effects of drugs, it cannot be simply considered that the absence of sgACC atrophy equals ineffectiveness of antidepressants.

In summary, using VBM on MRI, automatic analysis of atrophy in the sgACC and scACC became possible, which not only facilitated accurately diagnosing patients with depressive symptoms, but was also useful to decide on prescriptions. In addition, objective indicators were established, which enabled analysis at multiple facilities. The accumulation of more cases is expected, along with the establishment of this method as a highly accurate auxiliary diagnostic method.

Conclusion

In this study, we developed a method for the automatic analysis of atrophy of sgACC and scACC in young-mature adults and the elderly. We have shown that the findings obtained by using this method are useful not only to differentiate patients with depressive symptoms but also to decide on prescriptions.

On the basis of the analytical findings, the following conclusions were drawn. 1) Antidepressants are effective for patients complaining of depressive symptoms with atrophy detected only in the sgACC, but maintenance administration is necessary. 2) Antidepressants are a basic treatment when atrophy is detected in both the sgACC and scACC, but drug-induced manic/hypomanic switch is likely to occur, and concomitant administration of mood stabilizers and atypical antipsychotics acting as dopamine-system stabilizers is necessary. 3) When atrophy is detected only in the scACC, antidepressants should be used only for a short term as a rule because these drugs frequently induce manic/hypomanic switch, and it is necessary concomitantly to administer mainly mood stabilizers and atypical antipsychotics acting as dopamine-system stabilizers. However, there are many intractable cases. 4) When no atrophy is observed in either the sgACC or the scACC, improvement of symptoms by antidepressants is observed within a short time. When symptoms are not improved by short-term medication, it is necessary to investigate the possibility of BD and other diseases.

Furthermore, objective indicators were established, and information on local cerebral atrophy can be readily shared and compared among multiple facilities, which is expected to be utilized as an accurate auxiliary diagnostic tool for patients with depressive symptoms.

Acknowledgment

We are grateful to Takako Kuniyoshi from Nanto Clinic for her encouragement and administrative support.

Disclosure

The authors report no conflicts of interest in this work.

References

- Parker GB, Malhi GS, Crawford JG, Thase ME. Identifying "paradigm failures" contributing to treatment-resistant depression. *J Affect Disord.* 2005;87(2-3):185-191.
- Li CT, Bai YM, Huang YL, et al. Association between antidepressant resistance in unipolar depression and subsequent bipolar disorder: cohort study. *Br J Psychiatry.* 2012;200(1):45-51.
- Mervaala E, Föhr J, Könönen M, et al. Quantitative MRI of the hippocampus and amygdala in severe depression. *Psychol Med.* 2000;30(1):117-125.
- Frodl T, Schaub A, Banac S, et al. Reduced hippocampal volume correlates with executive dysfunctioning in major depression. *J Psychiatry Neurosci.* 2006;31(5):316-323.
- Campbell S, MacQueen G. An update on regional brain volume differences associated with mood disorders. *Curr Opin Psychiatry.* 2006;19(1):25-33.
- Yucel K, McKinnon MC, Chahal R, et al. Anterior cingulate volumes in never-treated patients with major depressive disorder. *Neuropsychopharmacology.* 2008;33(13):3157-3163.
- Bremner JD, Vythilingam M, Vermetten E, et al. Reduced volume of orbitofrontal cortex in major depression. *Biol Psychiatry.* 2002;51(4):273-279.
- Hastings RS, Parsey RV, Oquendo MA, Arango V, Mann JJ. Volumetric analysis of the prefrontal cortex, amygdala, and hippocampus in major depression. *Neuropsychopharmacology.* 2004;29(5):952-959.
- Tang Y, Wang F, Xie G, et al. Reduced ventral anterior cingulate and amygdala volumes in medication-naïve females with major depressive disorder: A voxel-based morphometric magnetic resonance imaging study. *Psychiatry Res.* 2007;156(1):83-86.
- Frodl T, Jäger M, Born C, et al. Anterior cingulate cortex does not differ between patients with major depression and healthy controls, but relatively large anterior cingulate cortex predicts a good clinical course. *Psychiatry Res.* 2008;163(1):76-83.
- Koolschijn PC, van Haren NE, Lensvelt-Mulders GJ, Hulshoff Pol HE, Kahn RS. Brain volume abnormalities in major depressive disorder: a meta-analysis of magnetic resonance imaging studies. *Hum Brain Mapp.* 2009;30(11):3719-3735.
- van Tol MJ, van der Wee NJ, van den Heuvel OA, et al. Regional brain volume in depression and anxiety disorders. *Arch Gen Psychiatry.* 2010;67(10):1002-1011.
- Amico F, Meisenzahl E, Koutsouleris N, Reiser M, Möller HJ, Frodl T. Structural MRI correlates for vulnerability and resilience to major depressive disorder. *J Psychiatry Neurosci.* 2011;36(1):15-22.
- Anand A, Li Y, Wang Y, et al. Activity and connectivity of brain mood regulating circuit in depression: a functional magnetic resonance study. *Biol Psychiatry.* 2005;57(10):1079-1088.
- Siegle GJ, Thompson W, Carter CS, Steinhauer SR, Thase ME. Increased amygdala and decreased dorsolateral prefrontal BOLD responses in unipolar depression: related and independent features. *Biol Psychiatry.* 2007;61(2):198-209.
- Bench CJ, Friston KJ, Brown RG, Scott LC, Frackowiak RS, Dolan RJ. The anatomy of melancholia – focal abnormalities of cerebral blood flow in major depression. *Psychol Med.* 1992;22(3):607-615.
- Drevets WC, Price JL, Simpson JR, et al. Subgenual prefrontal cortex abnormalities in mood disorders. *Nature.* 1997;386(6627):824-827.
- Drevets WC, Savitz J, Trimble M. The subgenual anterior cingulate cortex in mood disorders. *CNS Spectr.* 2008;13(8):663-681.

19. Liu F, Guo W, Yu D, et al. Classification of different therapeutic responses of major depressive disorder with multivariate pattern analysis method based on structural MR scans. *PLoS One*. 2012;7(7):e40968.
20. Bora E, Fornito A, Pantelis C, Yücel M. Gray matter abnormalities in Major Depressive Disorder: a meta-analysis of voxel based morphometry studies. *J Affect Disord*. 2012;138(1–2):9–18.
21. Niida R, Niida A, Motomura M, Uechi A. Diagnosis of depression by MRI scans with the use of VSRAD – a promising auxiliary means of diagnosis: a report of 10 years research. *Int J Gen Med*. 2011;4:377–387.
22. Niida A, Niida R, Matsuda H, Inada T, Motomura M, Uechi A. Identification of atrophy of the subgenual anterior cingulate cortex, in particular the subcallosal area, as an effective auxiliary means of diagnosis for major depressive disorder. *Int J Gen Med*. 2012;5:667–674.
23. Matsuda H, Mizumura S, Nemoto K, et al. Automatic voxel-based morphometry of structural MRI by SPM8 plus diffeomorphic anatomic registration through exponentiated lie algebra improves the diagnosis of probable Alzheimer Disease. *AJNR Am J Neuroradiol*. 2012;33(6):1109–1114.
24. Mayberg HS, Lozano AM, Voon V, et al. Deep brain stimulation for treatment-resistant depression. *Neuron*. 2005;45(5):651–660.
25. Ellison-Wright I, Bullmore E. Anatomy of bipolar disorder and schizophrenia: a meta-analysis. *Schizophr Res*. 2010;117(1):1–12.
26. Bora E, Fornito A, Yücel M, Pantelis C. Voxelwise meta-analysis of gray matter abnormalities in bipolar disorder. *Biol Psychiatry*. 2010;67(11):1097–1105.
27. American Psychiatric Association. *DSM-IV: Diagnostic and Statistical Manual of Mental Disorders*. 4th ed. Washington DC: American Psychiatric Association Press; 2000.
28. Hamilton M. A rating scale for depression. *J Neurol Neurosurg Psychiatry*. 1960;23:56–62.
29. Young RC, Biggs JT, Ziegler VE, Meyer DA. A rating scale for mania: reliability, validity and sensitivity. *Br J Psychiatry*. 1978;133:429–435.
30. Ashburner J. A fast diffeomorphic image registration algorithm. *Neuroimage*. 2007;38(1):95–113.
31. Jordan S, Koprivica V, Chen R, Tottori K, Kikuchi T, Altar CA. The antipsychotic aripiprazole is a potent, partial agonist at the human 5-HT1A receptor. *Eur J Pharmacol*. 2002;441(3):137–140.
32. Berk M, Dodd S, Kauer-Sant’anna M, et al. Dopamine dysregulation syndrome: implications for a dopamine hypothesis of bipolar disorder. *Acta Psychiatr Scand Suppl*. 2007;(434):41–49.
33. Nakato Y, Abekawa T, Ito K, Inoue T, Koyama T. Lamotrigine blocks apoptosis induced by repeated administration of high-dose methamphetamine in the medial prefrontal cortex of rats. *Neurosci Lett*. 2011;490(3):161–164.
34. Sumioka A. Auxiliary subunits provide new insights into regulation of AMPA receptor trafficking. *J Biochem*. 2013;153(4):331–337.
35. Du J, Suzuki K, Wei Y, et al. The anticonvulsants lamotrigine, riluzole, and valproate differentially regulate AMPA receptor membrane localization: relationship to clinical effects in mood disorders. *Neuropsychopharmacology*. 2007;32(4):793–802.
36. Abekawa T, Ito K, Nakagawa S, Nakato Y, Koyama T. Olanzapine and risperidone block a high dose of methamphetamine-induced schizophrenia-like behavioral abnormalities and accompanied apoptosis in the medial prefrontal cortex. *Schizophr Res*. 2008;101(1–3):84–94.
37. Delgado MR, Nearing KI, Ledoux JE, Phelps EA. Neural circuitry underlying the regulation of conditioned fear and its relation to extinction. *Neuron*. 2008;59(5):829–838.
38. Killgore WD, Yurgelun-Todd DA. Ventromedial prefrontal activity correlates with depressed mood in adolescent children. *Neuroreport*. 2006;17(2):167–171.
39. Hajek T, Carrey N, Alda M. Neuroanatomical abnormalities as risk factors for bipolar disorder. *Bipolar Disord*. 2005;7(5):393–403.
40. Boes AD, McCormick LM, Coryell WH, Nopoulos P. Rostral anterior cingulate cortex volume correlates with depressed mood in normal healthy children. *Biol Psychiatry*. 2008;63(4):391–397.

International Journal of General Medicine

Publish your work in this journal

The International Journal of General Medicine is an international, peer-reviewed open-access journal that focuses on general and internal medicine, pathogenesis, epidemiology, diagnosis, monitoring and treatment protocols. The journal is characterized by the rapid reporting of reviews, original research and clinical studies across all disease areas.

Submit your manuscript here: <http://www.dovepress.com/international-journal-of-general-medicine-journal>

Dovepress

A key focus is the elucidation of disease processes and management protocols resulting in improved outcomes for the patient. The manuscript management system is completely online and includes a very quick and fair peer-review system. Visit <http://www.dovepress.com/testimonials.php> to read real quotes from published authors.