

Russell Body Gastritis Treated With *Helicobacter pylori* Eradication Therapy: Magnifying Endoscopic Findings With Narrow Band Imaging Before and After Treatment

Naoyuki Nishimura, MD¹, Motowo Mizuno, MD¹, Yuichi Shimodate, MD¹, Akira Doi¹, Hirokazu Mouri, MD¹, Kazuhiro Matsueda, MD¹, Hiroshi Yamamoto, MD¹, and Kenji Notohara, MD²

¹Department of Gastroenterology and Hepatology, Kurashiki Central Hospital, Kurashiki, Japan

²Department of pathology, Kurashiki Central Hospital, Kurashiki, Okayama, Japan

ABSTRACT

Russell body gastritis is considered a benign inflammatory disease. This is the first report that documented the disease's natural history over a 15-month period and the response to eradication of *Helicobacter pylori*, with follow-up for another 15 months. In addition, Russell body gastritis was observed with magnifying endoscopy and narrow-band imaging. In the period of 30 months, we were able to record progression of the disease in the untreated state and its complete regression after clearance of *H. pylori*.

INTRODUCTION

Russell body gastritis (RBG), first described by Tazawa et al in 1998, is an unusual gastric mucosal lesion, characterized by the accumulation of numerous plasma cells containing eosinophilic cytoplasmic inclusions (Russell bodies).¹ Russell bodies are considered to be condensed immunoglobulins resulting from disturbed secretion in the cisternae of the rough endoplasmic reticulum.² Plasma cells filled with Russell bodies are immunoreactive for CD45, CD79a, and immunoglobulin G.¹ With the use of immunohistochemical analysis of immunoglobulin light chains, both polyclonal and monoclonal expansions of the plasma cells have been seen.³ Russell body gastritis is considered a benign inflammatory disease, but it may be confused with neoplastic diseases such as mucosa-associated lymphoid tissue (MALT) lymphoma and plasmacytoma. Russell body gastritis is a rare disease, but reports of the disease are increasing in parallel with improvements in gastrointestinal endoscopy and increased recognition of the disease by endoscopists and pathologists. However, many issues regarding RBG, such as its natural history, clinical significance, and a possible etiologic role of *Helicobacter pylori* remain uncertain.³ Also, endoscopic findings of RBG are not well defined. Magnifying endoscopy with narrow-band imaging (ME-NBI) is useful for the diagnosis of gastritis and gastric cancers, because it visualizes microsurface structures and microvessels.⁴

CASE REPORT

A 64-year-old woman with bronchiectasis underwent esophagogastroduodenoscopy because of heartburn and for a health check. She did not have a history of alcohol abuse, and her serological examination was negative for human immunodeficiency virus infection. A white, granular lesion, about 2 cm in size, was seen on the posterior wall of the lower gastric body (Figure 1). A mucosal biopsy revealed active chronic gastritis with infiltrating neutrophils, lymphocytes, and plasma cells containing numerous Russell bodies (Figure 2). Nuclear atypia, lymphoepithelial lesions,

ACG Case Rep J 2016;3(4):e96. doi:10.14309/crj.2016.69. Published online: August 3, 2016.

Correspondence: Naoyuki Nishimura, Department of Gastroenterology and Hepatology, Kurashiki Central Hospital, 1-1-1 Miwa, Kurashiki, Okayama, 710-8602, Japan (nn13543@kchnet.or.jp).



Copyright: © 2016 Nishimura et al. This work is licensed under a Creative Commons Attribution-NonCommercial-NoDerivatives 4.0 International License. To view a copy of this license, visit <http://creativecommons.org/licenses/by-nc-nd/4.0>.

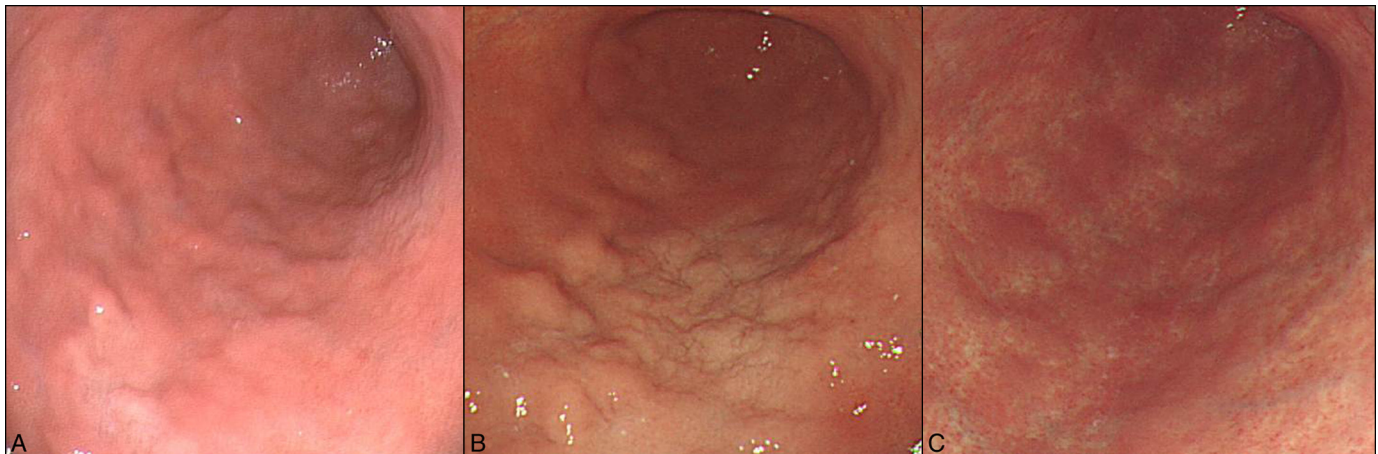


Figure 1. Conventional endoscopic findings. (A) A white, granular lesion is present on the posterior wall of the lower gastric body. (B) Fifteen months after the diagnosis of RBG, the lesion has grown larger. (C) Fifteen months after the eradication therapy, the lesion is no longer present.

and Dutcher bodies, which are attributed to immunoglobulin-filled nuclear pseudoinclusions and are often associated with low-grade malignant lymphoma,⁵ were not present. The plasma cells were immunohistochemically positive for both kappa and lambda light chains, which indicated that the cells were not neoplastic. Therefore, the lesion was diagnosed as RBG. Because the treatment and the natural course of the disease have not been established, we decided to carefully watch the lesion without treatment.

The follow-up esophagogastroduodenoscopy, performed 15 months after the diagnosis, revealed that the lesion had grown larger. Magnifying endoscopy with narrow-band imaging showed destruction and partial disappearance of the microsurface structure of the mucosa and irregular, elongated, and distorted wavy microvessels (Figure 3). These

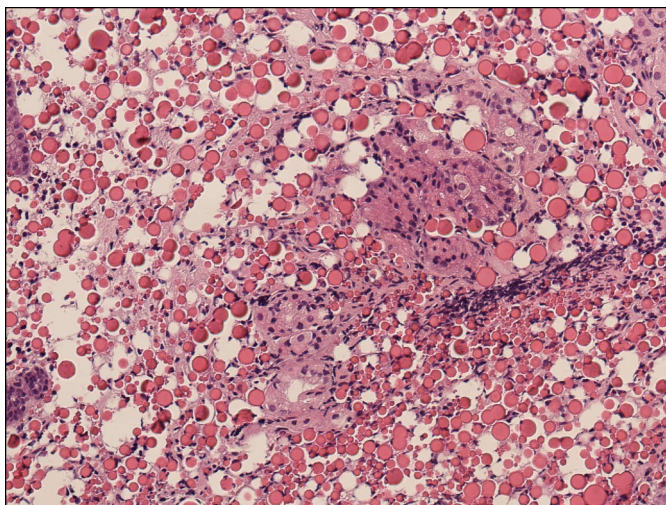


Figure 2. Histological appearance of biopsy taken from the lesion. Expansion of the lamina propria by infiltration of numerous plasma cells with Russell bodies is present (hematoxylin and eosin stain 20x magnification).

findings have some similarity with those of diffuse-type gastric cancer⁶ or MALT lymphoma.⁷ However, the irregular vessels were more linear and longer than the corkscrew pattern in diffuse-type gastric cancer,⁶ and were thinner than those of the tree-like appearance of MALT lymphoma.⁷ Biopsy specimens from the lesion again had the features of RBG and no evidence of neoplastic disease.

The patient's serum anti-*H. pylori* antibody test was positive, and histologic examination of gastric biopsies also showed *H. pylori* infection. The patient received *H. pylori* eradication therapy with amoxicillin 750 mg and clarithromycin 200 mg together with lansoprazole 30 mg twice a day for 1 week. Cure of *H. pylori* infection was documented by urea breath test 3 months after the therapy. Esophagogastroduodenoscopy performed 6 months after the eradication therapy revealed regression of the white, granular lesion, and 15 months later, the lesion had completely disappeared. Magnifying endoscopy with narrow-band imaging at this time showed the regular microsurface structures and microvessels of normal fundic gland mucosa. In the biopsy specimens of this area, the plasma cells with Russell bodies were no longer present; only mild mononuclear inflammatory cell infiltration was present.

DISCUSSION

To our knowledge, this is the first report of RBG with ME-NBI findings that documented the disease's natural history over a 15-month period and the response to eradication of *H. pylori*, with follow-up for another 15 months. Thus, in the period of 30 months, we were able to record progression of the disease in the untreated state and its regression after clearance of *H. pylori*.

Little is known about either the short- or long-term course of RBG. Araki et al⁸ reported that RBG of monoclonal type did not change during 1-year follow-up, which supports the

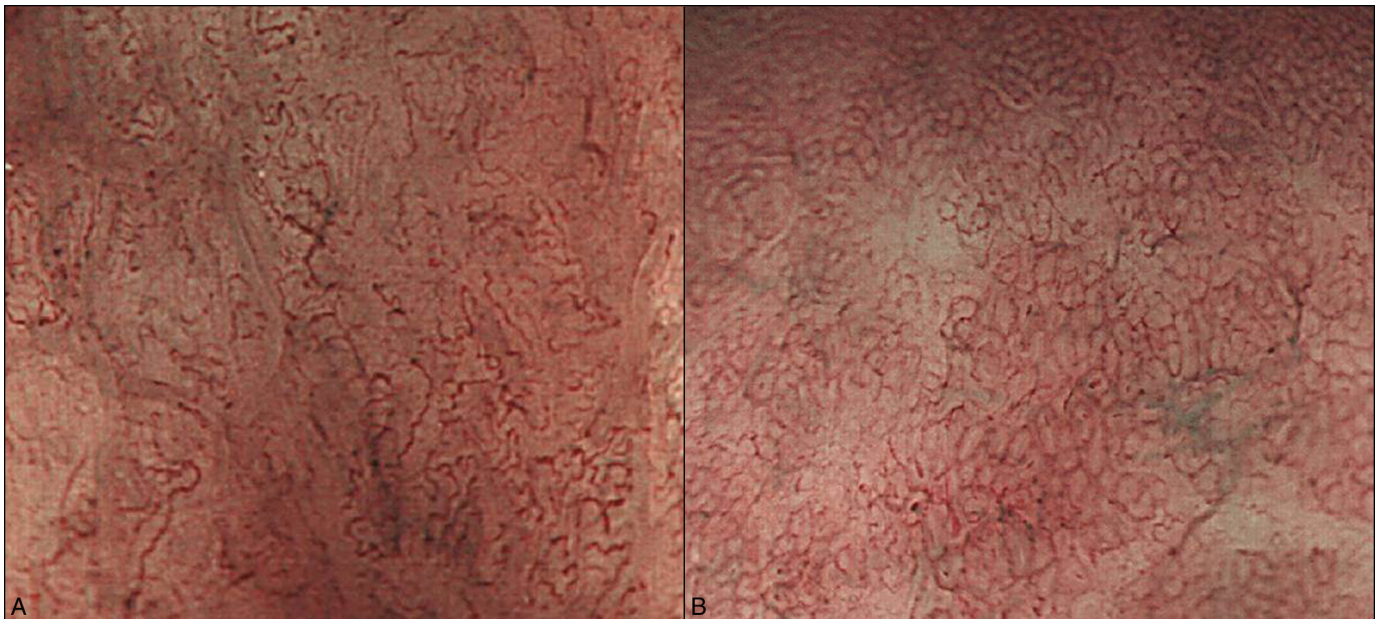


Figure 3. Findings with magnifying endoscopy and narrow band imaging. (A) Before eradication therapy, loss of microsurface structures and irregular microvessels with elongation and distortion can be seen. (B) After *H. pylori* eradication therapy, regular microsurface structures and microvessels have been restored.

opinion that RBG is a benign inflammatory change that does not progress to lymphoid neoplasia. However, findings in our patient suggest that it had the potential to progress to lymphoid neoplasia: the lesion enlarged during the relatively short period of 15 months, and the ME-NBI characteristics initially were similar to those of superficial-type MALT lymphoma.

Our report contributes to evidence that *H. pylori* infection can cause RBG. Although more than 60% of reported RBG cases have been associated with *H. pylori* infection,³ and regression of RBG after *H. pylori* eradication therapy has been reported,^{3,9} the etiology of RBG remains uncertain. Nonetheless, eradication treatment of *H. pylori* in RBG cases when the infection is found seems to be a logical. Other suggested causes for RBG are human immunodeficiency virus infection and alcohol abuse,³ which were not factors in our patient. Whatever the cause, an inflammatory response or immunological abnormality inducing plasma-cell hyperactivation might lead to the formation of Russell bodies.¹⁰

DISCLOSURES

Author contributions: The authors contributed equally to the creation of this manuscript. N. Nishimura is the article quarantor.

Financial disclosure: None to report.

Informed consent was obtained for this case report.

Received October 14, 2015; Accepted January 15, 2016

REFERENCES

1. Tazawa K, Tsutsumi Y. Effect of prolonged staining with hematoxylin on detecting *Helicobacter pylori* in hematoxylin-eosin-stained gastric mucosa. *Pathol Int*. 1998;48(6):448-52.
2. Hsu SM, Hsu PL, McMillan PN, Fanger H. Russell bodies: A light and electron microscopic immunoperoxidase study. *Am J Clin Pathol*. 1982; 77(1):26-31.
3. Zhang H, Jin Z, Cui R. Russell body gastritis/duodenitis: A case series and description of immunoglobulin light chain restriction. *Clin Res Hepatol Gastroenterol*. 2014;38(5):e89-97.
4. Yao K, Doyama H, Gotoda T, et al. Diagnostic performance and limitations of magnifying narrow-band imaging in screening endoscopy of early gastric cancer: A prospective multicenter feasibility study. *Gastric Cancer*. 2014;17(4):669-79.
5. Zakerberg LR, Ferry JA, Southern JF, Harris NL. Lymphoid infiltrates of the stomach. Evaluation of histologic criteria for the diagnosis of low-grade gastric lymphoma on endoscopic biopsy specimens. *Am J Surg Pathol*. 1990;14(12):1087-99.
6. Nakayoshi T, Tajiri H, Matsuda K, et al. Magnifying endoscopy combined with narrow band imaging system for early gastric cancer: Correlation of vascular pattern with histopathology (including video). *Endoscopy*. 2004;36(12):1080-4.
7. Nonaka K, Ishikawa K, Arai S, et al. A case of gastric mucosa-associated lymphoid tissue lymphoma in which magnified endoscopy with narrow band imaging was useful in the diagnosis. *World J Gastrointest Endosc*. 2012;4(4):151-6.
8. Araki D, Sudo Y, Imamura Y, Tsutsumi Y. Russell body gastritis showing IgM kappa-type monoclonality. *Pathol Int*. 2013;63(11):565-7.
9. Bhajjee F, Brown KA, Long BW, Brown AS. Russell body gastroenteritis: an aberrant manifestation of chronic inflammation in gastrointestinal mucosa. *Case Rep Med*. 2013;2013:797264.
10. Paik S, Kim SH, Kim JH, et al. Russell body gastritis associated with *Helicobacter pylori* infection: A case report. *J Clin Pathol*. 2006; 59(12):1316-9.

