

CASE REPORT

Theatrical fire pursuant exploratory laparotomy

Oliver C. Bellevue^{1,*}, Bennett M. Johnson¹, Andrew F. Feczko¹,
Daniel E. Nadig², and David M. White²

¹Department of General Surgery, Swedish Medical Center, Seattle, WA, USA, and ²Department of General Surgery, Pacific Medical Centers, Seattle, WA, USA

*Correspondence address. Department of General Surgery, Swedish Medical Center, Seattle, WA 98122, USA. Tel: +(206) 998-5628; Fax: +(206) 386-6293; Email: oliverbellevue@gmail.com

Abstract

Fire in the operating theater is a rare but potentially fatal complication. We report igniting an intraperitoneal fire while performing an exploratory laparotomy for perforated viscus. Fortunately, the patient suffered no injuries as a result.

INTRODUCTION

Fires in the operative theater are rare, but preventable events. They are generally associated with airway surgery or the use of high energy devices such as lasers. Very limited data regarding the ignition of gastrointestinal gas is present in the literature. We report the ignition of an intraperitoneal fire while performing an exploratory laparotomy for perforated viscus and review other similar reports.

CASE REPORT

A 63-year-old cachectic female with a medical history of multiple myeloma and advanced amyloidosis was admitted to our institution with complaints of left lateral thigh pain and nausea. At the time of presentation, her myeloma and associated vertebral fractures were under active treatment with cyclophosphamide and bortezomib. Ibuprofen had been prescribed 10 days prior to admission for musculoskeletal pain. The patient's nausea was associated with increasing abdominal distention over approximately 3 months. Computerized axial tomography performed on admission (Fig. 1) demonstrated a dilated stomach containing fecalized material. The patient reported passing gas and stool. She was placed on a general diet and was managed without nasogastric decompression as per her medical team. She continued to receive ibuprofen and

was treated with pulse dose steroids, cyclophosphamide and bortezomib until hospital day 5 when the patient complained of sudden, severe abdominal pain.

An abdominal plain film revealed substantial pneumoperitoneum and general surgery was consulted with concern for perforated viscus. Examination at that time revealed a tympanic, diffusely tender abdomen without overt signs of peritonitis. The patient's amyloidosis had resulted in severe macroglossia with multiple episodes of epistaxis and glossal hemorrhage. Nasogastric decompression was deliberately deferred given her friable macroglossia and expected endotracheal intubation. She was taken to the operating theater for exploratory laparotomy which preceded in standard fashion after rapid sequence induction.

Electrocautery was used to dissect through the subcutaneous tissues. When a deliberate incision was made into the peritoneum a loud clap was heard which was followed by a dull roar and 3–4 s of blue flame erupting from the peritoneal cavity. In this interval, the attending physician attempted to extinguish the fire with a moist towel causing a superficial burn to one of his fingers. When the flame had self-extinguished, the patient's wound was inspected and remarkably found to be free of injury or burn. The abdomen was inspected thoroughly and was also without any evidence of burn injury. An ulcer found on the greater curvature was biopsied and Graham

Received: April 25, 2016. Accepted: May 5, 2016

Published by Oxford University Press and JSCR Publishing Ltd. All rights reserved. © The Author 2016.

This is an Open Access article distributed under the terms of the Creative Commons Attribution Non-Commercial License (<http://creativecommons.org/licenses/by-nc/4.0/>), which permits non-commercial re-use, distribution, and reproduction in any medium, provided the original work is properly cited. For commercial re-use, please contact journals.permissions@oup.com

patched. The pylorus was hypertrophic, but widely patent with good movement of gastric contents into the duodenum.

Post-operatively the patient did well without apparent complication. An upper gastrointestinal series was performed on post-operative day 5 (Fig. 2) which was negative for leak but notable for very limited transit of contrast into the duodenum 2 h after administration. Her pathology returned negative for *H. Pylori*, negative for malignancy, but positive for abundant amyloid deposits. Ultimately, she was discharged home to hospice care given her overall decline.

DISCUSSION

The rapid exothermic combustion of gastrointestinal gasses is a rarely described, if feared complication in the operating theater. The American Society of Anesthesiologists endorses the 'fire triad,' composed of an oxidizer, an ignition source and a fuel [1]. The principle oxidizers found in the operating room are the oxygen enriched environment and nitrous oxide. Ignition usually occurs secondary to electrocautery, argon beam coagulators, lasers and other sources of electrical current. Fuels include volatile solutions such as alcohol, ether, chlorhexidine,

acetone as well as drapes, sponges, blankets, packing materials and gastrointestinal gasses (methane and hydrogen).

Although reportable to the Federal Drug Administration, the number or type of surgical fires per year are not published. The Emergency Care Resource Institute estimates that 200–240 fires occur annually within the United States [2]. Although fires are reported with more frequency in colonoscopy, other authors have witnessed similar gastrointestinal gas ignitions (Table 1).

Compared with these other published reports, our patient fared relatively, even surprisingly well after this intraabdominal explosion. We speculate that nasogastric decompression prior to the operating room, deferred given the patient's friable macroglossia, may have mitigated her intraperitoneal gaseous environment to an extent that may have prevented this fire. Although preoxygenated, she underwent rapid sequence induction and we do not suspect that any significant amount of 100% oxygen was pumped into her peritoneal cavity. Despite not having a mechanical gastric outlet obstruction, amyloid-induced gastroparesis resulted in the optimal environment for fermentation. We strongly recommend sharp entry into the

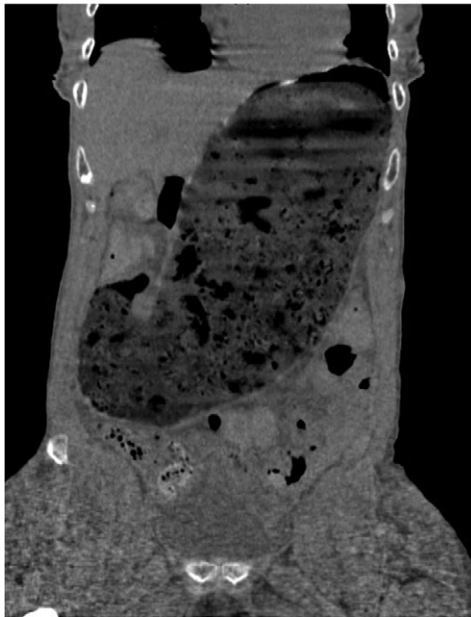


Figure 1: Computed tomography scan at presentation (prior to perforation) demonstrating gastric distention secondary to amyloid provoked gastroparesis with fecalization of gastric contents.

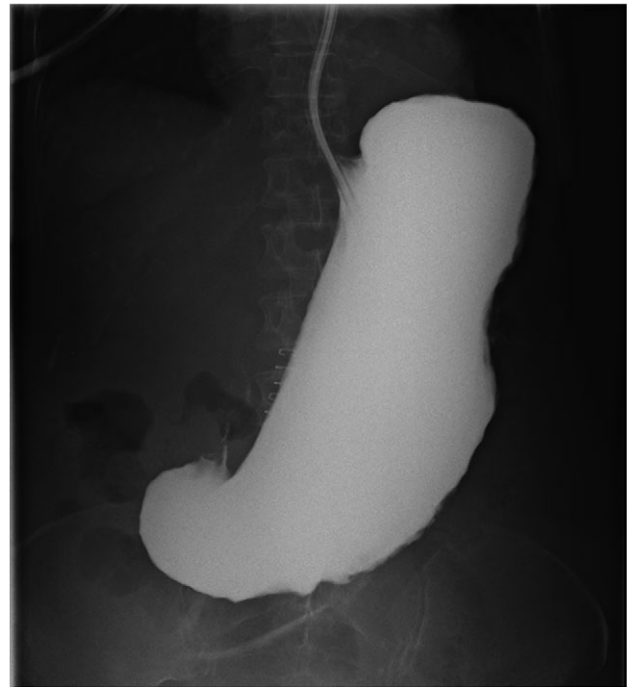

Figure 2: Upper gastrointestinal series 2 h after gastrografin contrast administration down nasogastric tube demonstrates no leak and no passage of contrast from severe gastroparesis.

Table 1. All reported studies of theatrical fires involving the ignition of gastrointestinal gasses. The heat source in all incidents was electrocautery.

Author	Year	Indication	Fuel	Harm
Joyce [3]	1989	Decompressive gastrostomy	Gastric gas	Gastric rupture with ignition.
Dhebri [4]	2002	Gastric perforation	Gastric gas	Rupture of diaphragm, splenic tears requiring splenectomy and death 3 h post-operative. Flash burn to surgeon's face with singeing of eyebrows.
Mansfield [5]	2012	Gastric perforation	Intraperitoneal gas	No harm to patient, 2nd degree burn to surgeon's finger.
Mumith [6]	2013	Cecal perforation	Intraperitoneal gas	No harm to patient, partial thickness burn to surgeon's hand.
Raghavan [7]	2015	Toxic megacolon	Colonic gas	No harm.
Raghavan [7]	2015	Transverse colon perforation	Intraperitoneal gas	No harm.

peritoneal cavity whenever intraperitoneal gastrointestinal gasses may be present.

CONFLICT OF INTEREST STATEMENT

None declared.

REFERENCES

1. Apfelbaum JL, Caplan RA, Barker SJ, Connis RT, Cowles C, Ehrenwerth J, et al. Practice advisory for the prevention and management of operating room fires: an updated report by the American Society of Anesthesiologists Task Force on Operating Room Fires. *Anesthesiology* 2013;**118**:271–90.
2. https://www.ecri.org/Accident_Investigation/Pages/Surgical-Fire-Prevention.aspx. (14 May 2016, date last accessed).
3. Joyce FS, Rasmussen TN. Gas explosion during diathermy gastrotomy. *Gastroenterology* 1989;**96**:530–1.
4. Dhebri AR, Afify SE. Free gas in the peritoneal cavity: the final hazard of diathermy. *Postgrad Med J* 2002;**78**:496–7.
5. Mansfield SK, Borrowdale R. Intraperitoneal explosion following gastric perforation. *Asian J Surg* 2014;**37**:110–3.
6. Mumith A, Thuraisingham J, Gurunathan-Mani S. Ignition of free gas in the peritoneal cavity: an explosive complication. *Case Rep Surg* 2013;**2013**:746430.
7. Raghavan K, Lagisetty KH, Butler KL, Cahalane MJ, Gupta A, Odom SR. Intraoperative fires during emergent colon surgery. *Am Surg* 2015;**81**:E82–3.