

● PERSPECTIVE

Ischemic penumbra in retina endures: vascular neuropathology is reconciled

A physiological state of “normoxia” obtains when tissue oxygen tension (pO_2) is sufficient to drive mitochondrial respiration throughout a volume of cells. Between 30–40% of the available oxygen is normally extracted from hemoglobin as it passes through neural tissue, implying a balance between oxygen delivery and consumption that includes a healthy reserve in case of increased oxygen demand (“energy homeostasis”). Tissue oxygenation is not restricted to the capillary microcirculation but can also be sourced from larger afferent vessels (as His demonstrated in 1880 when he discovered the retinal peri-arterial capillary-free zone). Of note, retinal “arteries” are $<100\ \mu\text{m}$ in diameter (as are cerebral cortical “arteries”) and correspond to large “arterioles” elsewhere. Regardless of terminology, the angio-architectural pattern is key to the distribution and heterogeneity of tissue pO_2 values, the highest being found near the largest afferent vessels.

Modest reductions in tissue perfusion may have no adverse consequences for parenchymal cells, but progressive oligemia results in diminishing hemoglobin-oxygen saturation (sO_2) values within blood draining the tissue. This indicates a reduction in the local oxygen reserve and, as the oxygen extraction fraction (OEF) increases towards 100%, such “misery perfusion” also implies exaggerated heterogeneity of tissue pO_2 values (the lowest approaching 0 mmHg) and steepening of the sO_2 gradient within the arterial tree. Thus, a disproportionate fraction of the available oxygen is extracted in the proximal portion of the vascular path, hemoglobin becoming relatively or completely deoxygenated by the time it reaches the distal portion. When the tissue pO_2 no longer supports oxidative metabolism adequately, the cellular dysfunction or injury arising exhibits 2 readily distinguishable

grades of severity, namely “ischemic hypoxia” (once an initial threshold of perfusion failure is crossed) and “ischemic anoxia” (once the volume flow of blood decreases by a further 50% or so). The hypoxic tissue compartment wherein local perfusion values (and, by inference, tissue pO_2 values) lie between these 2 thresholds is called the “ischemic penumbra” (Astrup et al., 1977).

Hypo-oxygenation thresholds: The “dual-threshold” paradigm for tissue hypo-oxygenation emerged from studies of baboon cerebral cortex wherein graduated tissue hypoperfusion was achieved by modulating the “pressure-passive” collateral circulation from distal arterio-arterial anastomoses following trans-orbital occlusion of the middle cerebral artery (MCAO). Below the first (“hypoxic” or “penumbra”) threshold, cortical neurons adapt to the low tissue pO_2 , and maintain their structural integrity, by suppressing evoked responses and spontaneous activity (which are energy-expensive) whilst safeguarding essential vegetative processes. Thus, the hypo-metabolic neurons are “electrically silent” but they maintain “ionic homeostasis” (*i.e.*, membrane polarization) and energy homeostasis. Meanwhile, neuronal survival factors (such as heat-shock and pro-angiogenic proteins) are up-regulated.

Below the second (“anoxic” or “lethal”) threshold, neuronal oxidative metabolism ceases altogether. As well as being electrically silent, the cells are depolarised and distended owing to an influx of Na^+ , Cl^- , Ca^{++} and H_2O and efflux of K^+ and glutamate. Elevated extracellular $[\text{K}^+]$ thus indicates impaired structural integrity of neurons once the lower of the 2 hypo-oxygenation thresholds has been crossed, but both thresholds can then be re-crossed, and electrical activity restored, if normal tissue perfusion is swiftly restored. In the case of formerly-anoxic neurons, however, renewed impulse and synaptic transmission requires prior reinstatement of the resting potential.

Ischemia and oxygenation-based tissue compartments: Arterial

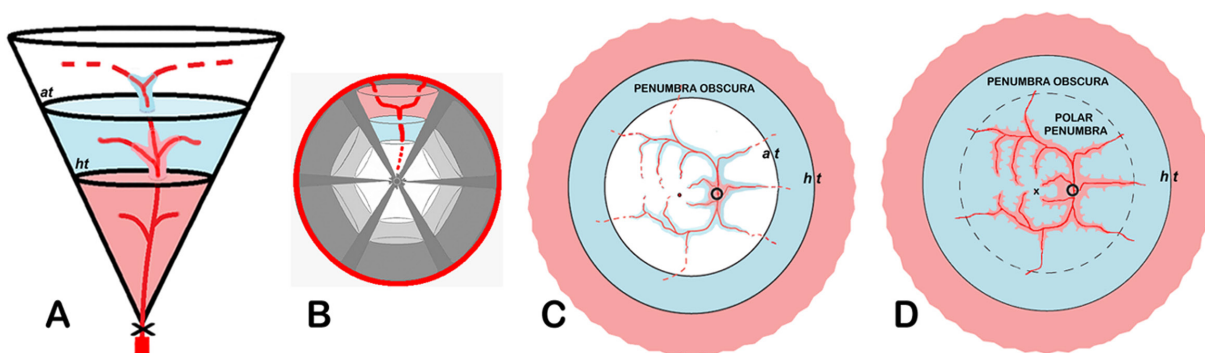


Figure 1 Oxygenation-based tissue compartments (pink = normoxic; blue = hypoxic; unshaded = anoxic).

(A) Hypoperfused 3-D tissue cone after partial occlusion (x) of feeding artery. Ischemic penumbra is intercalated between normoxic (proximal) and anoxic (distal) fields. Note incursions of preferentially-oxygenated peri-arterial cells across planar hypoxic (ht) and anoxic (at) pO_2 thresholds. (B) Anoxic core + hypoxic surround topography assembled from multiple tissue cones each with a reversed compartmental order reflecting distal collateral flow after complete occlusion of feeding artery. (C) En face 2-D topography of “complete” CRAO with minimal residual flow; the reversed compartmental order (anoxic proximally and normoxic distally) reflects graduated collateral oxygenation from the choroid. Concentric pO_2 isobars representing hypoxic (ht) and anoxic (at) thresholds delineate penumbra obscura. O = optic disc; o = cherry-red spot. (D) Diffuse “polar penumbra” in superficial inner retina after “partial” CRAO coalesces with penumbra obscura; middle-retinal compartments are not shown. Normoxic peri-arterial incursions across hypoxic thresholds underlie the formation of “embedded” cotton-wool spots. x = fovea. Figures 1A, C & D are based on illustrations in McLeod and Beatty (2015).

occlusion potentially results in the evolution of 3 oxygenation-based tissue compartments (“normoxic”, “hypoxic” and “anoxic”) within the territory of the vessel. The relative volumes of these compartments depend on the degree of luminal obstruction and the extent of collateral blood flow or other means of collateral oxygenation. The theoretical topography of the compartments arising from such tissue hypoperfusion can be considered in relation to simple sleeves (or cylinders) of cells surrounding individual blood vessels with co-current flow. Here, lethal conditions first affect distal cells located furthest from the axial vessels. These “anoxic corners” of the Krogh tissue cylinders are thought to be separated from proximal normoxic tissue by “hypoxic funnels” of cells (McLeod and Beatty, 2015).

Another geometric oxygenation model comprises a tissue “cone” supplied by the branching architecture of an afferent vessel entering at its apex. Here, incomplete obstruction to arterial inflow potentially results in the establishment of an anoxic tissue compartment in the vessel’s distal field of supply, a normoxic compartment in its proximal field, and an intercalated hypoxic compartment (McLeod and Beatty, 2015). Importantly, the planar hypo-oxygenation thresholds separating these compartments are penetrated by tapering peri-arterial sleeves of cells that are preferentially oxygenated (Figure 1A). A similar spatial pattern follows complete occlusion of the feeding artery but with collateral arterial input from a distal source. Here, however, the retrograde direction of flow reverses the order of tissue compartments (*i.e.*, anoxia in the occluded artery’s proximal field and a normoxic distal field). Unless axons within the apical neuro-vascular bundle somehow remain oxygenated, therefore, complete cortical de-afferentation will ensue even though many of the neuronal somata occupy the hypoxic and normoxic compartments.

Topography of hypo-oxygenated tissue compartments in brain and retina: The classic 3-D topography of cerebral stroke after MCAO comprises a central “core” of ischemic anoxia (primarily involving the basal ganglia) surrounded by hypoxic cortex that is marginally oxygenated by retrograde flow via leptomeningeal arterio-arterial anastomoses on the cerebral surface (Heiss, 2011). This penumbral zone is itself surrounded by normoxic (albeit oligemic) cortex. The “anoxic core + hypoxic surround” (or Type 1) stroke topography represents an aggregation of several hypoperfused tissue cones each with a reversed compartmental order (Figure 1B). This is often portrayed in 2-D as a “fried egg” topography with no acknowledgement of incursions by preferentially-oxygenated neurons. Hypoxic peri-arterial incursions across anoxic thresholds may underlie the “archipelago” (or Type 2) stroke topography described as “penumbra embedded within core” (Olivot et al., 2009).

Chronic retinal hypoxia has long been known to stimulate intraocular angiogenesis (Michaelson, 1948; Hayreh, 2011), but the ophthalmic scientific lexicon seldom includes the term “ischemic penumbra”. Recently, however, legacy experiments (1968–2004) in macaques, wherein the intra-orbital central retinal artery (CRA) was temporarily occluded, have

been re-visited (McLeod and Beatty, 2015). The b-wave of the electroretinogram (ERG), which is largely generated by bipolar cells located within the middle-retinal portion of the vascularised inner retina, is unsurprisingly “silenced” by CRA occlusion (CRAO) apart, that is, from a residual b-wave that is larger in response to full-field or “Ganzfeld” stimulation (averaging 41% of the pre-CRAO amplitude) in comparison with non-Ganzfeld stimulation ($\approx 10\%$). This suggests that normoxic middle-retinal tissue occupies a substantial area of the retinal periphery during CRAO. Moreover, on unclamping the CRA after, say, an hour of ischemia, responses to Ganzfeld stimulation increase from 41% to 68% of the pre-CRAO b-wave within 10 minutes. This “rapid-recovery component” (27%) indicates that a hypoxic middle-retinal tissue compartment, comprising electrically-silent but polarised bipolar cells, occupies the retinal mid-periphery during CRAO. The remaining 32% of the pre-CRAO b-wave recovers more slowly after transient CRAO presumably because, having temporarily lost their structural integrity, formerly-anoxic bipolar cells need time to repolarize before their electrical activities are reinstated. Full recovery of the visual evoked potential (VEP), signifying re-oxygenation of the superficial inner retina and cortical re-afferentation, is similarly protracted.

The *en-face* 2-D topography of complete CRAO thus comprises an anoxic “core” (visible ophthalmoscopically as a circular zone of initially-reversible retinal opacification $\approx 30^\circ$ in radius with a foveolar cherry-red spot at its center) plus a mid-peripheral “surround” of similarly electrically-silent, but transparent, inner retina. The concentric swathe of hypoxic neurons (or “penumbra obscura”) is itself surrounded by normoxic peripheral retina (Figure 1C). Of course, there are no distal arterio-arterial collaterals available after CRAO, unlike after MCAO. Nevertheless, the choroid, which is the ocular equivalent of the cerebral leptomeninges, acts like a large thin-walled artery (with a high blood volume flow, a low OEF and a high intravascular pO_2 throughout its extent) in offering a potential collateral source of oxygenation to the non-perfused inner retina (McLeod and Beatty, 2015). In the posterior pole, however, inward diffusion of oxygen is precluded by the oxygen sink or “metabolic oxygen barrier” presented by mitochondria within densely-packed, highly-energetic photoreceptors. By contrast, the mid-peripheral inner retina can be marginally oxygenated by the choroid because rod photoreceptor cell density diminishes with increasing eccentricity from the fovea beyond 20° . The annular hypoxic compartment lies between the roughly circular pO_2 isobar at $\approx 30^\circ$ eccentricity (*i.e.*, the anoxic threshold) and another at $\approx 55^\circ$ eccentricity (*i.e.*, the hypoxic or penumbra threshold). The outlines of these inner retinal pO_2 thresholds, reflecting the graduated centrifugal diminution in photoreceptor cell density, show no threshold incursions.

Normoxic peri-arterial incursions across hypoxic thresholds (Figure 1A) are a characteristic feature of the clinical picture that evolves following “partial” CRAO. Here, misery perfusion (as witnessed by retinal venous hypoxemia) is associated with heterogeneous macular retinal opacification that reflects considerable heterogeneity in tissue pO_2 values (Oji and McLeod,

1978). Densely opaque cotton-wool spots (CWSs) appear along the posterior boundary of a (transparent) “polar penumbra” involving most of the superficial inner retina in the posterior pole. These white sentinels result from ischemic obstruction of retrograde axoplasmic transport in the retinal nerve-fibre layer (NFL), and some of them become “embedded” within the penumbral zone courtesy of continuing mitochondrial transportation within tapering zones of peri-arterial normoxia (**Figure 1D**). The pathophysiology of embedded CWSs adds to the substantial body of evidence challenging the almost universal misapprehension that retinal CWSs represent “NFL infarcts” (McLeod and Beatty, 2015). Meanwhile, in the middle retinal layers posteriorly, subtle peri-venous opacification signifies “anoxic corner” formation owing to reduced counter-current blood flow within the interdigitating arteries and veins that radiate around the fovea. The localised anoxic damage reflects the exaggerated vulnerability to hypoperfusion extant within the distal portion of the vascular path.

Time-course of cerebral and inner retinal ischemic change:

Unlike the spatial similarities noted above, temporal aspects of ischemic neuropathology differ significantly between brain and retina. The “survival time” of cerebral neurons is believed to be ≈ 30 –40 minutes following MCAO before oncotic infarction ensues. However, the hypoxic cortical neurons surrounding the anoxic core maintain their viability for 1–6 hours before self-destructing *via* the apoptotic cell-death pathway, albeit often leaving a residual “cap” of penumbral cortex (Slevin et al., 2006). The “penumbra-to-umbra conversion” results from wave after wave of peri-infarct depolarisation, perhaps due to excessive extracellular $[K^+]$ emanating from the infarct core. Such depolarisations impose intolerable energetic demands on the hypo-oxygenated cells as they attempt to re-establish ionic homeostasis (Heiss, 2011). Hyperacute interventions for stroke (including fibrinolytic arterial recanalisation) aim to salvage a significant volume of penumbral cortex.

As already noted, diffusely-opacified posterior retina can regain its transparency, and the ERG and VEP will recover fully, provided inner retinal perfusion is restored within 100 minutes or so of CRA clamping (Hayreh, 2011). Once the anoxia survival time expires, however, retinal opacification does not reverse until tissue atrophy occurs 1–2 weeks later, and the VEP and 32% of the ERG b-wave (corresponding to the slow component of the biphasic ERG b-wave recovery seen following transient CRAO) are irreversibly extinguished (McLeod and Beatty, 2015). Nevertheless, even after CRA clamping for several hours, the rapid component of b-wave recovery (27%) persists. This indicates that penumbral tissue in the retinal mid-periphery does not undergo delayed apoptotic infarction, perhaps because excess K^+ is siphoned into the vitreous. Experimental CRAO might therefore be an appropriate model for studying penumbral neurogenesis uncomplicated by peri-infarct depolarisations (Slevin et al., 2006; Ramos-Cabrera et al., 2011). In clinical practice, there is little urgency in trying to re-establish inner retinal perfusion once the duration of

CRAO exceeds 2 hours.

Endurance of the penumbra obscura (with continuing secretion of pro-angiogenic proteins) is also reflected in the progression to severe intraocular angiogenesis seen in those 15–20% of eyes with clinical CRAO in which the retina remains non-perfused. The angiogenic drive from the hypo-oxygenated mid-peripheral retina perpetuates because, unlike neovascularisation within cerebral cortex or elsewhere, penumbral retina does not become re-vascularised. This can probably be explained by the accumulation of pro-angiogenic molecules within the vitreous extracellular matrix rather than the neuropile. In consequence, angiogenesis within the eye is not self-limiting in nature.

Presented in part as the Zivojnovic Lifetime Achievement Award Lecture, European Vitreo-Retinal Society, Venice, 2015.

David McLeod*

Academic Department, Manchester Royal Eye Hospital and University of Manchester Centre for Ophthalmology & Vision Research, Manchester, UK

*Correspondence to: David McLeod, Professor Emeritus, david.mcleod@nhs.net.

Accepted: 2016-03-21

orcid: 0000-0002-4433-2088 (David McLeod)

doi: 10.4103/1673-5374.181367 <http://www.nrronline.org/>

How to cite this article: McLeod D (2016) Ischemic penumbra in retina endures: vascular neuropathology is reconciled. *Neural Regen Res* 11(5):737-739.

References

- Astrup J, Symon L, Branston NM, Lassen NA (1977) Cortical evoked potential and extracellular K^+ and H^+ at critical levels of brain ischemia. *Stroke* 8:51-57.
- Hayreh SS (2011) Acute retinal arterial occlusive disorders. *Prog Retin Eye Res* 30:359-394.
- Heiss WD (2011) The ischemic penumbra: correlates in imaging and implications for treatment of ischemic stroke. *The Johann Jacob Wepfer award* 2011. *Cerebrovasc Dis* 32:307-320.
- McLeod D, Beatty S (2015) Evidence for an enduring ischaemic penumbra following central retinal artery occlusion, with implications for fibrinolytic therapy. *Prog Retin Eye Res* 49:82-119.
- Michaelson IC (1948) The mode of development of the vascular system of the retina, with some observations on its significance for certain retinal diseases. *Trans Ophthalmol Soc UK* 68:137-180.
- Oji EO, McLeod D (1978) Partial central retinal artery occlusion. *Trans Ophthalmol Soc UK* 98:156-159.
- Olivot JM, Mlynash M, Thijs VN, Purushotham A, Kemp S, Lansberg MG, Wechsler L, Gold GE, Bammer R, Marks MP, Albers GW (2009) Geography, structure, and evolution of diffusion and perfusion lesions in Diffusion and perfusion imaging Evaluation For Understanding Stroke Evolution (DEFUSE). *Stroke* 40:3245-3251.
- Ramos-Cabrera P, Campos F, Sobrino T, Castillo J (2011) Targeting the ischemic penumbra. *Stroke* 42:S7-S11.
- Slevin M, Kumar P, Gaffney J, Kumar S, Krupinski J (2006) Can angiogenesis be exploited to improve stroke outcome? Mechanisms and therapeutic potential. *Clin Sci (Lond)* 111:171-183.