



Andrology and fertility

## Three's a crowd: A very rare form of polyorchidism with sertoli cell adenomas

James Roy<sup>a,\*</sup>, James Hunt<sup>b</sup>, Hazel Ecclestone<sup>a</sup>, James Johnston<sup>a</sup><sup>a</sup> Taranaki Base Hospital, Taranaki District Health Board, 23 David Street, New Plymouth, New Zealand<sup>b</sup> Taranaki Pathology Services, 56 Vivian Street, New Plymouth, New Zealand

## ARTICLE INFO

## Keywords:

Polyorchidism  
 Congenital anomalies  
 Orchialgia  
 Sertoli cell adenoma

## ABSTRACT

Polyorchidism is rare with fewer than 200 cases reported in literature. We present a case of a 26 year old male with chronic pain secondary to a very rare form of polyorchidism, with histology showing Sertoli cell adenomas. Orchiectomy should be considered in patients with chronic pain due to polyorchidism.

## Introduction

Polyorchidism is the rare congenital presence of more than 2 testicles. We present a case of a 26 year old male who underwent inguinal orchidectomy for persistent orchialgia due to complete duplication of the right testicle.

## Case report

A 26 year old male presented 15 months prior with an acute exacerbation of chronic intermittent right hemiscrotal pain, with ultrasound scan (USS) showing a bilobed testicle with normal Doppler flow. Given the patient had ongoing pain, he proceeded to scrotal exploration and bilateral orchidopexy for suspected intermittent testicular torsion. 10 months later the patient was seen in outpatient clinic with persisting right hemiscrotal pain, and the right testicle was noted to be significantly smaller compared to previous examination with concerns for chronic ischaemia and subsequent atrophy. A repeat USS showed vascularity in both right testicular moieties but reduced and heterogeneous echotexture of the smaller lobe (Fig. 1). The right testicle was smaller again on serial examination four weeks later.

Given suspected ongoing chronic ischaemia, the patient proceeded to

an uncomplicated right inguinal orchiectomy. Histology was reported as complete polyorchidism, with each testis having a separate epididymis and vas deferens (Fig. 2). Both testicles displayed tubular atrophy and diminished spermatogenesis, as well as single Sertoli cell adenomas (Fig. 3).

There was no evidence of malignancy. During a phone review 4 weeks post-operatively, the patient reported his right hemiscrotal pain had resolved.

## Discussion

Polyorchidism is exceedingly rare with under 200 cases reported.<sup>1</sup> It is believed to arise from abnormal division of the genital ridge during embryological development, with the resultant subtype dependent on where this division occurs.<sup>1</sup> Leung devised 4 subtypes based on the anatomy of the supernumerary testis.<sup>2</sup> In type A, the supernumerary testis has no epididymis or vas deferens, and therefore no reproductive potential. Type B shares the ipsilateral testicle's epididymis and vas deferens, and type C has its own epididymis but shares the vas deferens with the ipsilateral testis. Type D describes our patient and is extremely rare. The supernumerary testis has its own epididymis and vas deferens separate to that of the ipsilateral testis, and results from complete

\* Corresponding author.

E-mail addresses: [james.roy@tdhb.org.nz](mailto:james.roy@tdhb.org.nz) (J. Roy), [james.hunt@taranakipath.co.nz](mailto:james.hunt@taranakipath.co.nz) (J. Hunt), [hazel.ecclestone@tdhb.org.nz](mailto:hazel.ecclestone@tdhb.org.nz) (H. Ecclestone), [james.johnston@tdhb.org.nz](mailto:james.johnston@tdhb.org.nz) (J. Johnston).

<https://doi.org/10.1016/j.eucr.2020.101512>

Received 23 November 2020; Received in revised form 25 November 2020; Accepted 28 November 2020

Available online 30 November 2020

2214-4420/© 2020 The Authors.

Published by Elsevier Inc.

This is an open access article under the CC BY-NC-ND license

(<http://creativecommons.org/licenses/by-nc-nd/4.0/>).

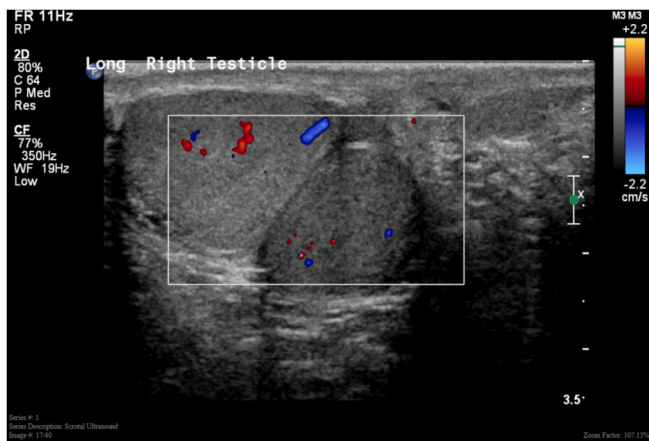

Fig. 1. Scrotal USS showing ipsilateral and supernumerary right testes.

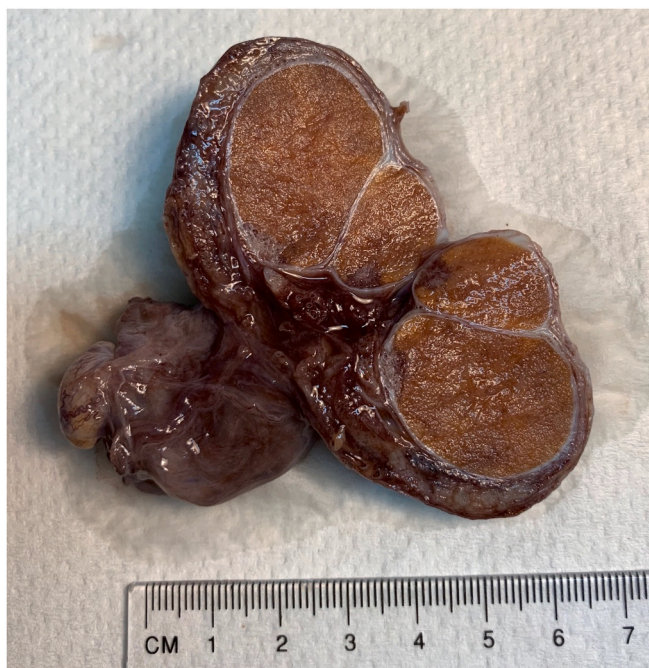


Fig. 2. Macroscopic dissection specimen showing right polyorchidism.

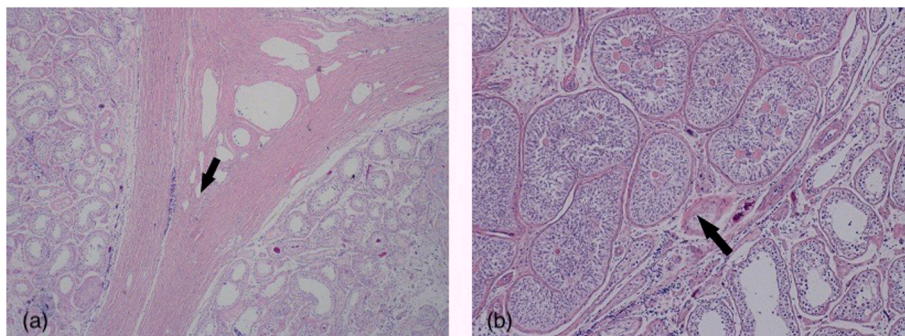


Fig. 3. (a) Histology showing fused tunica albuginea (arrow) with testis either side. (b) Histology showing Sertoli cell/Pick's adenoma (arrow).

longitudinal duplication of the genital ridge and mesonephric duct. This case is even more rare because only 25% of polyorchidism cases occur on the right side.<sup>2</sup>

Most cases are incidental however some can present with pain or a palpable testicular lump. Associated pathologies include inguinal hernia, cryptorchidism, testicular torsion, hydrocele, hypospadias and testicular cancer.<sup>3</sup> The location of the supernumerary testis can be scrotal, inguinal or retroperitoneal.

Debate exists on best management of this condition. If the supernumerary testis has no reproductive potential, then it should be surgically removed due to increased risk of malignancy. With advances in medical imaging such as magnetic resonance imaging (MRI), a supernumerary testis with reproductive potential can be followed up closely with a non-operative approach to preserve fertility. Orchiectomy however is the standard of care if the location is not scrotal.<sup>3</sup>

Sertoli cell neoplasms account for only 1% of testicular neoplasms, with the minority being malignant. Sertoli cell or Pick's adenomas are unencapsulated, benign hyperplastic lesions of immature Sertoli cells and are commonly but not always encountered in undescended testes.<sup>4</sup> They are usually an incidental finding and rarely present as a testicular mass. There is no documented association between polyorchidism and these benign lesions, and the patient had no history of cryptorchidism, however the atrophic nature of the patient's testes may explain their presence.

Clinical relevance to this case could apply in the setting of a failed vasectomy. If polyorchidism with duplication of the epididymis and vas deferens is present but unknown, then only dividing one vas would result in the supernumerary testis still being able to produce sperm in the ejaculate. Although a rare condition, there could potentially be a role for routine scrotal USS in vasectomy failure.

**Conclusion**

Polyorchidism is a rare condition and should be included in the differential diagnosis of a testicular mass. Persisting pain in the setting of this condition should prompt the clinician to suspect chronic ischaemia and consider orchiectomy for symptomatic relief. The presence of Sertoli cell adenomas in this condition may be the result of testicular atrophy.

**Consent**

Verbal and written consent was obtained from the patient involved in this case for specific details of his case to be documented and published.

### Declaration of competing interest

There are no conflicts of interest to declare.

### References

1. Di Cosmo G, Silvestri T, Bucci S, Bertolotto M, Trombetta C. A singular case of polyorchidism. *Archivio Italiano di Urologia, Andrologia: organo Ufficiale [di] Societa Italiana di Ecografia. Urologica e Nefrologica*. 2016;88(4):333–334.
2. Leung AK. Polyorchidism. *Am Fam Physician*. 1988;38:153–156.
3. Bergholz R, Wenke K. Polyorchidism: a meta-analysis. *J Urol*. 2009;182(5):2422–2427.
4. Barghorn A, Alioth HR, Hailemariam S, Bannwart F, Ulbright TM. Giant Sertoli cell nodule of the testis: distinction from other Sertoli cell lesions. *J Clin Pathol*. 2006;59(11):1223–1225.