

## An uncommon cause of dysphagia

Manickavasagam Senthilraja<sup>1</sup>, Remya Rajan<sup>1</sup>, Nitin Kapoor<sup>1</sup>,  
Thomas Vizhalil Paul<sup>1</sup>, Kripa Elizabeth Cherian<sup>1</sup>

<sup>1</sup>Department of Endocrinology, Diabetes and Metabolism, Christian Medical College and Hospital, Vellore, Tamil Nadu, India

### ABSTRACT

Lingual thyroid is an abnormal mass of ectopic thyroid tissue seen in the base of tongue caused due to aberrant embryological development. It is often asymptomatic but may cause local symptoms, such as dysphagia, dysphonia, and upper airway obstruction. In this case, we report a 13-year-old girl who presented with dysphagia and breathing difficulty. Local examination revealed thyroid tissue in the posterior aspect of the tongue. Thyroid scintigraphy showed abnormal tracer uptake at base of tongue. Hormonal test showed subclinical hypothyroidism. She was treated with Levothyroxine.

**Keywords:** Dysphagia, lingual thyroid, Tc-99m scintigraphy

### Case Report

A 13-year-old girl presented to her primary care physician with complaints of difficulty in swallowing and breathing since 5 months. She experienced dysphagia equally with foods of solid or liquid consistency. The symptoms were nonprogressive, and these were managed conservatively. She was referred to our center for further evaluation. On further enquiry, she did not have any constitutional symptoms in the form of weight loss or prolonged fever. There was no history of sore throat or cough. There was no history of an underlying connective tissue disease. She did not have symptoms suggestive of hypothyroidism. On examination, she was found to have a small mass in the midline at the base of her tongue [Figure 1]. Examination of the neck revealed no palpable thyroid gland in the normal pretracheal position. Thyroid scintigraphy with technetium (Tc-99 m) showed abnormal tracer uptake in an ectopic location at the base of tongue and no uptake in the thyroid bed [Figure 2]. Biochemical evaluation showed subclinical hypothyroidism with TSH of 12.1  $\mu$ IU/mL (N: 0.3–4.5  $\mu$ IU/mL) with total T4 of 6.8  $\mu$ g/dL (N: 4.5–12.5  $\mu$ g/dL), and free T4 of 1.0 ng/dL (N: 0.8–2.0 ng/dL).

**Address for correspondence:** Dr. Kripa Elizabeth Cherian, Department of Endocrinology, Christian Medical College and Hospital, Vellore - 632 004, Tamil Nadu, India.  
E-mail: kripaec@gmail.com

She was started on Levothyroxine 25  $\mu$ g/day and has been asked to follow up after 6 months.

### Discussion

The thyroid tissue migrates caudally from the foramen cecum at the base of tongue and reaches the normal location in the pretracheal region at the seventh week of fetal life.<sup>[1]</sup> If thyroid tissue fails to migrate, it can result in ectopic thyroid tissue. Ectopic thyroid tissue may be found anywhere along the line of the obliterated thyroglossal duct, usually from the base of the tongue to the mediastinum. Lingual thyroid is the most common type of ectopic thyroid, accounting for 90% of cases, whereas sublingual, thyroglossal, laryngotracheal, and lateral cervical types are less frequently encountered.<sup>[2]</sup> Thyroid tissue can also be found, extremely rarely, in remote structures that were associated with the thyroid anlage during development, including the esophagus, mediastinum, heart, aorta, adrenal, pancreas, gallbladder, and skin.

A normally located thyroid is not seen in 70% of patients with lingual thyroid.<sup>[3]</sup> Ectopic thyroid tissue can be the only functional thyroid tissue. Rarely, the lingual thyroid may cause hyperthyroidism<sup>[4]</sup> or it may be the site of thyroid cancer.<sup>[5]</sup>

This is an open access journal, and articles are distributed under the terms of the Creative Commons Attribution-NonCommercial-ShareAlike 4.0 License, which allows others to remix, tweak, and build upon the work non-commercially, as long as appropriate credit is given and the new creations are licensed under the identical terms.

**For reprints contact:** reprints@medknow.com

**How to cite this article:** Senthilraja M, Rajan R, Kapoor N, Paul TV, Cherian KE. An uncommon cause of dysphagia. J Family Med Prim Care 2019;8:1282-3.

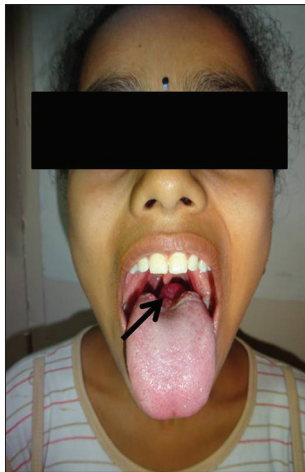#### Access this article online

##### Quick Response Code:



**Website:**  
www.jfmipc.com

**DOI:**  
10.4103/jfmipc.jfmipc\_2\_19



**Figure 1:** Thyroid tissue seen at the posterior aspect of tongue

During puberty, lingual thyroid can increase in size and cause obstructive symptoms.

Asymptomatic cases can be monitored with suppressive hormonal therapy aiming for reduction of ectopic tissue volume.<sup>[6]</sup> Effective treatment for lingual thyroid is surgical excision, but no surgical treatment should be attempted until radioactive isotope scan has determined that there is an adequate thyroid tissue in the neck. Surgical indications are intractable dyspnea, dysphagia, suspicion of malignancy, uncontrolled hyperthyroidism, and repetitive or severe bleeding.<sup>[7]</sup>

The differential diagnosis for lingual thyroid should include vascular tumors, telangiectatic granuloma, teratomas, and benign or malignant swelling in the posterior region of the tongue.<sup>[8]</sup>

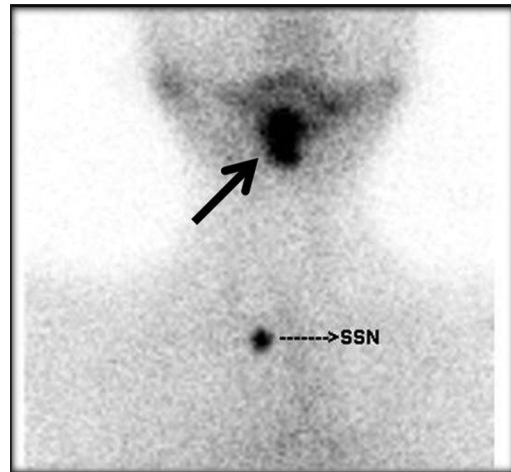
Although our patient's initial complaints had been that of dysphagia, she had been asymptomatic at the time of presentation to us. However, the occurrence of dysphagia, especially in the setting of primary care, mandates a thorough local physical examination. This will assist in detecting local causes for the same and appropriate referral to a higher center for further management.

### Conclusion

Rarely, lingual thyroid may present with dysphagia. When a mass lesion is seen at the base of the tongue, ectopic lingual thyroid should be considered in the differential diagnosis, and the diagnosis must be verified using ultrasonography, and Tc-99 m thyroid scintigraphy.

### Declaration of patient consent

The authors certify that they have obtained all appropriate patient consent forms. In the form the patient(s) has/have given his/her/their consent for his/her/their images and other clinical information to be reported in the journal. The patients



**Figure 2:** Technetium-99m thyroid scan showing abnormal tracer uptake at base of tongue suggestive of ectopic lingual thyroid

understand that their names and initials will not be published and due efforts will be made to conceal their identity, but anonymity cannot be guaranteed.

### Acknowledgements

The authors would like to thank Dr Mary John, for the professional help rendered in patient care.

### Financial support and sponsorship

Nil.

### Conflicts of interest

There are no conflicts of interest.

### References

1. Toso A, Colombani F, Averono G, Aluffi P, Pia F. Lingual thyroid causing dysphagia and dyspnoea. Case reports and review of the literature. *Acta Otorhinolaryngol Ital* 2009;29:213-7.
2. Sauk JJ. Ectopic lingual thyroid. *J Pathol* 1970;102:239-43.
3. Babademez MA, Günbey E, Acar B, Günbey HP. A rare cause of obstructive sleep apnea syndrome: Lingual thyroid. *Sleep Breath Schlaf Atm* 2012;16:305-8.
4. Abdallah-Matta MP, Dubarry PH, Pessey JJ, Caron P. Lingual thyroid and hyperthyroidism: A new case and review of the literature. *J Endocrinol Invest* 2002;25:264-7.
5. Massine RE, Durning SJ, Koroscil TM. Lingual thyroid carcinoma: A case report and review of the literature. *Thyroid* 2001;11:1191-6.
6. Huang TS, Chen HY. Dual thyroid ectopia with a normally located pretracheal thyroid gland: Case report and literature review. *Head Neck* 2007;29:885-8.
7. Kumar SS, Kumar DM, Thirunavukuarasu R. Lingual thyroid-conservative management or surgery? A case report. *Indian J Surg* 2013;75(Suppl 1):118-9.
8. Koch CA, Picken C, Clement SC, Azumi N, Sarlis NJ. Ectopic lingual thyroid: An otolaryngologic emergency beyond childhood. *Thyroid* 2000;10:511-4.