

The Combined Use of Tocilizumab and Hemoadsorption in a Patient with SARS-COV-2-19-Associated Pneumonia: A Case Report

Giorgio Berlot^a Ariella Tomasini^a Erik Roman Pognuz^a Anna Randino^a
Fabrizio Chiella^a Cristina La Fata^a Marco Piva^a Paola Amato^a
Vittorio di Maso^b Francesco Bianco^b Ugo Gerini^b Paola Tomietto^c
Tommaso Trenti^d

^aDepartment of Anesthesia and Intensive Care Medicine, Cattinara Hospital, Azienda Sanitaria Universitaria Giuliano-Isontina (ASUGI), Trieste, Italy; ^bDepartment of Nephrology, Cattinara Hospital, Azienda Sanitaria Universitaria Giuliano-Isontina (ASUGI), Trieste, Italy; ^cDepartment of Internal Medicine, Cattinara Hospital, Azienda Sanitaria Universitaria Giuliano-Isontina (ASUGI), Trieste, Italy; ^dDepartment of Laboratory Medicine and Pathological Anatomy, Azienda Ospedaliera Universitaria e Azienda USL di Modena, Modena, Italy

Keywords

SARS-COV-2-19 · Tocilizumab · CytoSorb · Interleukin 6 · C-reactive protein.

Abstract

The SARS-COV-2-19-associated respiratory involvement is caused by the massive release of inflammatory cytokines ultimately leading to interstitial pneumonia and acute respiratory distress syndrome (ARDS). In the absence of an effective antiviral treatment, a reasonable causal approach could be constituted by the neutralization of these substances. The authors describe the clinical course of a patient with SARS-COV-2-19 interstitial pneumonia treated with the combination of an anti-interleukin 6 (IL-6) agent (tocilizumab) and hemoadsorption (HA). This combination was used to abate the surge of inflammatory mediators leading to the lung damage. Blood levels of IL-6 and C-reactive protein (CRP) were measured before the initiation of the treatment and in the following 3 days. At the end of the treatment, the values of IL-6 and CRP decreased from 1,040 to 415 pg/mL and from

229 to 59 mg/L, respectively. The gas exchanges and the chest imaging rapidly improved, and the patient was extubated 10 days later. The combination of tocilizumab and HA could be valuable in the treatment of SARS-COV-2-19-associated pneumonia and ARDS that are caused by the release of inflammatory mediators.

© 2020 S. Karger AG, Basel

Background

Since the beginning of February 2020, an outbreak of a novel coronavirus disease (SARS-COV-2-19) spread all over Italy [1]. Similarly to what has been reported in epidemics caused by other strains of coronavirus and H1N1 influenza virus, it appears that a massive release of inflammatory mediators, including tumor necrosis factor, several pro-inflammatory mediators, including interleukin (IL)-1, IL-2, IL-6, interferon, etc. could be responsible for the endothelial and alveolar damage ultimately leading to the severe hypoxia and multiple organ dysfunction

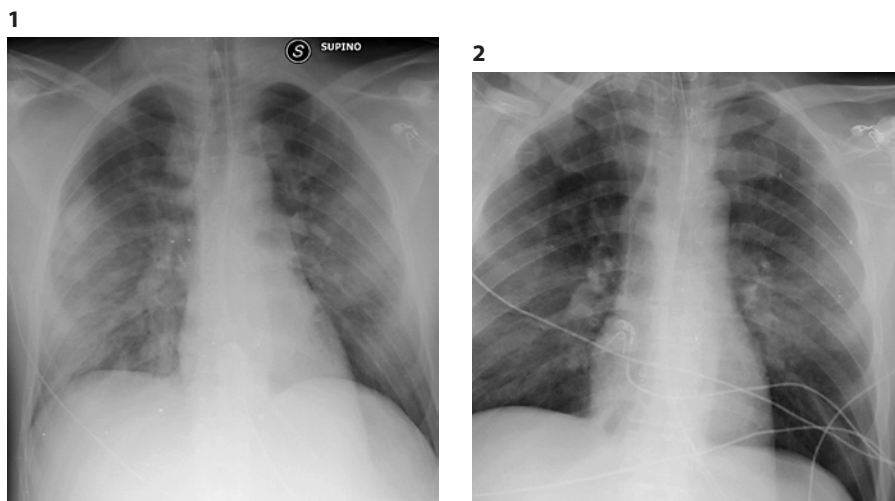


Fig. 1. Admission CRX: bilateral multiple confluent opacities. CRX, chest radiograph.

Fig. 2. One day after the end of treatment with CytoSorb® and tocilizumab. Bilateral reduction of the opacities.

syndrome occurring in these patients [2, 3], making them prone also to infections with other germs and viruses [4]. A similar reaction, frequently indicated as cytokine release syndrome can occur also in a number of critical conditions other than sepsis, including hemophagocytic syndrome (HS), onset of adult Still's disease and untoward reactions to innovative therapies aiming to enhance the host's immune response against the tumor cells [5–7].

Aiming to contrast this hyperinflammatory response, we combined hemoadsorption (HA) and the anti-IL-6 agent tocilizumab in a patient with a SARS-CoV-2-19 severe interstitial pneumonia. To the best of our knowledge, no other similar case has been reported so far.

Case Description

A 40-year-old man with an uneventful history was admitted to our ICU due to a severe respiratory failure caused by SARS-CoV-2 that was diagnosed from the pharyngeal swab. The chest radiograph (CRX) demonstrated multiple bilateral opacities (Fig. 1). He was mechanically ventilated with an FIO₂ of 100% and a PEEP of 10 cm of H₂O; the initial PaO₂/FIO₂ was 80 but increased up to 245 with recruitment maneuvers. The C-reactive protein (CRP) was elevated, but other biochemistries, including the procalcitonin were in the normal range (Table 1). An antiviral treatment with lopinavir/ritonavir was started. Due to the elevated inflammatory pattern, HA was initiated simultaneously with the iv. Anti-IL-6 tocilizumab was administered at a dosage of 8 mg/kg and repeated after 24 h. HA was performed with a CytoSorb® (CytoSorbents Corporation, Monmouth Junction, NJ, USA; Aferetica s. r.l. Bologna Italy) using a femoral bi-lumen catheter; the anticoagulation was obtained with a continuous infusion of iv. Heparin was titrated according to the APTT; 3 sessions of CytoSorb® were performed, each lasting 24 h; the procedure was performed in the hemoperfusion mode, as the patient did not need any renal replacement treatment. The blood levels of IL-6 and CRP were mea-

Table 1. Time course of some inflammatory and respiratory variables

Variable ^a (normal values)	Interventions			
	Tmab + HA D1	Tmab + HA D2	HA D3	none D4
PaO ₂ /FIO ₂	132	200	220	315
CRP (<5.0 mg/L)	229	180	129	59
PCT (<0.5 ng/mL)	<0.5	<0.5	<0.5	<0.5
IL-6 (0–10 pg/mL)	1,040	953	487	415

HA, hemoadsorption; Tmab, tocilizumab; IL, interleukin; CRP, C-reactive protein; PCT, procalcitonin. ^a All blood samples were obtained before the initiation of HA and Tmab.

sured before the initiation of HA and tocilizumab and in the following 4 days (D1–D4, respectively) (Table 1). Both substances were measured with commercially available kits.

Twenty-four hours after the start of the treatment, the PaO₂/FIO₂ increased to 341. At the end of the combined procedures, the CRX was substantially improved (Fig. 2) and 10 days after admission, the patient was extubated and discharged to a sub-ICU. SARS-CoV-2 was no longer present in the bronchoalveolar lavage. Ten days after the discharge from ICU, he left the hospital and returned home free of symptoms, and 1 month later, he called us over phone and announced that he became father of a girl.

Discussion

In the absence of effective antiviral treatments, the approach to patients with SARS-CoV-2-19 acute respiratory distress syndrome (ARDS) remains largely supportive and includes the use of protective mechanical ventila-

tion, high PEEP, and prone position; in a small rate of patients, these measures fail to increase blood oxygenation and an extracorporeal membrane oxygenation is warranted. Since the lung tissue damage appears to be caused by the action of pro-inflammatory mediators released during the virus-host interaction, their abatement could be valuable. With this aim, we treated the described patient with a dual approach, taking advantage of the IL-6-blocking action exerted by the tocilizumab as well as of the CytoSorb[®]. The former is an anti-IL-6 receptor chimeric antibody primarily used in the treatment of rheumatoid arthritis, whereas the latter consists in a cartridge containing a hemocompatible macroporous sorbent-polystyrene divinylbenzene copolymer beads covered with PVP – polyvinylpyrrolidone polymeric beads – with a total surface area of more than 40.000 m², designed to remove from the blood a broad spectrum of hydrophobic molecules with a molecular weight of up to approximately 60 kDa, including cytokines and other inflammatory mediators that could lead to uncontrolled systemic inflammation and organ failure [7, 8]. The CytoSorb[®] can be used as a stand-alone treatment or in combination with a renal replacement treatment or an extracorporeal membrane oxygenation circuit. Some experimental and clinical investigations demonstrated that the use of CytoSorb[®] is associated both with the reduction of blood levels of many inflammatory cytokines and with the improved survival of patients with septic shock [9, 10]. Notably, tocilizumab is not removed by the CytoSorb[®] due to its elevated molecular weight [11].

Our decision was inspired by a case recently described by Bottari et al. [10] who successfully treated with the same approach a cytokine release syndrome occurring in a young patient treated with chimeric antigen-receptor modified T-cells and observed the decrease of different markers of inflammation (including IL-6, IL-10, and ferritin) occurring along with the improvement of the gas exchange and of the CRX. In our patient, the decrease of IL-6 and CRP were associated to similar improvements, possibly indicating that the combination of tocilizumab and HA could be valuable for the treatment of SARS-CoV-2-associated interstitial pneumonia or ARDS, likely due to the decrease of the bulk of circulating inflammatory mediators determined by their use.

Yet, 2 relevant points need clarification. First, which patient could take advantage from this treatment? Actually, as the rapid measurement of blood levels of IL-6 as well as of other mediators is not readily available in Italy, other markers are warranted. Recently, Mehta et al. [12] suggested the HS score to screen SARS-COV-2-19 pa-

tients with a hyperinflammatory response and, thus, eligible for immunomodulatory treatment. This system has been developed by Fardet et al. [13] to assess the individual risk of reactive HS in patients with septic shock and is based on the measurement of 22 variables whose derangement is ranked according to the deviation from their normal values; however, it requires some information that can be either difficult to gather in SARS-COV-2-19 patients, such as the presence of hemophagocytosis in the bone marrow aspirate or not directly related to the SARS-COV-2-19 such as the hepatomegaly or the splenomegaly. A more practical approach could be constituted by the repeated measurements of the CRP as this acute-phase reactant is produced under the stimulation of the IL-6 [14]. Put in other terms, the CRP could be considered as a proxy of IL-6, and its elevation could prompt the initiation of the tocilizumab and HA therapies. Actually, in the absence of readily available markers of inflammation, Ronco et al. [15] advocate the unspecific blockade of the cytokine surge by means of CytoSorb[®] or other similar techniques.

Second, it is not (yet) clear if and in which amount the antiviral agents are inactivated by the HA. Although the efficacy of lopinavir/ritonavir is questionable [16], this issue is particularly relevant in view of other agents currently under investigation [17] because the measurement of their circulating levels and the consequent adjustment of dosage is not yet available everywhere.

Conclusions

In our experience, the combined use of CytoSorb[®] and tocilizumab was followed by the rapid improvement of the gas exchange and CRX in a patient with SARS-COV-2-19 pneumonia. These variations were associated with a sharp decrease of CRP and IL-6 whose levels remained low even on the day after the end of the treatment. We suggest considering the use of the combined approach of CytoSorb[®] and tocilizumab in patients with SARS-COV-2-19-induced pneumonia, ARDS, and/or multiple organ dysfunction syndrome with elevated levels of CRP.

Acknowledgements

The authors are deeply grateful to the nursing and administrative staff of the Trieste ICU.

Statement of Ethics

Not applicable; the patient gave the authorization to the publication of his case in anonymous form.

Conflict of Interest Statement

The authors have non conflicts of interest to declare.

Funding Sources

The authors did not receive any funding.

Author Contributions

G.B. and A.T. wrote the manuscript whose final version was approved by all the authors; E.R.-P., A.R., F.C., C.L.F., M.P., P.A., V.d.M., F.B., U.G., and P.T. actively participated in the treatment of the described patient; and T.T. measured the blood levels of IL-6.

References

- 1 Remuzzi A, Remuzzi G. COVID-19 and Italy: what next? *Lancet*. 2020;395(10231):1225–8.
- 2 Li X, Geng M, Peng Y, Meng L, Su S. Molecular immune pathogenesis and diagnosis of SARS-COV-2 -19. *J Pharm Anal*. 2020;10(2):102–8.
- 3 Jensen JA, Sjastaad FV, Griffith TS, Badovinar VP. Sepsis-induced T cell immunoparalysis: the ins and outs of impaired T cell immunity. *J Immunol*. 2018;200:1543–53.
- 4 Wang T, Du Z, Zhu F, Cao Z, An Y, Gao Y, et al. Comorbidities and multi-organ injuries in the treatment of COVID-19. *Lancet*. 2020 Mar 21;395(10228):e52.
- 5 Beutel G, Wiesner O, Eder M, Hafer C, Schneider AS, Kielstein JT, et al. Virus-associated hemophagocytic syndrome as a major contributor to death in patients with 2009 influenza A (H1N1) infection. *Crit Care*. 2011;15(2):R80.
- 6 Kyriazopoulou E, Leventogiannis K, Norrby-Teglund A, Dimopoulos G, Pantazi A, Orfanos SE, et al. Macrophage activation-like syndrome: an immunological entity associated with rapid progression to death in sepsis. *BMC Med*. 2017;15(1):172–82.
- 7 Gruda MC, Ruggenberg K-C, O’Sullivan P, Guliashvili T, Scheirer AR, Golobish TD, et al. Broad adsorption of sepsis-related PAMP and DAMP molecules, mycotoxin and cytokines from whole blood using CytoSorb® sorbent porous polymer beads. *PLoS One*. 2018 Jan 25;13(1):e0191676.
- 8 Malard B, Lambert C, Kellum JA. In vitro comparison of the adsorption of inflammatory mediators by blood purification devices. *Intensive Care Med Exp*. 2018;6(1):12–25.
- 9 Brouwer WP, Duran S, Kuijper, M, Ince C: Hemoadsorption with CytoSorb shows a decreased observed versus expected 28-day all-cause mortality in ICU patients with septic shock: a propensity-score-weighted retrospective study. *Crit Care*. 2019;23(1):317–26.
- 10 Zuccari S, Damiani E, Domizi R, Scorcella C, D’Arezzo M, Carsetti A, et al. Changes in cytokines, haemodynamics and microcirculation in patients with sepsis/septic shock undergoing continuous renal replacement therapy and blood purification with CytoSorb. *Blood Purif*. 2020;49(1–2):107–13.
- 11 Bottari G, Merli P, Guzzo I, Stoppa F, Ruggeri A, Di Nardo M, et al. Multimodal therapeutic approach of cytokine release syndrome developing in a child given chimeric antigen receptor-modified T cell infusion. *Crit Care Explor*. 2020;2(1):e0071.
- 12 Mehta P, McAuley DF, Brown M, Sanchez E, Tattersall RS, Manson JJ. COVID-19: consider cytokine storm syndromes and immunosuppression. *Lancet*. 2020;395(10229):1033–4.
- 13 Fardet L, Galicier L, Lambotte O, Marzac C, Aumont C, Chahwan D, et al. Development and validation of the HScore, a score for the diagnosis of reactive hemophagocytic syndrome. *Arthritis Rheumatol*. 2014;66(9):2613–20.
- 14 Daniels LB. Pretenders and contenders: inflammation, C-reactive protein, and interleukin-6. *J Am Heart Assoc*. 2017 Oct 24;6(10):e007490.
- 15 Ronco C, Reis T, De Rosa S. Coronavirus epidemic and extracorporeal therapies in intensive care: si vis pacem para bellum. *Blood Purif*. 2020;49(3):255–8.
- 16 Cao B, Wen D, Liu W, Wag J, Fan G, Ruan L, et al. A trial of lopinavir-ritonavir in adults hospitalized with severe SARS-COV-2-19. *New Engl J Med*. 2020.
- 17 Dong L, Hu S, Gao J. Discovering drugs to treat coronavirus disease 2019 (COVID-19). *DD&T*. 2020;14(1):58–60.