

Study of Incidence and Factors: Risk and Preventive, of Chronic Subdural Hematoma/hygroma in Clipped Patients of Unruptured Intracranial Aneurysms – An Institutional Experience

Abstract

Introduction: One of the underreported complications of clipping of unruptured aneurysm is chronic subdural hematoma/hygroma (CSDH). It can cause sudden deterioration and might need emergency evacuation. Recently, very few papers have studied its incidence and predisposing factors. We are reporting our institutional experience of it along with the study of its risk factors and possible pathogenesis. **Methodology:** Totally 91 postoperative patients of unruptured aneurysms were retrospectively analyzed. Totally 21 patients had CSDH who were operated. In rest seventy patients, there was no CSDH. **Results:** Male sex, old age, anticoagulant use, presence of pneumocephalus and dead space were significantly associated with occurrence of CSDH, whereas arachnoidoplasty significantly protected against it. There was no significant relation of CSDH with Gorei-san use. **Conclusions:** We recommend arachnoidoplasty should be carried out in all patients of clipping of unruptured aneurysm. Male patients or/and patients with dead space with pneumocephalus must be given extra attention like avoiding any dead space in postoperative period, doing arachnoidoplasty and regular follow up till 1st year.

Keywords: Arachnoidoplasty, chronic subdural hematoma/hygroma, clipping, pneumocephalus, unruptured aneurysm

**Tsukasa Kawase,
Ishu Bishnoi¹,
Riki Tanaka,
Chinmaya Dash²,
Yoko Kato,
Yoshiru Yamada**

*Department of Neurosurgery,
Banbuntane Hotokukai Hospital,
Fujita Health University,
Otobashi, Nagoya, Japan,
¹Department of Neurosurgery,
Maharaja Agrasen Medical
College, Agroha, Hisar,
Haryana, ²Department
of Neurosurgery, AIIMS,
New Delhi, India*

Introduction

In the last few years, unruptured intracranial aneurysms have been detected more frequently due to good screening methods.^[1] The numbers of patients who are undergoing clipping of unruptured aneurysms, have increased significantly. The surgery is easy due to fewer adhesions, no brain edema and good plane of dissection. The morbidity and mortality are also less due to well-preserved patients. One of the side effects, which have been, especially reported in clipping of unruptured aneurysm, is chronic subdural hematoma/hygroma (CSDH).^[2,3] It can cause morbidity and mortality both. Very few studies are there, which have reported its incidence, risk factors and methods to prevent it in clipped unruptured aneurysm.^[2-5] We did an institutional study to find its incidence, predisposing risk factors, methods which can prevent it.

Methodology

This was a retrospective comparative study, which included operated patients

between 2014 and 2015. Patients of unruptured aneurysms treated by clipping at our institute, of any age/sex, who were followed up for 1 year, were enrolled in this study after informed consent. We took approval from the Institutional Ethical Committee. Totally 100 patients were operated, of which, 91 patients were enrolled who met all inclusion criteria. Patient's details were taken from our data collection center. Two groups were formed – patients who developed symptomatic CSDH for which they were operated (Group I) and patients who either developed small asymptomatic CSDH, managed conservatively or no CSDH at all (Group II). The demographic profile of patients such as age/sex, aneurysm site, use of Kampo medicine (Gorei-san which is suspected to prevent CSDH), anticoagulant use (pre- or post-operatively), the presence of pneumocephalus, arachnoidoplasty were analyzed and compared in all patients of both groups. Tables 1 and 2 show the details of Group I and II, respectively. The Bar Chart 1 depicts the

Address for correspondence:
Dr. Ishu Bishnoi,
Department of Neurosurgery,
Maharaja Agrasen Medical
College, Agroha - 125 047,
Hisar, Haryana, India.
E-mail: ishubishnoi@gmail.com

Access this article online

Website: www.asianjns.org

DOI: 10.4103/ajns.AJNS_355_16

Quick Response Code:



How to cite this article: Kawase T, Bishnoi I, Tanaka R, Dash C, Kato Y, Yamada Y. Study of incidence and factors: Risk and preventive, of chronic subdural hematoma/hygroma in clipped patients of unruptured intracranial aneurysms – An institutional experience. *Asian J Neurosurg* 2018;13:707-13.

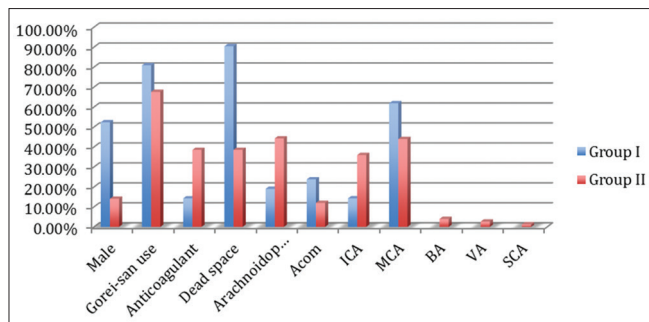
This is an open access journal, and articles are distributed under the terms of the Creative Commons Attribution-NonCommercial-ShareAlike 4.0 License, which allows others to remix, tweak, and build upon the work non-commercially, as long as appropriate credit is given and the new creations are licensed under the identical terms.

For reprints contact: reprints@medknow.com

distribution (percentage wise) of all analyzed factors in both groups.

Illustrative case (Group I)

First [3rd patient in Table 1 and Figure 1a-d] A female aged 76 years, operated for the left middle cerebral artery (MCA) aneurysm [Figure 1a] without arachnoidoplasty. She was given Gorei-san in the postoperative period and was on tablet aspirin for long time. She was having complaint of headache in the postoperative period. Computed tomography (CT) [Figure 1c] head was done, which detected large left hemispheric CSDH. She underwent burr hole evacuation under sedation, after informed consent. Gorei-san was given after evacuation and follow up CT head [Figure 1d] revealed no recurrence. She recovered without deficit.



Bar Chart 1: Depicting distribution of various parameters in both groups. ACOM – Anterior communicating artery; ICA – Internal carotid artery; MCA – Middle cerebral artery; BA – Basilar artery; VA – Vertebral artery; SCA – Superior cerebellar artery

Second [9th patient in Table 1 and Figure 2a-d] A gentleman, aged 71 years, operated for anterior communicating (ACOM) aneurysm [Figure 2d] clipping by inter hemispheric approach, without arachnoidoplasty. He received Gorei-san in postoperative period, And no aspirin. He presented with headache, forgetfulness, and urinary incontinence in follow up after 5 months. CT head [Figure 2b] was suggestive of large left side CSDH. It was evacuated by burr hole under sedation after informed

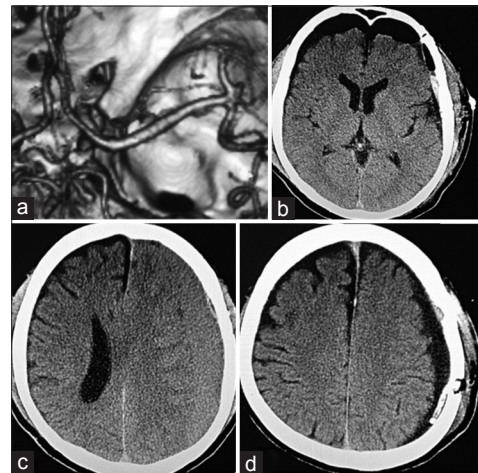


Figure 1: (a) Three-dimensional computed tomography angiogram left middle cerebral artery aneurysm, (b) postoperative computed tomography after clipping, showing dead space with pneumocephalus (bifrontal), (c) follow up computed tomography head at 1 month, large left side chronic subdural hematoma/hygroma compressing ipsilateral ventricle with midline shift, (d) postoperative computed tomography head with complete evacuation of chronic subdural hematoma/hygroma and drain *in situ*

Table 1: Clinical/demographic/intraoperative/radiological profile of Group I

Age	Gender	Location	Gorei-san	Plasty	CSDH detection	Site	Dead space	Aspirin
73	Male	Right ICA-PC	No	No	3M	Right	Yes	No
62	Male	Left MCA	No	No	1M	Left	Yes	No
76	Female	Left MCA	Yes	No	1M	Left	Yes	Yes
70	Female	Left MCA	Yes	No	2M	Left	Yes	No
71	Female	Left ICA-Oph	Yes	No	2M	Left	Yes	No
72	Female	Left MCA	No	No	2M	Left	Yes	No
62	Male	Right MCA	Yes	No	3M	Right	Yes	No
68	Male	Left MCA	Yes	No	3M	Left	Yes	No
71	Male	ACOM	Yes	No	5M	Right	Yes	No
55	Male	Left ICA-ACH	Yes	No	2M	Left	Yes	No
59	Male	ACOM	Yes	No	3M	Right	Yes	No
74	Female	ACOM	Yes	No	3M	b/l	Yes	Yes
74	Female	Right MCA	Yes	Yes	3M	Right	Yes	No
77	Male	Left MCA	Yes	No	3M	b/l	Yes	No
75	Female	Left MCA	Yes	Yes	3M	Left	Yes	No
64	Male	ACOM	Yes	No	3M	Left	Yes	No
72	Male	Right MCA	Yes	No	1M	Right	Yes	No
74	Female	Right MCA	Yes	No	3M	Right	Yes	No
65	Male	Left-A1 (ACOM complex)	Yes	Yes	2M	Left	Yes	No
66	Female	Left-MCA	Yes	No	6M	Left	Yes	No
79	Female	Right MCA	Yes	Yes	1M	Right	Yes	Yes

ICA – Internal Carotid Artery; PC – Posterior communicating artery; Oph – Ophthalmic segment; MCA – Middle cerebral artery; ACOM – Anterior communicating artery; ACH – Anterior choroidal artery; CSDH – Chronic subdural hematoma/hygroma; b/l – Bilateral

consent. Gorei-san was given in postoperative period. Postoperative CT head [Figure 2c] was clear.

Illustrative case (Group II)

First [23rd patient in Table 2 and Figure 3a-c] A lady, aged 61 years, operated for right MCA aneurysm [Figure 3a] clipping without arachnoidoplasty. She was given Gorei-san in postoperative period. There was no history of aspirin intake. Postoperative CT head [Figure 3b] showed dead space with pneumocephalus. There were no symptoms. Follow up CT head at 1 month showed no dead space/pneumocephalus and patient was asymptomatic.

Second [7th patient in Table 2 and Figure 4a-c] A lady, 80 years, operated for the right internal carotid artery-posterior communicating (ICA) [Figure 4a] junction aneurysm clipping without arachnoidoplasty. She was given Gorei-san in postoperative period. There was no history of aspirin intake. Postoperative CT head showed no dead space with pneumocephalus [Figure 4b]. There were no symptoms. In follow up after 6 months, patient was asymptomatic and CT head [Figure 4c] was normal.

Results

The incidence of symptomatic CSDH was 23% in our study. The mean postoperative duration of the occurrence of CSDH was 2.62 months in Group I. The age was calculated as mean age and compared by using two-sample independent *t*-test. There was significant difference ($P = 0.015$) between Group I (mean age – 69.48 ± 6.35 years) and Group II (mean age – 64.66 ± 11.32 years). Group I had higher age group patients.

Rest of the data were quantitative data, which was compared by using Chi-square/Fisher/Mantel–Haenszel

Chi-square/Yates corrected Chi-square test to know *P* value ($P < 0.05$ significant). Odds ratio (OR) was calculated to know the association between factors. We used OpenEpi, version 3 software (Emory University, Atlanta, Georgia) to do statistical analysis. The male patients were significantly more common in Group I (11/21, 52.4%) than the Group II (10/70, 14.3%). The use of anticoagulants (pre- or post-operative) was significantly ($P = 0.044$) associated with CSDH formation (Group I – 3/21 and Group II – 2/70). The occurrence of dead space with pneumocephalus was significantly ($P = 0.00001$) more common in Group I (19/21, 90.5%) than Group II (27/70, 38.6%). Use of Kampo medicine (Gorei-san) did not significantly reduce the CSDH (Group I – 17/21 and Group II – 48/70). The arachnoidoplasty (after clipping) was associated with significant ($P = 0.019$) reduction in CSDH formation (Group I – 4/21 and Group II – 31/70). Table 3 shows final results of both groups along with *P* value and OR.

Discussion

According to various studies, the incidence of CSDH in unruptured aneurysms clipping is between 2% and 20%.^[2-6] In our study, the incidence was 23%, which was almost similar to previous studies that considered both hematoma and hygroma. The findings were confirmed.

Various studies have shown that higher age group patients are more prone to develop CSDH.^[2-5] In this study, CSDH was significantly more common in older age group.

According to Kanat *et al.* study, male sex is more prone to develop CSDH due to more cerebral atrophy.^[7] In females, the estrogen has a protective action on capillaries, which is absent in males.^[2] In case of unruptured aneurysm clipping also, studies have confirmed this finding.^[2-6] We also found the same observation.

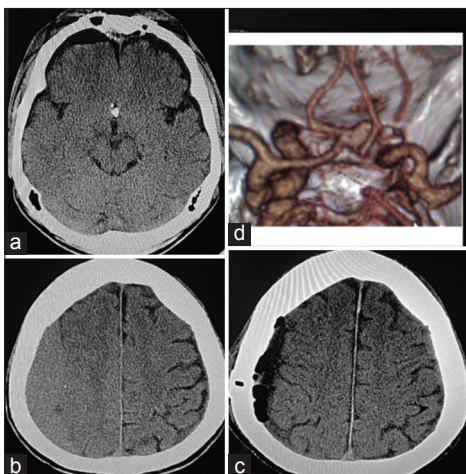


Figure 2: (a) Postoperative computed tomography of anterior communicating aneurysm clipping with dead space with pneumocephalus right frontal lobe, (b) follow up computed tomography head at 3 months, large chronic subdural hematoma/hygroma with no mass effect, (c) postoperative computed tomography head showing complete evacuation of chronic subdural hematoma/hygroma, (d) 3D computed tomography angiography showing anterior communicating aneurysm

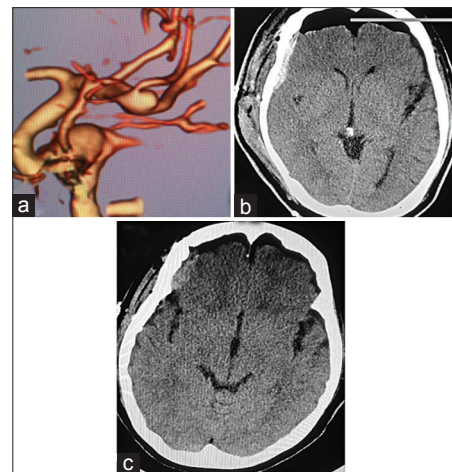

Figure 3: (a) Three-dimensional computed tomography angiography image of right middle cerebral artery aneurysm, (b) postoperative computed tomography head of the right middle cerebral artery clipping with large dead space and pneumocephalus, (c) follow up computed tomography head at 1 month with complete resolution of dead space and no chronic subdural hematoma/hygroma formation

Table 2: Clinical/demographic/intraoperative/radiological profile of Group II

Age	Gender	Location	Goreisan	Plasty	Deadspace	Aspirin
67	Female	Left ICA-Oph	No	No	Yes	No
74	Female	ACOM	No	No	Yes	No
71	Male	Left-ICA	No	No	Yes	No
69	Female	DACA	No	No	No	No
78	Female	Right ICA-PCOM	Yes	Yes	Yes	Yes
80	Female	ACOM	Yes	No	No	No
80	Female	Right-ICA-PCOM	Yes	No	No	No
76	Female	ACOM	Yes	No	No	No
82	Female	ACOM right-MCA left-MCA	Yes	Yes	No	No
73	Female	ACOM	Yes	Yes	No	No
67	Female	Right-ICA-PCOM	Yes	Yes	No	No
76	Female	Right-MCA	Yes	No	Yes	No
68	Male	BA-left SCA right-MCA	Yes	No	Yes	No
65	Female	Left ICA-ACH	Yes	Yes	No	No
64	Female	ICA	Yes	No	No	No
77	Male	Right MCA	Yes	Yes	No	Yes
67	Male	ACOM	Yes	No	Yes	No
49	Female	Left MCA	Yes	No	No	No
61	Female	Left ICA-PC	No	No	Yes	No
65	Female	ACOM	Yes	No	Yes	No
71	Female	Left ICA-PC	Yes	Yes	Yes	No
64	Female	Left MCA	Yes	No	No	No
61	Female	Right MCA	Yes	No	Yes	No
42	Female	Left MCA	Yes	Yes	Yes	No
53	Female	Left MCA	Yes	No	Yes	No
39	Female	Right ICA Oph	No	No	Yes	No
66	Male	Left MCA	Yes	Yes	No	No
61	Female	Left ICA	Yes	Yes	No	No
47	Female	Left MCA	Yes	Yes	No	No
36	Female	Left ICA	Yes	Yes	Yes	No
63	Female	Left ICA-PC	Yes	Yes	Yes	No
56	Female	Left ICA	Yes	Yes	No	No
47	Female	Left ICA	Yes	No	Yes	No
73	Female	Right MCA	Yes	No	No	No
57	Female	Left ICA Oph	Yes	Yes	No	No
73	Female	Left ICA-PC	Yes	Yes	Yes	No
80	Male	Left MCA	Yes	No	Yes	No
64	Female	Left ICA	Yes	No	Yes	No
75	Female	Left ICA-ACH	Yes	Yes	No	No
78	Female	Right MCA	No	No	Yes	No
67	Female	Right MCA	Yes	Yes	No	No
48	Female	Right MCA	Yes	No	No	No
63	Female	Right ICA-ACH	Yes	Yes	No	No
54	Female	BA top	No	No	No	No
77	Male	Left MCA	Yes	No	No	No
61	Male	BA top and ACOM	Yes	No	Yes	No
71	Female	Right ICA-PC	Yes	Yes	No	No
69	Female	Right MCA	Yes	Yes	Yes	No
76	Male	ACOM	Yes	Yes	No	No
59	Female	Right MCA	Yes	Yes	Yes	No
44	Female	Right MCA	Yes	No	No	No
36	Female	Right ICA Oph	Yes	No	Yes	No
62	Female	Right MCA	Yes	Yes	No	No
55	Female	Left ICA-PC	Yes	Yes	No	No

Contd...

Table 2: Contd...

Age	Gender	Location	Goreisan	Plasty	Deadspace	Aspirin
72	Female	Left VA PICA	Yes	No	No	No
73	Female	Left MCA	Yes	Yes	No	No
58	Female	Left ICA	Yes	Yes	No	No
78	Female	Right MCA	Yes	No	No	No
47	Female	Right MCA	Yes	Yes	No	No
56	Male	Left ICA ACH	Yes	Yes	No	No
75	Female	Left MCA	Yes	Yes	No	No
59	Female	Left MCA	No	No	No	No
76	Female	Right MCA	No	No	No	No
65	Female	Left ICA-PC	No	No	No	No
64	Female	Right MCA	No	No	No	No
79	Female	Right MCA	No	No	Yes	No
68	Female	Left ICA Oph	No	No	Yes	No
67	Female	Right VA-PICA	Yes	Yes	No	No
68	Female	Right MCA	Yes	No	No	No
64	Female	Left ICA	No	No	No	No

ICA – Internal carotid artery; PC – Posterior communicating artery; Oph – Ophthalmic segment; MCA – Middle cerebral artery; ACOM – Anterior communicating artery; ACH – Anterior choroidal artery; VA – Vertebral artery, BA – Basilar artery; DACA – Distal anterior cerebral artery; PICA – Posterior inferior cerebellar artery; SCA – Superior cerebellar artery; PCOM – Posterior communicating artery

Table 3: Data analysis of all factors and P value in both groups

Factors	Group I (%)	Group II (%)	P	OR
Mean age (years)	69.5	64.66	<0.015	-
Male:Female	11:10	10:60	<0.0004	6.6
Gorei-san use	17/21	48/70	>0.143	0.5865
Anticoagulant	3/21	2/70	>0.044	5.667
Dead space	19/21	27/70	<0.00001	15.13
Arachnoidoplasty	4/21	31/70	<0.019	0.296
Aneurysm location				
Total aneurysms	21	75		
ACOM	5 (23.8)	9 (12)		
ICA (PCOM, ACH, Oph, bifurcation, cavernous)	3 (14.3)	27 (36)		
Total depth aneurysms (ICA + ACOM complex)	8 (38.1)	36 (48)	0.218	0.667
MCA	13 (61.9)	33 (44)	0.079	2.068
BA	0	3 (4)		
VA	0	2 (2.7)		
SCA	0	1 (1.3)		
Multiple	0	3		

ACOM – Anterior communicating artery; ICA – Internal carotid artery; PCOM – Posterior communicating artery; ACH – Anterior choroidal artery; Oph – Ophthalmic; MCA – Middle cerebral artery; BA – Basilar artery; VA – Vertebral artery; SCA – Superior cerebellar artery; OR – Odds ratio

The aneurysms located in depth, for example, ACOM artery or ICA, are more common to develop CSDH formation than MCA aneurysm clipping.^[2] Lee *et al.* gave the explanation that the more cisternal dissection and hence, more cerebrospinal fluid (CSF) loss in the case of depth aneurysms (anterior cerebral artery [ACA] and ICA) than surface aneurysms (MCA) might be the cause of increased CSDH formation.^[2] In our study, MCA aneurysm was the most common in both groups and there was no statistical significant difference in aneurysm distribution. The possible reason could be much more common incidence of MCA aneurysm in our aneurysmal patients.

Kampo medicine, which includes Gorei-san, is a Japanese herbal medicine that has been used to treat CSDH formation and recurrence.^[8-10] Various studies on the use of Kampo medicine in CSDH occurrence and recurrence have showed both promising and nonpromising results.^[8-11] The possible mechanism of prevention of CSDH is via inhibitory effect on aquaporin-4.^[8] The aquaporin-4 receptors are present on dural membrane and it cause increased fluid formation in subdural space.^[8] Gorei-san ingredients like poria, polypus, *Atractylodes*, lanceae rhizoma inhibit aquaporin-4 and thus decrease subdural collection.^[8,12] In this study, we could not find statistical significant reduction of CSDH occurrence

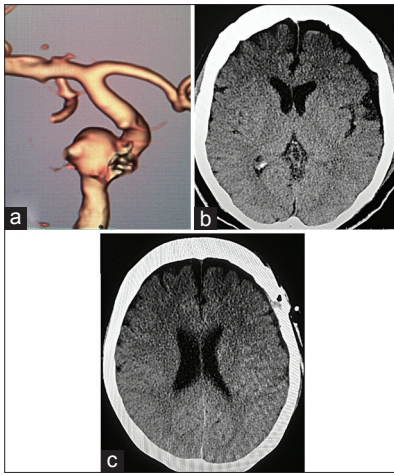


Figure 4: (a) Three-dimensional computed tomography angiography image of right internal carotid artery-posterior communicating aneurysm, (b) postoperative right internal carotid artery-posterior communicating aneurysm clipping with almost nil dead space and no pneumocephalus, (c) follow up computed tomography head at 3 months with no chronic subdural hematoma/hygroma formation

with Gorei-san use, but we found that in postoperative period of CSDH patients, there was no recurrence of it. We think that Gorei-san or Kampo medicine might have some role in prevention of CSDH, at least after hematoma evacuation, and one large-scale randomized study is needed to know about it.

The presence of significantly more dead space due to cerebral atrophy/dehydration, is associated with CSDH formation.^[2,13] However, the presence of pneumocephalus has not been studied by any searched study on PubMed. We found postoperative dead space and pneumocephalus (CT brain) in all patients, who developed postoperative CSDH. The finding was very significantly ($P < 0.0001$) associated with the occurrence of CSDH. The possible hypothesis could be the empty space and air. Postsurgery, arachnoid is torn and it leads to direct contact of brain cortex and CSF with subdural space. The air has almost no pressure and brain is injured due to retraction/manipulation. It leads to continuous oozing of capillaries and CSF in empty subdural space. It might not happen if arachnoid remains intact and fluid like saline is filled, to remove air. However in absence of protective factors, this leaked fluid and CSF, full of inflammatory cells and cytokines, lead to CSDH formation. As this is only a possible hypothesis, it needs to be confirmed by further studies. Yagi *et al.* have proposed that arachnoid tear causing CSF leak in subdural space and then subdural fluid collection.^[14]

The use of anticoagulants leading to CSDH has been very well established.^[13] In our study, use of anticoagulants (aspirin) was significantly associated with occurrence of CSDH. The role of arachnoidoplasty in prevention of CSDH is recently been documented by a few studies.^[14,15] The possible mechanism is prevention of CSF leak in subdural space by repairing torn arachnoid.^[14,15] It

is usually carried out by using fibrin glue. Lee *et al.* study showed that there was no statistically significant reduction in CSDH formation after doing it. They gave the reason that it might be due to spontaneous dissolution of glue over time and then leak again. In our study, we found that the arachnoidoplasty significantly reduced CSDH in postclipping patients. Other than prevention of CSF leak, we think that it also acts through reducing the subdural space by increasing CSF + brain volume covered by arachnoid.

Our study has a few limitations also. It was a retrospective, nonrandomized study. Our patient number is 91, which is lesser than the other reports.

Conclusions

It can be concluded that incidence of CSDH formation is quite high in postoperative patients of unruptured aneurysm clipped patients. To reduce its occurrence, we should do arachnoidoplasty and avoid postoperative pneumocephalus/dead space by filling subdural space with saline. The male sex, patients using anticoagulants and depth aneurysms (ACA/ICA) must be strictly followed up with CT brain, after taking necessary precautions to prevent CSDH formation. Role of Kampo medicine is still not clear and it should be confirmed by a large scale prospective randomized study.

Financial support and sponsorship

Nil.

Conflicts of interest

There are no conflicts of interest.

References

1. Ajiboye N, Chalouhi N, Starke RM, Zanaty M, Bell R. Unruptured cerebral aneurysms: Evaluation and management. *ScientificWorldJournal* 2015;2015:954954.
2. Lee WJ, Jo KI, Yeon JY, Hong SC, Kim JS. Incidence and risk factors of chronic subdural hematoma after surgical clipping for unruptured anterior circulation aneurysms. *J Korean Neurosurg Soc* 2015;57:271-5.
3. Ohno T, Iihara K, Takahashi JC, Nakajima N, Satow T, Hishikawa T, *et al.* Incidence and risk factors of chronic subdural hematoma after aneurysmal clipping. *World Neurosurg* 2013;80:534-7.
4. Park J, Cho JH, Goh DH, Kang DH, Shin IH, Hamm I. Postoperative subdural hygroma and chronic subdural hematoma after unruptured aneurysm surgery: Age, sex, and aneurysm location as independent risk factors. *J Neurosurg* 2016;124:310-7.
5. Inamasu J, Watabe T, Ganaha T, Yamada Y, Nakae S, Ohmi T, *et al.* Clinical characteristics and risk factors of chronic subdural haematoma associated with clipping of unruptured cerebral aneurysms. *J Clin Neurosci* 2013;20:1095-8.
6. Kwon MY, Kim CH, Lee CY. Predicting factors of chronic subdural hematoma following surgical clipping in unruptured and ruptured intracranial aneurysm. *J Korean Neurosurg Soc* 2016;59:458-65.
7. Kanat A, Kayaci S, Yazar U, Kazdal H, Terzi Y. Chronic

- subdural hematoma in adults: Why does it occur more often in males than females? Influence of patient's sexual gender on occurrence. *J Neurosurg Sci* 2010;54:99-103.
8. Yasunaga H. Effect of Japanese herbal Kampo medicine Goreisan on reoperation rates after burr-hole surgery for chronic subdural hematoma: Analysis of a National Inpatient Database. *Evid Based Complement Alternat Med* 2015;2015:817616.
 9. Miyagami M, Kagawa Y. Effectiveness of Kampo medicine Gorei-san for chronic subdural hematoma. *No Shinkei Geka* 2009;37:765-70.
 10. Muramatsu M, Yoshikawa T, Hanabusa K. Effectiveness of Kampo medicine Gorei-san-ryo for chronic subdural hematoma in very elderly patients. *No Shinkei Geka* 2005;33:965-9.
 11. Okamura A, Kawamoto Y, Sakoda E, Murakami T, Hara T. Evaluation of recurrence factors and Gorei-san administration for chronic subdural hematoma after percutaneous subdural tapping. *Hiroshima J Med Sci* 2013;62:77-82.
 12. Nagai K, Isoyama Y, Koga T, Ashizuka T, Hisatsune A, Miyata T. Effect of herbal extracts and minerals on aquaporin-mediated water transport across plasma membrane. *J Pharm Sci* 2005;97:3.
 13. Baechli H, Nordmann A, Bucher HC, Gratzl O. Demographics and prevalent risk factors of chronic subdural haematoma: Results of a large single-center cohort study. *Neurosurg Rev* 2004;27:263-6.
 14. Yagi K, Irie S, Inagaki T, Ishii Y, Saito O, Lee T, *et al.* Intraoperative arachnoid plasty has possibility to prevent chronic subdural hematoma after surgery for unruptured cerebral aneurysms. *Neurol Med Chir (Tokyo)* 2015;55:493-7.
 15. Mino Y, Hirashima Y, Hamada H, Masuoka T, Yamatani K, Takeda S, *et al.* Effect of arachnoid plasty using fibrin glue membrane after clipping of ruptured aneurysm on the occurrence of complications and outcome in the elderly patients. *Acta Neurochir (Wien)* 2006;148:627-31.