

# Alternative All-Inside Technique of Repairing a Vertical Meniscus Tear



Vikram Arun Mhaskar, M.S., M.Ch.

**Abstract:** Lateral meniscus vertical tears are often seen with acute anterior cruciate ligament injuries. The inside-out technique of repairing the meniscal tear is currently the gold standard treatment. However, every technique has its own drawbacks. The inside-out technique has possible risk of infection and neurovascular complications. All-inside techniques are becoming increasingly popular. A novel all-inside technique and a variation of it for meniscus repair using an antegrade suture passer like a Knee Scorpion are described. These are cost effective using a 2-0 FiberWire for repair of vertical meniscal tears. This technique also provides a better control of reduction at tear site through tensioning the 2 suture limbs. It is cost effective, easy to use, and has less neurovascular complications as compared with the inside-out technique.

Lateral meniscus vertical tears are often seen with acute anterior cruciate ligament injury.<sup>1</sup>Treatment options range from meniscectomy to meniscus repair. However, repairs have proven advantages in clinical literature and should be performed wherever possible.<sup>2</sup>The inside-out technique of repair is currently the gold standard.<sup>3</sup>The all-inside repair is increasingly becoming popular but is, however, more expensive.<sup>4</sup>Antegrade suture passers like the Scorpion have been used routinely in shoulder surgery. However, the knee provides less space to manipulate these devices in routine meniscus repairs.<sup>5</sup>Knee-specific antegrade suture passers like the Knee Scorpion (Arthrex, Naples, FL) have been introduced that are more low profile to be used in tight spaces like the knee. They are used in repairing root tears of the menisci.<sup>6</sup>However, there has been just 1 case report on their use in bucket-handle meniscus tears.<sup>7</sup>The described techniques are novel all-inside future repair techniques of lateral meniscus vertical tears using a knee scorpion and 2-0 FiberWire suture (Arthrex). There are 2 variations of the

technique that have been described individually, depending on the location of the tear and the width of the meniscus. Technique A is used in tears that are in the red-white zone or where the posterior horn's width is not greater than the length of the Knee Scorpion's jaw. Technique B is used in cases in which the tear is in the red-red zone or the posterior horn width is more than the length of the Knee Scorpion's jaw.

## Technique A (With Video Illustration)

A standard anterolateral portal (portal A) of 1 cm in size is made in the soft spot and the arthroscope is introduced. The vertical tear in the lateral meniscus is identified. The joint space is opened up by giving a varus stress in a figure of 4 position on the operating table and the tear is visualized (Fig 1 A and B). A 1-cm high horizontal medial portal (portal B) is made such that instruments can be introduced into the lateral compartment without scuffing the cartilage. The tear is freshened using a diamond rasp. A flexible PassPort Cannula (Arthrex) is introduced through portal B. The

From the Department of Orthopaedics, Max Smart Hospital, New Delhi, India; and Knee & Shoulder Clinic, New Delhi, India.

The author reports that he has no conflicts of interest in the authorship and publication of this article. Full ICMJE author disclosure forms are available for this article online, as [supplementary material](#).

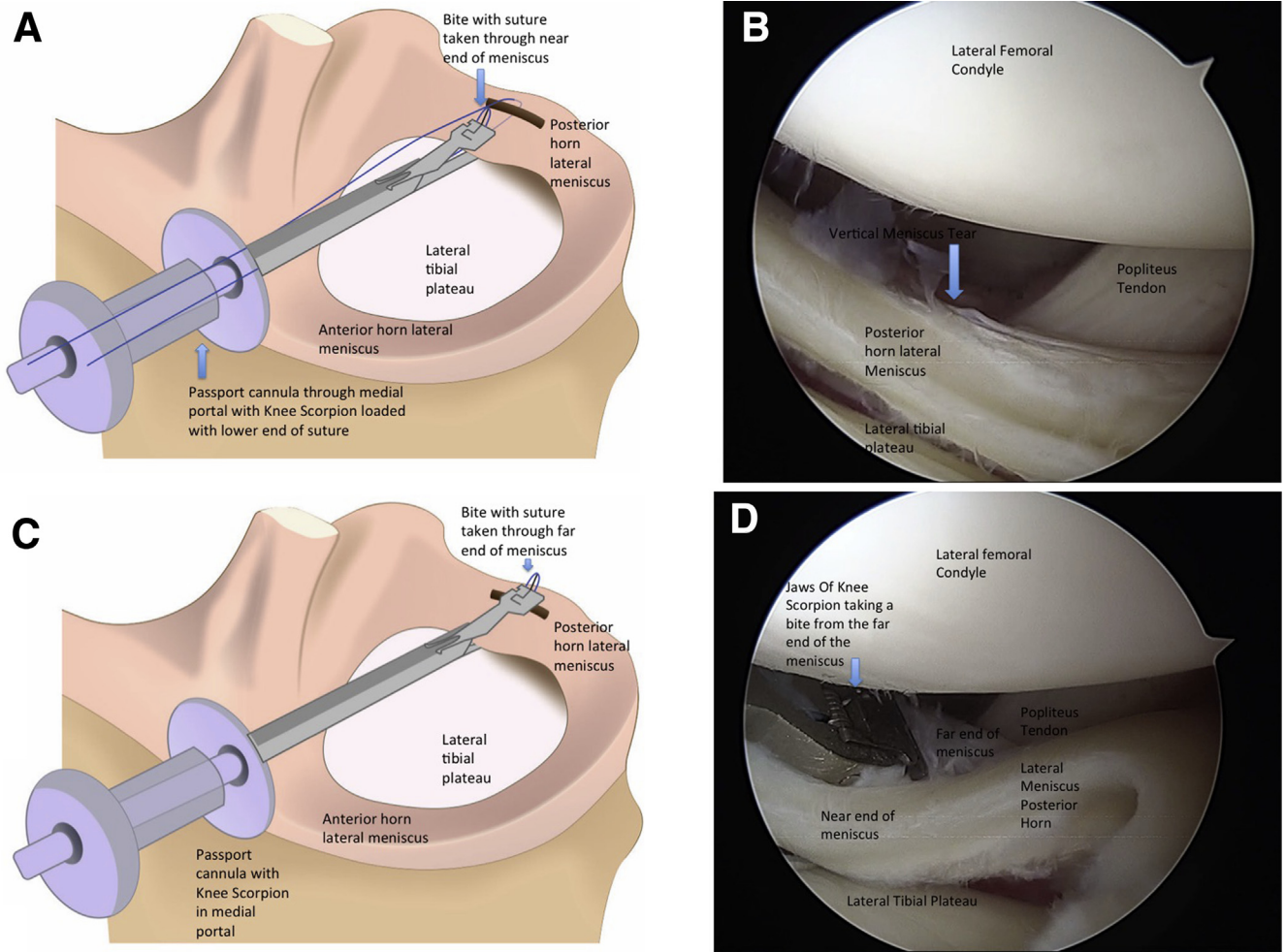
Received February 29, 2020; accepted April 26, 2020.

Address correspondence to Vikram Arun Mhaskar, M.S., M.Ch., Department of Orthopaedics, Max Smart Hospital, New Delhi, Delhi 110070, India. E-mail: [drvikrammhaskar@gmail.com](mailto:drvikrammhaskar@gmail.com)

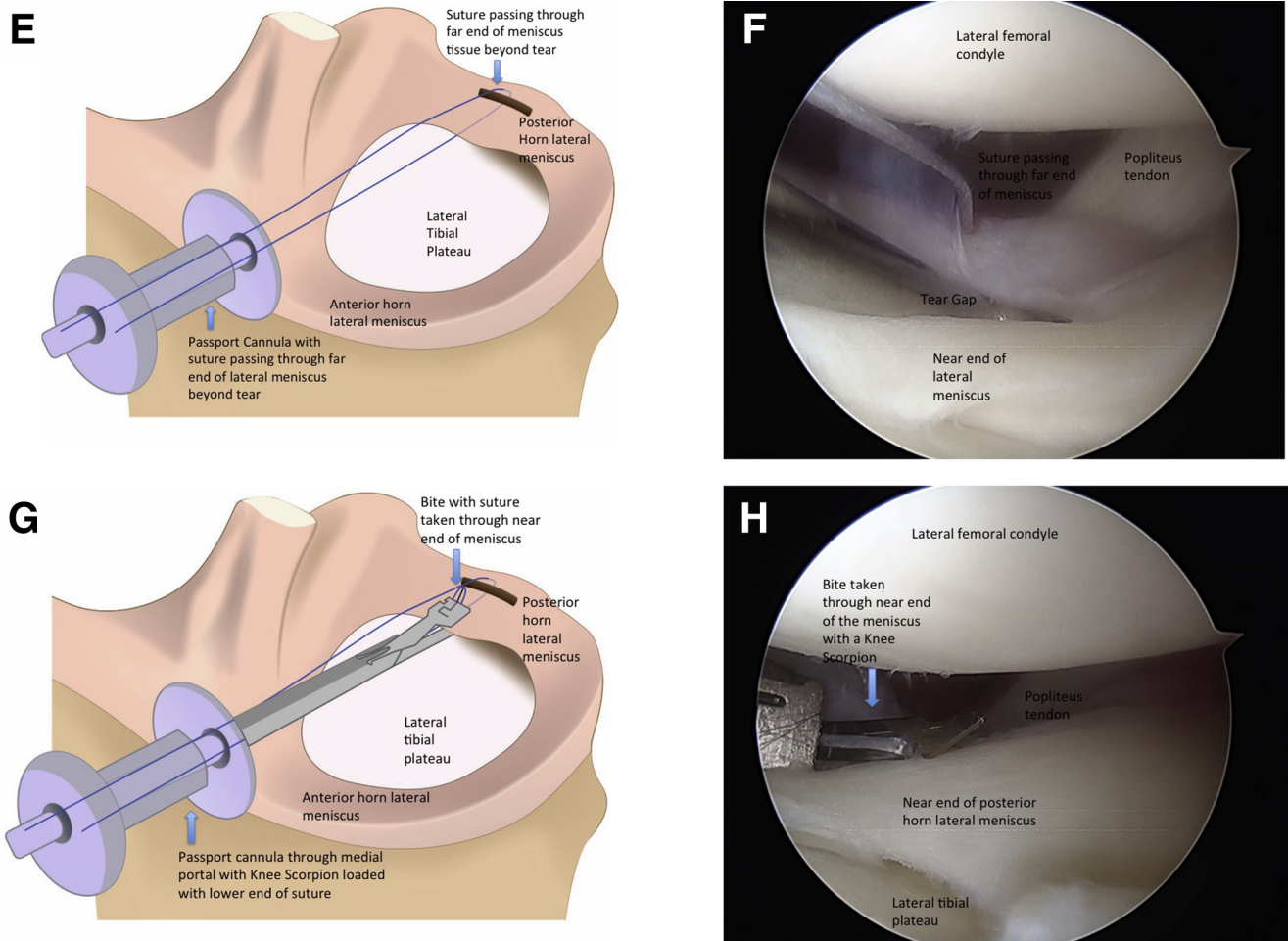
© 2020 by the Arthroscopy Association of North America. Published by Elsevier. This is an open access article under the CC BY-NC-ND license (<http://creativecommons.org/licenses/by-nc-nd/4.0/>).

2212-6287/20293

<https://doi.org/10.1016/j.eats.2020.04.018>



**Fig 1.** (A) Illustration of the left knee with a vertical meniscus tear in the posterior horn of the lateral meniscus. (B) Arthroscopic image of the left knee viewed from a standard anterolateral portal with knee in figure of 4 position showing vertical tear of lateral meniscus in posterior horn. (C) Illustration of the left knee showing the lateral meniscus and Knee Scorpion loaded with a suture introduced from a high medial portal with a PassPort Cannula in it taking a bite in the peripheral meniscus tissue beyond the tear. (D) Arthroscopic image of left knee viewed from a standard anterolateral portal with knee in figure of 4 position showing a Knee Scorpion loaded with a 2-0 FiberWire introduced from a high medial portal with a PassPort Cannula taking a bite in the peripheral meniscus tissue beyond the tear. (E) Illustration of left knee showing both ends of a suture from a medial portal containing a PassPort Cannula passing through the peripheral meniscus tissue beyond the tear and suture's lower end coming from under the near end of meniscus tissue central to the tear. (F) Arthroscopic image of the left knee viewed from a standard anterolateral portal with knee in figure of 4 position showing a 2-0 FiberWire passing through peripheral meniscus tissue. The FiberWire is in a PassPort Cannula in a high medial portal. (G) Illustration of the left knee in showing a Knee Scorpion loaded with the lower end of the suture introduced through a PassPort Cannula from a high medial portal taking a bite from the near end of the meniscus central to the tear. (H) Arthroscopic image of left knee viewed from a standard anterolateral portal with knee in figure of 4 position showing a Knee Scorpion loaded with the lower end of the 2-0 FiberWire introduced through a PassPort Cannula from a high medial portal taking a bite from the near end of the meniscus central to the tear. (I) Illustration of the left knee showing 2 ends of a suture coming from a PassPort Cannula from a high medial portal passing through the near and peripheral (far end) of meniscus tissue. (J) Illustration of the left knee showing a knot pusher passing through a PassPort Cannula from a high medial portal tying a simple knot to approximate the tear. (K) Arthroscopic image of left knee viewed from a standard anterolateral portal with knee in figure of 4 position showing a knot pusher pushing a simple knot to approximate the tear. The knot pusher is coming from a high medial portal containing a PassPort Cannula. (L) Illustration of the left knee showing an approximated meniscus tear with a simple knot with 3 throws. (M) Arthroscopic image of the left knee viewed from a standard anterolateral portal with knee in figure of 4 position showing a an approximated meniscus tear with a knot with 3 throws tied.



**Fig 1. (continued).**

lower jaw of the Scorpion is loaded with a 2-0 FiberWire. The suture-loaded Knee Scorpion is then introduced through this portal. The jaws of the Knee Scorpion are opened and the meniscal tissue grasped till beyond the tear. The jaws are closed to secure the meniscal tissue and scorpion needle advanced to retrieve the FiberWire through the upper jaw (Fig 1 C and D). The scorpion is pulled back through the portal. The FiberWire is released from the scorpion. This secures the bite through the peripheral part of the meniscus beyond the tear (Fig 1 E and F). The Knee Scorpion is again loaded with the inferior arm of the FiberWire that passes under the meniscus. The meniscal tissue central to the tear is grasped again with the scorpion and jaws closed. The FiberWire is retrieved by

advancing the needle of scorpion (Fig 1 G and H), and the scorpion is withdrawn. The FiberWire is released from the scorpion, leaving 2 ends of the FiberWire passing through near and far ends of the meniscal tissue around the tear (Fig 1I). Taking the peripheral part of the FiberWire as a post, a knot is tied in the peripheral part of meniscus with a knot pusher and a total of 3 knots tied (Fig 1 J and K). The FiberWire is cut flush with knot with the help of a suture cutter (Fig 1 L and M).

### Technique B (With Video Illustration)

This technique is used when the jaws of the Knee Scorpion are not able to reach the peripheral portion of the meniscus tissue beyond the tear to pass the



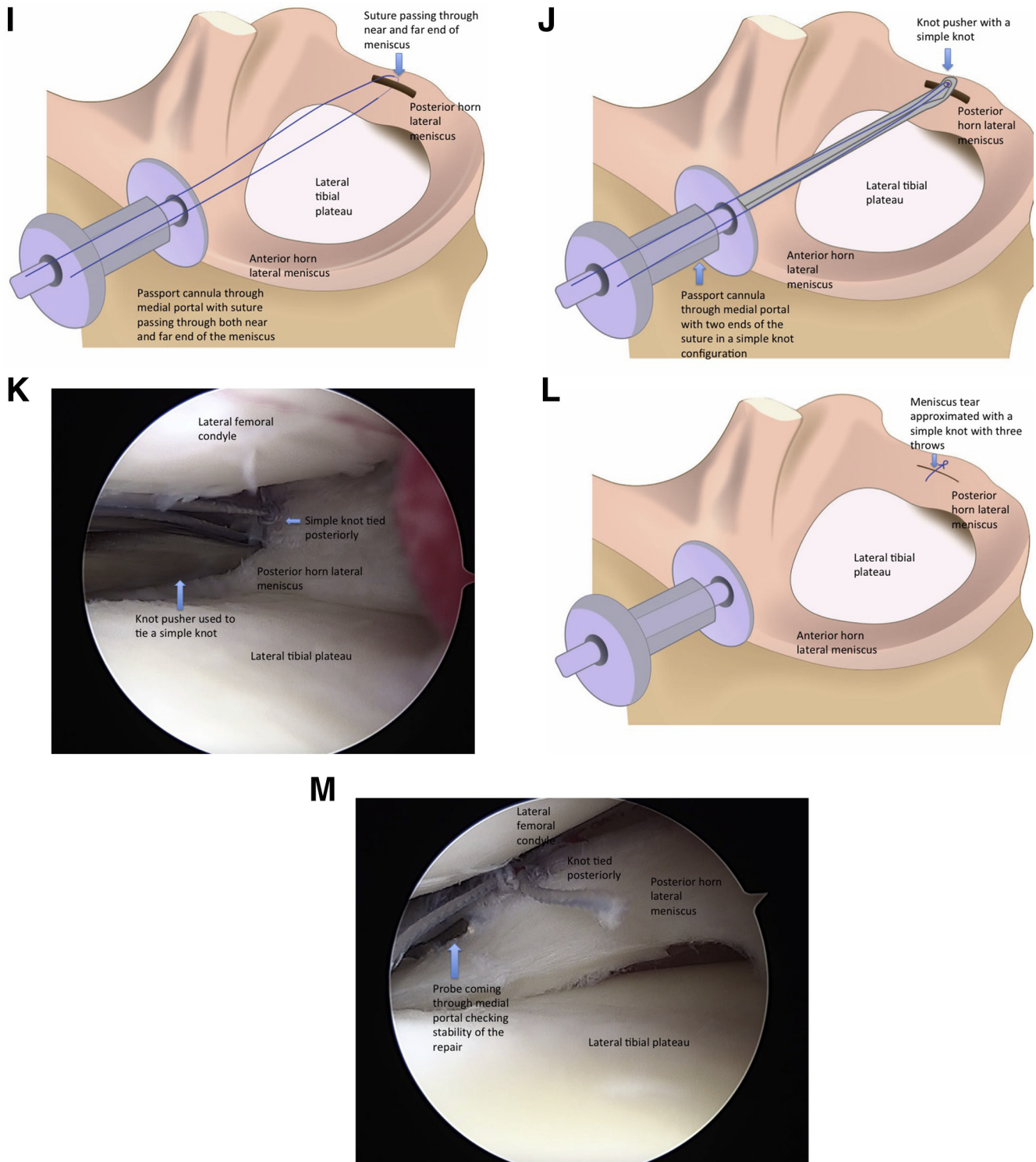
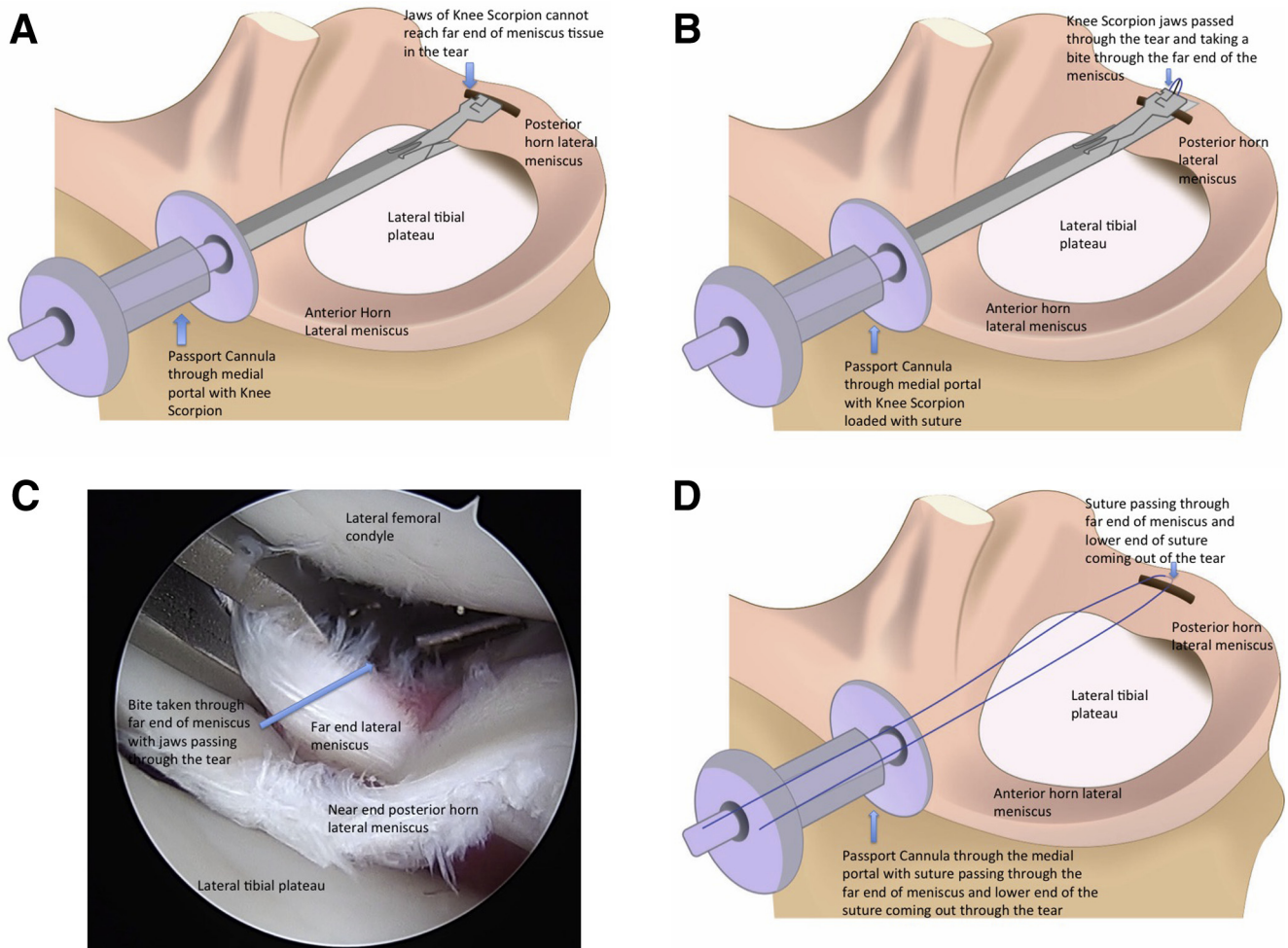


Fig 1. (continued).

FiberWire through this tissue (Fig 2A). The jaws of the Knee Scorpion are opened and passed through the tear itself to grasp the peripheral part of the tear. The jaws are closed to secure the meniscal tissue and scorpion

needle advanced to retrieve the FiberWire through the upper jaw (Fig 2 BandC). This leaves the upper arm of the FiberWire going through the peripheral meniscus tissue and lower arm coming out through the tear



**Fig 2.** (A) Illustration of the left knee showing a Knee Scorpion introduced through a PassPort Cannula through a high medial portal whose jaws cannot reach the peripheral meniscus tissue (beyond the tear). (B) Illustration of the left knee showing a Knee Scorpion loaded with a suture passed through a PassPort Cannula in a high medial portal passed through the tear and taking a bite through the peripheral meniscus tissue. (C) Arthroscopic image of left knee in figure of 4 position, viewing from a standard anterolateral portal with a Knee Scorpion loaded with a 2-0 FiberWire passed through a PassPort Cannula in a high medial portal passed through the tear and taking a bite through the peripheral meniscus tissue. (D) Illustration of the left knee showing a suture passing through the far end of the meniscus and lower end coming out through the tear. (E) Arthroscopic image of the left knee in figure of 4 position, viewing from a standard anterolateral portal showing a 2-0 FiberWire passing through the peripheral meniscus and lower end coming out through the tear. Both ends of the suture pass out through a PassPort Cannula in a high medial portal. (F) Illustration of the left knee showing a crochet passing through a PassPort Cannula in a high medial portal passing under the near end of the meniscus and engaging the lower end of the suture coming out through the tear. (G) Arthroscopic image of left knee in figure of 4 position, viewing from a standard anterolateral portal showing a crochet introduced under the near end of the meniscus central to the tear engaging the lower end of the 2-0 FiberWire coming out through the tear. The Crochet is introduced through the PassPort Cannula in the high medial portal. (H) Illustration of the left knee showing the crochet in the PassPort Cannula in high medial portal pulling the lower end of the suture coming from the tear to under the near end of the meniscus through into the PassPort Cannula. (I) Arthroscopic image of the left knee in figure of 4 position, viewing from a standard anterolateral portal showing the crochet pulling the lower end of the 2-0 FiberWire under the near end of the meniscus central to the tear. The crochet is coming from a PassPort Cannula in the high medial portal.

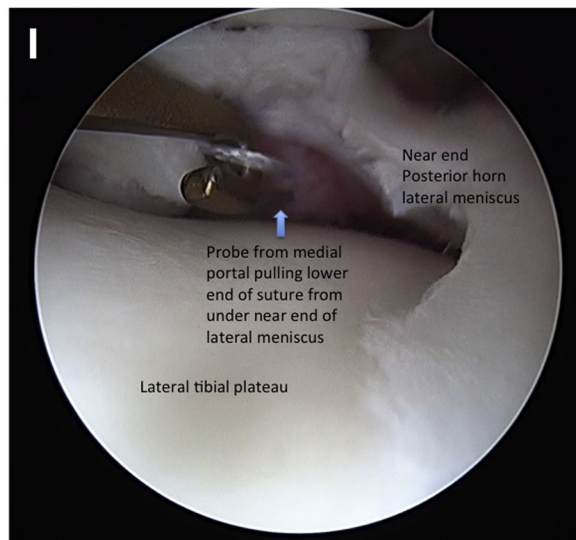
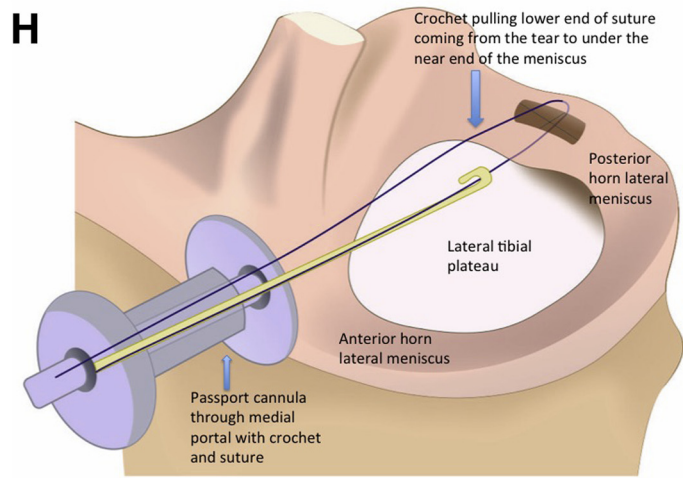
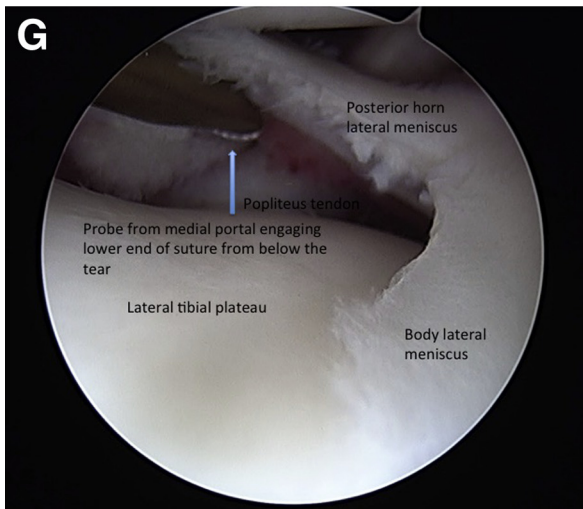
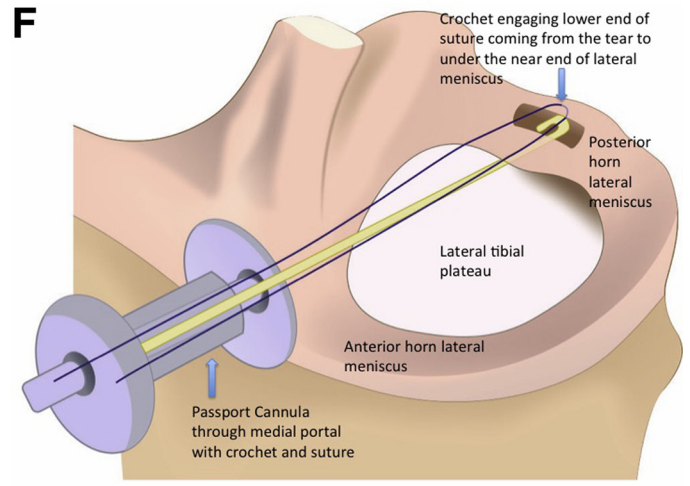
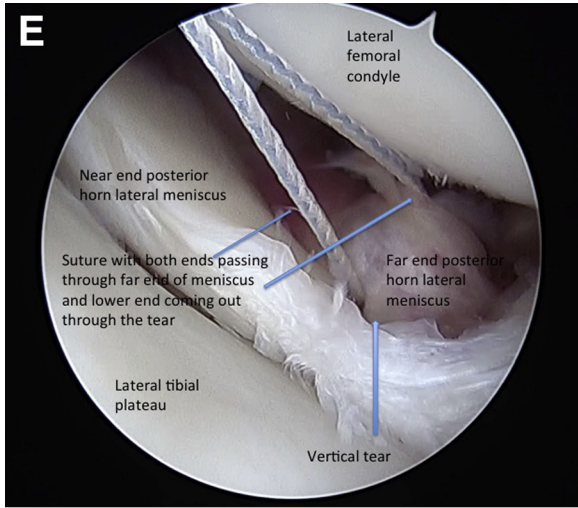



Fig 2. (continued).



**Fig 3.** The effective jaw length of Knee Scorpion is 10 mm.




(Fig 2 D and E). The scorpion is pulled back through the portal. The FiberWire is released from the Knee Scorpion. A crochet hook is introduced through portal B and is passed under the near end of the meniscus into the tear to secure the lower arm of the FiberWire (Fig 2 F and G) and retrieve it (Fig 2 H and I). This is then pulled under the meniscus and out through the PassPort Cannula. The next steps are the same as Technique A.

### Discussion

The inside-out technique of repair is a gold standard technique, especially for unstable tears. However, every technique has its own drawbacks. Here it needs an extra incision and dissection down to the capsule with possible risk of infection and neurovascular complications.<sup>3</sup> It also leaves nonabsorbable suture knots outside the capsule that could irritate the patient later on. Other all-inside techniques also use implants that anchor to the capsule and are delivered by long beveled tip needles that can potentially injure vital structures in the posterior and posterolateral aspects of

the knee. The all-inside technique described here has the advantage of less inventory and fewer chances of neurovascular complications with no implants in the capsule or beyond. The all-inside technique using suture anchors creates a fixed tension at the repair site, the technique described here provides better control of reduction through tensioning the 2 suture limbs. The length of the jaws of Knee Scorpion is 10 mm (Fig 3), and the average width of the posterior horn of lateral meniscus is 9.70 mm.<sup>8</sup> The height of the needle from where it exits to the tip of the jaw is about 5 mm (Fig 4). The meniscus is thinner toward the center and thicker toward the periphery with an average height of 5.36 mm,<sup>8</sup> which is about the height the needle of the Knee Scorpion. However, these dimensions vary and have been determined via magnetic resonance imaging measurements. When the tear is very peripheral, the jaws of the knee scorpion may not pass beyond the tear to catch the meniscal tissue peripheral to the tear. Also, the needle that comes through the jaws has a curvilinear path and does not make use of the full jaw length and hence cannot grasp the peripheral meniscus



**Fig 4.** The effective height of the jaws is 5 mm.

**Table 1.** Advantages and Disadvantages of This Technique

Advantages	Disadvantages
More cost-effective, as the Knee Scorpion is sterilizable. The only cost is the needle and 2-0 FiberWire. One 2-0 FiberWire can be used for up to 3 stitches.	More technically demanding with a longer learning curve as compared with other all-inside devices.
There is more control over tightening the knots, as it can be seen while tightening it.	In small tears of the posterior horn where the jaws of the Knee Scorpion cannot engage the peripheral part and Technique B is used, retrieving the lower end of the FiberWire from the tear to below the near end of the meniscus can be difficult, as the tear is not as mobile.
No implants in the capsule other than sutures.	Knots on the surface of the meniscus could potentially abrade the cartilage on the femoral side.
Less neurovascular complications, as no needle or implant is passed through the capsule into the posterior aspect of the knee where the popliteal artery or common peroneal nerve is.	Time taken is longer than other all-inside devices.
Inventory in operation room is less, as all that is needed in disposables is one Knee Scorpion needle and 2-0 FiberWires.	Needle used for multiple stitches could potentially lead to fatigue and can break.

tissue in tears that are very peripheral. Technique B describes a simple way to do the repair despite this problem, as bites through the periphery are taken through the tear. This is also a cost-effective technique of using a FiberWire only as compared with other devices used for all-inside fixation technique. The advantages and disadvantages as well as pearls and

pitfalls are described in [Tables 1](#) and [2](#). Techniques A and B are shown in [Video 1](#).

### Acknowledgments

The author thanks Dr. Jitendra Maheshwari and Dr. Ajay Singh for their help and support.

**Table 2.** Pearls and Pitfalls

Pearls	Pitfalls
Making a high medial working portal helps in reaching the lateral meniscus tear	Very low medial working portal can cause cartilage abrasion while introducing the Knee Scorpion and can be obstructed by the tibial spine preventing easy entry into the lateral compartment
Using a flexible cannula in the medial portal helps in maneuvering the Knee Scorpion intra-articularly	Using a hard cannula creates less maneuverability, and using no cannulas can cause a tissue bridge between the 2 ends of the meniscus
While loading the suture onto the Knee Scorpion, the loose end should be short so that it is easily delivered through the canula after the bite	Overzealously tightening the 2-0 FiberWire can potentially break it
Gently using the crochet to lift the meniscus up in Technique B makes the lower end of the suture more visible and easily deliverable below the near end of the meniscus	Not identifying the lower end of the suture passing through the far end of the meniscus can cause the suture to become entangled, preventing good knot security
Using a low-profile, smaller-diameter knot pusher helps, as it potentially has less chance of damaging the femoral condyle cartilage.	While delivering the lower end of the suture under the near end of the meniscus after taking a bite in the far end of the meniscus in Technique B, it is important that upper end of the suture is long enough and when the loop is pulled the correct arm of the loop is pulled as this could disengage the suture from the meniscus completely
Tying the knots more posteriorly on the meniscus potentially reduces damage on the articular cartilage	Simple knots are the preferred technique, with at least 3 knots, as they are easier to disengage if not secure enough, giving the surgeon another opportunity. This is not possible with a sliding knot, which needs to be cut completely if not satisfactorily tight
Depending on the location of the tear in the posterior horn of the lateral meniscus, the viewing and working portal may be interchanged	



## References

1. Nikolic DK. Lateral meniscus tears and their evolution in acute injuries of the anterior cruciate ligament of the knee. Arthroscopic analysis. *Knee Surg Sports Traumatol Arthrosc* 1998;6:26-30.
2. Lutz C, Dalmay F, Ehkirch FP, et al. Meniscectomy versus meniscal repair: 10 years radiological and clinical results in vertical lesions in stable knee. *Orthop Traumatol Surg Res* 2015;101:S327-S331.
3. Fillingham YA, Riboh JC, Erickson BJ, Bach BR, Yanke AB. Inside-out versus all-inside repair of isolated meniscal tears: An updated systematic review. *Am J Sports Med* 2016;45:234-242.
4. Bogunovic L, Kruse LK, Haas AK, Huston LJ, Wright RW. Outcome of all inside second generation meniscal repair: Minimum 5-year follow-up. *J Bone Joint Surg Am* 2014;96:1303-1307.
5. Woodmass JM, Krych AJ. Horizontal cleavage meniscus tear treated with all inside circumferential compression stitches. *Arthrosc Tech* 2017;6:1329-1333.
6. Smith PA, Bley JA. Simplified arthroscopic lateral meniscal root repair involving the use of 2 cinch loop sutures. *Arthrosc Tech* 2017;6:e73-e79.
7. Mhaskar VA, Mahehsuari J, Sansanwal M. Femoral avulsion of the anterior cruciate ligament in a multiligament setting: A unique case. *Knee Surg Rel Res* 2019;31:137.
8. Erbagci H, Gumusburun E, Bayram M, Karakurum G, Sirikchi A. The normal menisci: In vivo MRI measurements. *Surg Radiol Anat* 2004;26:28-32.