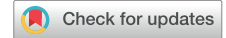

# IgM-Positive Tubulointerstitial Nephritis Associated With Asymptomatic Primary Biliary Cirrhosis



Shoko Mizoguchi<sup>1</sup>, Kan Katayama<sup>1</sup>, Tomohiro Murata<sup>1</sup>, Eiji Ishikawa<sup>1</sup>, Yuji Kozuka<sup>2</sup>, Yasuhiro Honda<sup>1</sup>, Keiko Oda<sup>1</sup>, Yosuke Hirabayashi<sup>1</sup>, Takayasu Ito<sup>1</sup> and Masaaki Ito<sup>1</sup>

<sup>1</sup>Department of Cardiology and Nephrology, Mie University Graduate School of Medicine, Tsu, Japan; and <sup>2</sup>Department of Pathology, Mie University Graduate School of Medicine, Tsu, Japan

**Correspondence:** Kan Katayama, Department of Cardiology and Nephrology, Mie University Graduate School of Medicine, 2-174 Edobashi, Tsu, Mie, 514-8507, Japan. E-mail: [katayamk@clin.medic.mie-u.ac.jp](mailto:katayamk@clin.medic.mie-u.ac.jp)

*Kidney Int Rep* (2018) 3, 1004–1009; <https://doi.org/10.1016/j.ekir.2018.04.001>

© 2018 International Society of Nephrology. Published by Elsevier Inc. This is an open access article under the CC BY-NC-ND license (<http://creativecommons.org/licenses/by-nc-nd/4.0/>).

## INTRODUCTION

Tubulointerstitial nephritis (TIN) is an inflammatory disorder in renal tubules and interstitium without the involvement of glomerular lesions.<sup>1</sup> TIN is often induced by drugs and infections, but idiopathic or systemic disease-related forms have also been observed.<sup>2</sup>

Primary biliary cirrhosis (PBC) is an immune-mediated chronic and progressive cholestatic liver disease.<sup>3</sup> Laboratory data show increased serum values of alkaline phosphatase,  $\gamma$ -glutamyl transpeptidase, and IgM. The hallmark of the disease is the circulating antimitochondrial antibody (AMA). PBC is often associated with extrahepatic autoimmune disorders, such as Sjögren syndrome, thyroid disorders, systemic sclerosis, and rheumatoid arthritis.<sup>4</sup>

Although distal renal tubular acidosis (RTA) has been observed in 33% to 60% of PBC patients,<sup>5,6</sup> TIN and subsequent Fanconi syndrome are relatively rare.<sup>7</sup> We report herein a case of TIN associated with asymptomatic PBC, which was diagnosed after 4 years of treatment for TIN and Fanconi syndrome.

## CASE REPORT

A 57-year-old woman who had not had any abnormality previously was found to have proteinuria on a health checkup 7 years earlier; however, she did not visit a doctor. She developed general malaise and saw her general practitioner 4 years ago. Because urinary examinations revealed proteinuria and glycosuria, she was referred to our hospital for further evaluation. Her height was 160 cm, and her body weight was 59 kg. Her blood pressure was 114/83 mm Hg, and her pulse

was 72/min. Physical examination revealed no abnormality except for mild bilateral lower-leg edema. Goiter was not palpable. Laboratory data are listed in [Table 1](#). Urinary examinations showed no cylinders, and pan-aminoaciduria was detected. Serum concentrations of iron, copper, magnesium, cadmium, aluminum, chromium, and cobalt were within normal ranges. The Fishberg concentration test showed decreased renal concentration capacity, and a bicarbonate ion tolerance test showed decreased tubular transport maximum for  $\text{HCO}_3^-$ . The percent tubular reabsorption of phosphate (%TRP) was low at 63.8% (reference value 85%–95%). There were no signs of osteomalacia on bone scintigraphy. There were no abnormalities of bone marrow puncture. She was clinically diagnosed with Fanconi syndrome and distal renal tubular acidosis.

The first renal biopsy showed 8 instances of global sclerosis among 15 glomeruli. There were no cases of mesangial proliferation, extracapillary proliferative lesions, or adhesion. Severe lymphocyte infiltration in the tubulointerstitial area was noted, accompanied by tubular atrophy ([Figure 1a](#), upper-left panel). She was diagnosed with idiopathic TIN and treated with 50 mg of prednisolone daily. Her serum Cr level temporarily improved from 1.7 to 1.15 mg/dl, but it increased to 1.46 mg/dl during tapering of prednisolone. Urinary  $\beta_2$ mg increased from 16,000 to 47,456  $\mu\text{g/l}$ , and serum IgM increased from 133 to 959 mg/dl. She was admitted to our hospital again for evaluation of her renal dysfunction.

Laboratory data at the second admission showed hypophosphatemia and a high titer of anti-mitochondrial M2 antibody with normal liver enzymes ([Table 1](#)). The second renal biopsy showed global sclerosis in 26 of 51 glomeruli. Severe

**Table 1.** Laboratory data at the first and second admissions

	First	Second		First	Second
Urinary examination			Blood chemistry		
pH (4.5–7.5)	7	8	HbA1c (%; 4.9–6.0)	5.2	5.3
Protein (g/gCr)	1.49	1.36	Glu (mg/dl; 73–109)	98	88
Occult blood	(±)	(–)	TP (g/dl; 6.6–8.1)	7.9	6.7
Glucose (mg/dl)	250	250	Alb (g/dl; 4.1–5.1)	4.4	3.9
$\beta_2$ mg ( $\mu$ g/l; 5–253)	42700	47456	BUN (mg/dl; 8–20)	14	13.9
NAG (U/l; 1.0–4.2)	5.7	6.6	Cr (mg/dl; 0.46–0.79)	1.56	1.46
BJP	(–)	(–)	eGFR (ml/min per 1.73 m <sup>2</sup> )	28.1	29.7
			UA (mg/dl; 2.6–5.5)	2.2	1.9
Complete blood count			Na (mEq/l; 138–145)	139	140
WBC ( $\mu$ l; 3300–8600)	6790	9250	K (mEq/l; 3.6–4.8)	3.6	3.8
RBC ( $\times 10^4/\mu$ l; 386–492)	454	454	Cl (mEq/l; 101–108)	112	109
Hb (g/dl; 11.6–14.8)	14.4	14.1	HCO <sub>3</sub> <sup>–</sup> (mmol/l)	18.6	17.7
Plt ( $\times 10^4/\mu$ l; 15.8–34.8)	26.9	30	Ca (mg/dl; 8.8–10.1)	9.4	8.8
			IP (mg/dl; 2.7–4.6)	2.6	2.1
Serology			AST (U/l; 13–30)	29	19
TSH ( $\mu$ U/ml; 0.38–4.31)	12.43	4.75	ALT (U/l; 7–23)	29	16
fT3 (pg/ml; 1.9–3.8)	2.4	2.7	LDH (U/l; 124–222)	232	283
fT4 (ng/dl; 0.82–1.63)	0.76	0.96	ALP (U/l; 106–322)	517	283
ANA	1.40	ND	$\gamma$ -GTP (U/l; 9–32)	36	31
Anti-M2 (U/ml; <7)	ND	>400	T. bil (mg/dl; 0.4–1.5)	0.4	0.6
MPO-ANCA (U/ml; 0–8.9)	<1.3	ND	IgG (mg/dl; 861–1747)	1180	588
PR3-ANCA (U/ml; 0–3.4)	<1.3	ND	IgA (mg/dl; 93–393)	95.6	71
Anti-SS-A (0–29.9)	<5	ND	IgM (mg/dl; 50–269)	890	959
Anti-SS-B (0–24.9)	<5	ND	IgG4 (mg/dl; 4–108)	55	ND

Alb, albumin; ALP, alkaline phosphatase; ALT, alanine transaminase; ANA, antinuclear antibody; AST, aspartate transaminase;  $\beta_2$ mg,  $\beta_2$ -microglobulin; BJP, Bence Jones protein; BUN, blood urea nitrogen; Ca, calcium; Cl, chloride; Cr, creatinine; eGFR, estimated glomerular filtration rate; fT3, free triiodothyronine; fT4, free thyroxine; Glu, glucose;  $\gamma$ -GTP,  $\gamma$ -glutamyl transpeptidase; Hb, hemoglobin; HbA1c, hemoglobin A1c; HCO<sub>3</sub><sup>–</sup>, bicarbonate ion; IP, inorganic phosphate; K, potassium; LDH, lactate dehydrogenase; MPO-ANCA, myeloperoxidase antineutrophil cytoplasmic antibody; Na, sodium; NAG, *N*-acetyl- $\beta$ -D-glucosaminidase; ND, not done; Plt, platelets; PR3-ANCA, proteinase-3-antineutrophil cytoplasmic antibody; RBC, red blood cells; T. bil, total bilirubin; TP, total protein; TSH, thyroid stimulating hormone; UA, uric acid; WBC, white blood cells.

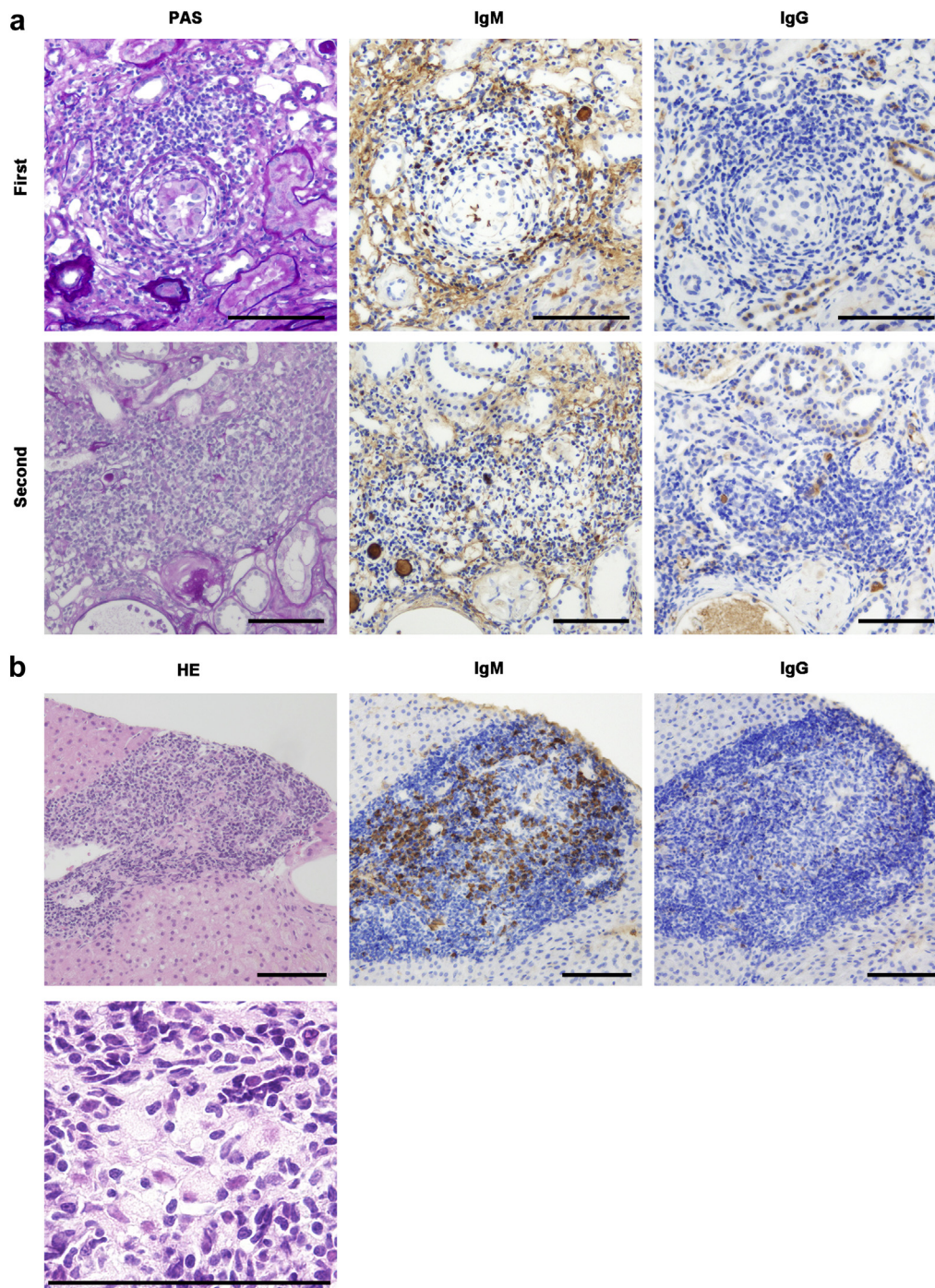
lymphocyte infiltration in the tubulointerstitial area was not improved (Figure 1a, lower-left panel). IgM-positive cells were more dominantly observed than IgG-positive cells (Figure 1a). A liver biopsy revealed epithelioid granuloma formation and inflammatory cell infiltration surrounding the bile ducts, which was compatible with PBC (Figure 1b). IgM-positive cells were abundant, whereas IgG-positive cells were scarce in the liver (Figure 1b). To further define the types of cells, immunohistochemical staining with cluster of differentiation (CD)3, a marker for T lymphocytes, CD20, a marker for B lymphocytes, and CD138, a marker for plasma cells, was performed. CD3-positive cells were mixed with CD20- or CD138-positive cells in the tubulointerstitial area on the first renal biopsy, and CD138-positive cells were more abundant than CD20-positive cells (Figure 2, upper panels). On the second renal biopsy, CD3-positive cells were more dominantly observed than CD20- or CD138-positive cells in the tubulointerstitial area (Figure 2, middle panels). On the liver biopsy, CD3-positive cells were mixed with CD20- or CD138-positive cells in the inflammatory cell infiltrates (Figure 2, lower panels).

Because the serum Cr, IgM, and urinary  $\beta_2$ mg levels increased during prednisolone tapering, i.v.

administration of 500 mg of methylprednisolone per day for 3 consecutive days, followed by 10 mg of prednisolone daily, was initiated. The patient's serum Cr, IgM, and urinary  $\beta_2$ mg levels improved, and, at the time of writing, her renal function has been stable without recurrence for 2 years.

## DISCUSSION

We report herein a patient treated for TIN and Fanconi syndrome who was diagnosed with asymptomatic PBC 4 years later. The antinuclear antibody titer was low, and the serum concentrations of various metal ions were normal at the first admission. As she was not taking any medicines and had no infections, she was diagnosed with idiopathic TIN. Hematological disorders were suspected based on her high serum IgM level, but there were no obvious findings from a bone marrow puncture. Because the serum IgM level improved after the administration of prednisolone, no further investigation was performed. During prednisolone tapering, the patient's serum Cr level as well as her serum IgM or urinary  $\beta_2$ mg levels increased again. Antimitochondrial M2 antibody was positive at the second admission, and a liver biopsy confirmed the diagnosis of PBC. Severe lymphocyte infiltration in the tubulointerstitial area was not improved at the second renal biopsy.

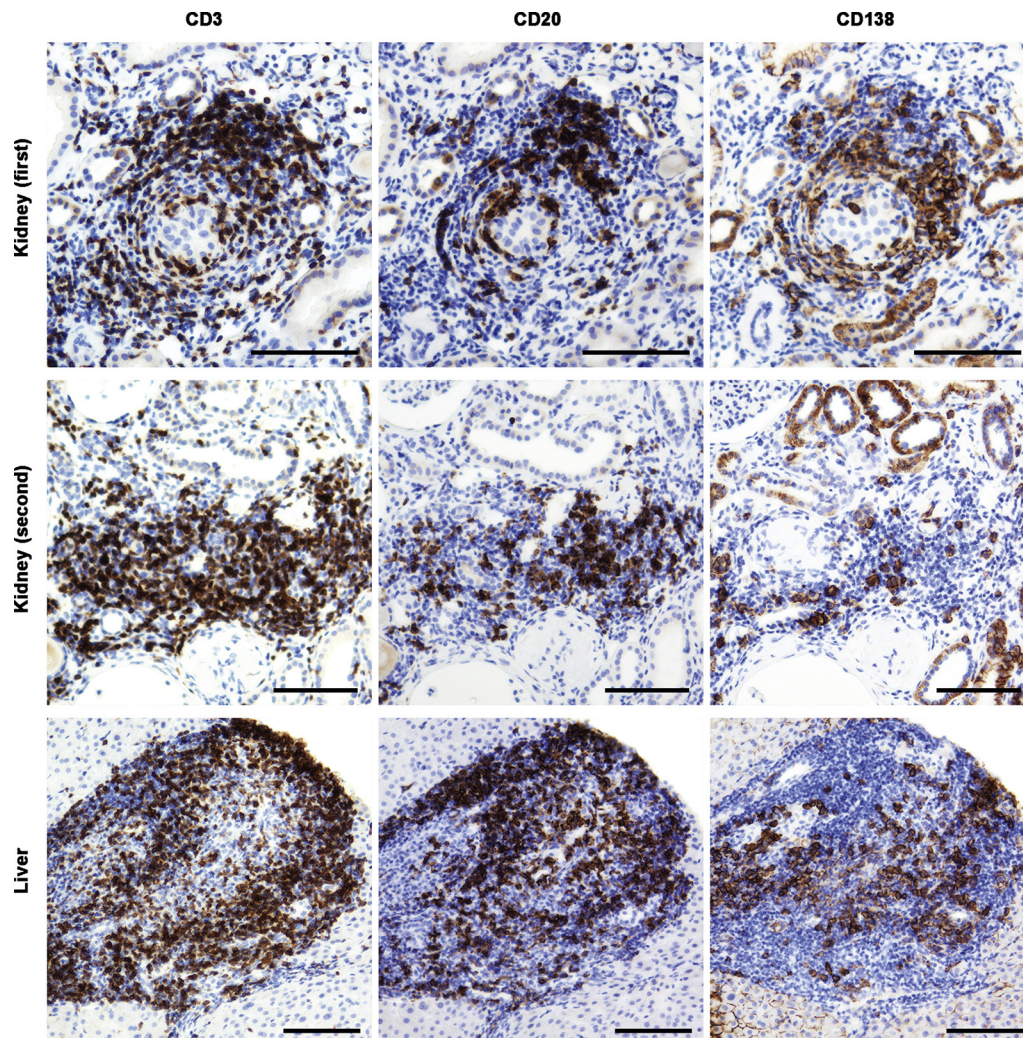


**Figure 1.** (a) Renal histology findings on the first and the second admissions. Periodic acid–Schiff (PAS) staining showed severe lymphocyte infiltration in the tubulointerstitial area accompanied by tubular atrophy at the first admission, and the infiltration in the tubulointerstitial area was not improved at the second admission. IgM-positive cells were dominantly observed than IgG-positive cells in the tubulointerstitial area. Bars = 100  $\mu$ m. (b) Hepatic histology findings at the second admission. Hematoxylin and eosin (HE) staining of a liver biopsy specimen showed inflammatory cell infiltration surrounding the bile ducts at a low magnification and epithelioid granuloma formation at a high magnification. Although there were many IgM-positive cells, IgG-positive cells were scarce. Bars = 100  $\mu$ m.

We searched for articles written in English in PubMed with the terms “renal tubular acidosis primary biliary cirrhosis” or “tubulointerstitial nephritis primary biliary cirrhosis” or “Fanconi syndrome primary biliary cirrhosis.” Among the 13 articles found that described TIN with PBC, we excluded 4 because a

renal biopsy was not performed in 2 articles and the other 2 articles described cases that were complicated with Sjögren syndrome. We included 2 cases from an article of a 13-case series that was published recently because the 2 cases were PBC without Sjögren’s syndrome.<sup>8</sup> There were 16 similar cases, including our own





**Figure 2.** At the first admission, CD3-positive cells were mixed with CD20- or CD138-positive cells in the tubulointerstitial area. CD138-positive cells were more abundant in the tubulointerstitial area than CD20-positive cells. At the second admission, CD3-positive cells were more dominantly observed than CD20- or CD138-positive cells in the tubulointerstitial area. In the liver, CD3-positive cells were mixed with CD20- or CD138-positive cells in the inflammatory cell infiltrates. Bars = 100  $\mu$ m.

**Table 2.** Summary of the reported cases of tubulointerstitial nephritis with primary biliary cirrhosis

	Age/sex	U- $\beta_2$ mg ( $\mu$ g/l)	U-NAG (U/l)	Urine pH	sCr (mg/dl)	AST (U/l)	ALT (U/l)	ALP (U/l)	$\gamma$ GTP (U/l)	IgM (mg/dl)	AMA	M2A	FS	OM
Macdougall <i>et al.</i> <sup>1</sup> 1987	50/F	NA	NA	NA	2	NA	NA	117	NA	630	800	NA	x	x
Kodama <i>et al.</i> <sup>9</sup> 1996	36/F	NA	NA	NA	0.8	19	14	83	32	1260	640	(-)	o	x
Lino <i>et al.</i> <sup>10</sup> 2005, pat 1	51/F	25 mg/24 h	NA	6.5	1.8	41	67	107	53	NA	NA	800	o	o
Lino <i>et al.</i> <sup>10</sup> 2005, pat 2	68/F	57 mg/24 h	NA	6	1.3	25	34	276	51	NA	NA	640	o	o
Terrier <i>et al.</i> <sup>11</sup> 2008	42/F	263,000	NA	NA	1.3	3N	2N	4.5N	3.5N	358	NA	200	o	o
Komatsuda <i>et al.</i> <sup>7</sup> 2010, pat 1	36/F	10,595	NA	7.3	0.8	19	14	83	32	1260	640	(-)	o	x
Komatsuda <i>et al.</i> <sup>7</sup> 2010, pat 2	66/F	84,400	21.1	6.3	1.5	20	10	290	13	663	80	178	o	x
Komatsuda <i>et al.</i> <sup>7</sup> 2010, pat 3	77/F	15,586	2.5	7	1.4	32	19	152	37	74	20	40	x	x
Komatsuda <i>et al.</i> <sup>7</sup> 2010, pat 4	52/F	60,000	7.4	7.5	1.5	25	19	812	24	665	320	157	o	x
Bansal <i>et al.</i> <sup>12</sup> 2012	46/F	NA	NA	NA	2.3	NA	NA	209	252	NA	(+)	(+)	x	x
Iwakura <i>et al.</i> <sup>13</sup> 2013	46/F	20,975	11.1	NA	1.1	38	50	694	190	966	160	143	x	x
Rasolzadegan <i>et al.</i> <sup>14</sup> 2014	28/F	NA	NA	NA	2	185	138	NA	698	NA	(-)	19.5	x	x
Yamaguchi <i>et al.</i> <sup>15</sup> 2015	49/F	NA	NA	6	1.4	23	24	663	18	1084	NA	10	o	o
Takahashi <i>et al.</i> <sup>8</sup> 2017, pat 12	44/F	69,359	NA	NA	1.4	NA	NA	1559	56	1284	NA	562	o	x
Takahashi <i>et al.</i> <sup>8</sup> 2017, pat 13	56/F	66,987	NA	NA	2.7	NA	NA	806	178	2045	(-)	10	o	x
Present case	57/F	47,456	6.6	8	1.5	19	16	283	31	959	40	400	o	x

ALP, alkaline phosphatase; ALT, alanine transaminase; AMA, anti-mitochondrial antibody; AST, aspartate transaminase; F, female; FS, Fanconi syndrome;  $\gamma$ GTP,  $\gamma$ -glutamyl transpeptidase; M, male; M2A, anti-mitochondrial M2 antibody, NA, not available; OM, osteomalacia; pat, patient; sCr, serum creatinine; U- $\beta_2$ mg, urinary  $\beta_2$ -microglobulin; U-NAG, urinary *N*-acetyl- $\beta$ -D-glucosaminidase; o, yes; x, no.

**Table 3.** Summary of the outcome data for the reported cases of tubulointerstitial nephritis with primary biliary cirrhosis

	Prednisolone (mg)	Follow-up period	Final sCr (mg/dl)	Relapse
Macdougall <i>et al.</i> <sup>1</sup> 1987	40	11 mo	1.9	Yes
Kodama <i>et al.</i> <sup>9</sup> 1996	NA	NA	NA	NA
Lino <i>et al.</i> <sup>10</sup> 2005, pat 1	0.5/kg	1 yr	1.6	No
Lino <i>et al.</i> <sup>10</sup> 2005, pat 2	0.5/kg	NA	2.3	No
Terrier <i>et al.</i> <sup>11</sup> 2008	1/kg	3 mo	1.1	No
Komatsuda <sup>7</sup> 2010, pat 1	25–30	16 yr	0.6	No
Komatsuda <i>et al.</i> <sup>7</sup> 2010, pat 2	25–30	11 yr	1.7	No
Komatsuda <i>et al.</i> <sup>7</sup> 2010, pat 3	25–30	1 yr	1.5	No
Komatsuda <i>et al.</i> <sup>7</sup> 2010, pat 4	25–30	0.5 yr	1	No
Bansal <i>et al.</i> <sup>12</sup> 2012	40	5 mo	NA	No
Iwakura <i>et al.</i> <sup>13</sup> 2013	NU	NA	NA	NA
Rasolzadegan <i>et al.</i> <sup>14</sup> 2014	NA	2 yr	NA	No
Yamaguchi <i>et al.</i> <sup>15</sup> 2015	20	1 yr	NA	No
Takahashi <i>et al.</i> <sup>8</sup> 2017, pat 12	20	0.8 yr	1.4	No
Takahashi <i>et al.</i> <sup>8</sup> 2017, pat 13	30	0.2 yr	2	No
Present case	Methylprednisolone 500 mg ×3	2 yr	1.3	No

NA, not available; NU, not used; pat, patient; sCr, serum creatinine.

(Table 2).<sup>1,7–15</sup> All 16 patients were female, and 11 were diagnosed with Fanconi syndrome. Of the 16 patients, 12 did not have osteomalacia.

The long-term use of corticosteroids in patients with PBC is contraindicated because of the progression of osteoporosis. However, treatment with corticosteroids was successful when the patients had TIN, and the common dose was 0.5 to 1 mg/kg per day (Table 3). We started treating our patient with 0.8 mg/kg per day of prednisolone. Although TIN temporarily improved after the treatment, it deteriorated during prednisolone tapering. Relapse of TIN after prednisolone tapering seemed to be rare, as only 1 case has been reported (by Macdougall *et al.*<sup>1</sup>) aside from the present case (Table 3). Because we judged TIN still to be active based on the findings of the second renal biopsy, we performed methylprednisolone pulse therapy, and the TIN improved. To our knowledge, this is the first reported case of TIN with PBC in a patient who was successfully treated with steroid pulse therapy. Bisphosphonates were used to prevent osteoporosis, and the bone density of the lumbar spine was 129% compared to the average in women of the same age.

Takahashi *et al.* recently reported a disease group of TIN with high serum IgM levels.<sup>8</sup> The investigators observed CD138- and IgM-double-positive plasma cells in the tubulointerstitial area. In the present case, IgM-positive cells were more dominantly observed than IgG-positive cells in both the kidney and the liver. Although we were unable to perform double staining with CD138 and IgM, CD138-positive cells were also predominantly observed in the first renal biopsy, and we surmised that some of these cells were positive for IgM.

In conclusion, we diagnosed a rare case of IgM-positive TIN associated with asymptomatic PBC.

## DISCLOSURE

MI received departmental scholarship funds of ≥1,000,000 yen per year for direct expenses from Merck Sharp & Dohme K.K., Bristol-Myers Squibb, BIOTORONIK JAPAN, Inc., Astellas Pharma Inc., Shionogi & Co., Ltd., and Otsuka Pharmaceutical Co., Ltd., in 2015, Merck Sharp & Dohme K.K., Astellas Pharma Inc., Takeda Pharmaceutical Company, Ltd., Daiichi Sankyo Company, Ltd., and Otsuka Pharmaceutical Co., Ltd., in 2016, and Merck Sharp & Dohme K.K., Shionogi & Co., Otsuka Pharmaceutical Co., Ltd., Takeda Pharmaceutical Company, Ltd., and Daiichi Sankyo Company, Ltd., in 2017. The companies associated with this funding were not involved in the manuscript preparation or the decision to publish the present case report. All the other authors declared no competing interests.

## AUTHOR CONTRIBUTIONS

SM and TM took clinical care of the patient and participated in the acquisition of clinical data. SM, KK, TM, EI, and YK carried out analysis of patient's clinical course and data interpretation. SM and KK wrote a draft of the manuscript and TM, EI, YK, YHo, KO, YHi, TI, and MI revised it critically. All authors read and approved the final manuscript.

## REFERENCES

- Macdougall IC, Isles CG, Whitworth JA, et al. Interstitial nephritis and primary biliary cirrhosis: a new association? *Clin Nephrol.* 1987;27:36–40.
- Praga M, González E. Acute interstitial nephritis. *Kidney Int.* 2010;77:956–961.

3. Bhandari BM, Bayat H, Rothstein KD. Primary biliary cirrhosis. *Gastroenterol Clin North Am*. 2011;40:373–386.
4. Chalifou SL, Konyn PG, Choi G, et al. Extrahepatic manifestations of primary biliary cholangitis. *Gut Liver*. 2017;11:771–780.
5. Golding PL, Mason AS. Renal tubular acidosis and autoimmune liver disease. *Gut*. 1971;12:153–157.
6. Pares A, Rimola A, Bruguera M, et al. Renal tubular acidosis in primary biliary cirrhosis. *Gastroenterology*. 1981;80:681–686.
7. Komatsuda A, Wakui H, Ohtani H, et al. Tubulointerstitial nephritis and renal tubular acidosis of different types are rare but important complications of primary biliary cirrhosis. *Nephrol Dial Transplant*. 2010;25:3575–3579.
8. Takahashi N, Saeki T, Komatsuda A, et al. Tubulointerstitial nephritis with IgM-positive plasma cells. *J Am Soc Nephrol*. 2017;28:3688–3698.
9. Kodama T, Imai H, Wakui H, et al. Tubulointerstitial nephritis with renal tubular acidosis and asymptomatic primary biliary cirrhosis accompanied by antibody to a 52-kDa mitochondrial protein alone. *Clin Nephrol*. 1996;45:401–405.
10. Lino M, Binaut R, Noel LH, et al. Tubulointerstitial nephritis and Fanconi syndrome in primary biliary cirrhosis. *Am J Kidney Dis*. 2005;46:e41–e46.
11. Terrier B, Fakhouri F, Berezne A, et al. Osteomalacia revealing celiac disease and primary biliary cirrhosis-related Fanconi syndrome in a patient with systemic sclerosis. *Clin Exp Rheumatol*. 2008;26:467–470.
12. Bansal T, Takou A, Khwaja A. Progressive chronic kidney disease secondary to tubulointerstitial nephritis in primary biliary cirrhosis. *Clin Kidney J*. 2012;5:442–444.
13. Iwakura T, Fujigaki Y, Matsuyama T, et al. Tubulointerstitial nephritis and primary biliary cirrhosis with a T cell-dominant profile of infiltrating cells and granulomas in both organs. *Intern Med*. 2013;52:467–471.
14. Rasolzadegan MH, Bakhshayesh H, Amid N. Tubulointerstitial nephritis associated with primary biliary cirrhosis. *J Nephroarmacol*. 2014;3:29–31.
15. Yamaguchi S, Maruyama T, Wakino S, et al. A case of severe osteomalacia caused by tubulointerstitial nephritis with Fanconi syndrome in asymptomatic primary biliary cirrhosis. *BMC Nephrol*. 2015;16:187.