



Magnetic Resonance Imaging in Ootosyphilis: A Rare Manifestation of Neurosyphilis

Rajsekar Chandrasekharan¹  Chinmay Kulkarni¹ Sreekumar Karumathil Pullara¹ Srikanth Moorthy¹ 

¹Department of Radiology, Amrita Institute of Medical Sciences and Research Centre, Kochi, Kerala

Address for correspondence Rajsekar Chandrasekharan, Hyde Park villa (AN 10), Ferry junction, Ellookara road, Mupathadam P.O. Aluva, Ernakulam, Kerala 683110, India (e-mail: raj462750@gmail.com).

Indian J Radiol Imaging 2022;32:278–284.

Abstract

We report magnetic resonance imaging (MRI) in a case with otosyphilis, which is a rare manifestation of neurosyphilis. A 50-year-old male presented with progressive hearing loss on the left side and recent-onset palsy of the left 7th and 12th cranial nerves. Computed tomography imaging showed destructive bone lesions involving the petrous temporal bone, middle ear, and mastoid region with a pathognomonic pattern of bone destruction depicted in the volume rendering technique images. MRI showed features of destructive bone lesions (gummatous lesion), meningoneuritis, and labyrinthitis. Pathological examination and treponemal antibody absorption test favored the diagnosis. Otosyphilis should be considered as a differential diagnosis in an adult patient with destructive lesions of the petrous temporal bone. To the best of our knowledge, MRI in otosyphilis has not been reported.

Keywords

- ▶ gummatous lesions
- ▶ labyrinthitis
- ▶ meningoneuritis
- ▶ neurosyphilis
- ▶ otosyphilis

A 50-year-old man presented with gradually progressive hearing diminution in the left ear of 9 months duration. It was associated with occasional tinnitus. There was no ear pain, discharge, or fever. It gradually progressed to near total hearing loss. Two months later he noticed difficulty in closing the left eye. Two days later, he started having drooling of food and saliva through the left side of angle of mouth. There was no history of nasal regurgitation, or choking. He had history of pulmonary tuberculosis 10 years back. Cranial nerve examination revealed a left facial nerve and left 12th cranial nerve palsy with normal palatal movement. Otoscopy revealed minimal tympanic membrane bulge and audiogram showed moderate high-frequency mixed hearing loss.

Magnetic resonance imaging (MRI) showed T2-weighted (T2W) hyperintense lesions in the left petrous temporal bone and the mastoid region with a T2W intermediate to hypointense extra-axial lesion at the left cerebellopontine region (▶ Fig. 1A, B). Contrast scan showed homogeneously enhancing dural-based soft tissue lesion in the premedullary cistern

and cerebellopontine region extending into the left internal acoustic meatus and jugular foramen. Enhancing soft tissue foci were also seen in the left petrous temporal bone, middle ear, and mastoid along with the involvement of the labyrinth and the cochlear duct (▶ Fig. 2). There was edema involving the adjacent left cerebellum without any enhancing parenchymal lesions.

Temporal bone computed tomography (CT) showed conglomerate lytic lesions in the middle ear and mastoid air cells (▶ Fig. 3). In three-dimensional volume rendering technique images, the lesions showed an unusual worm-shaped appearance of irregular bone destruction predominantly involving the petrous apex and mastoid region (▶ Fig. 4). There was erosion of the incus with suspicious erosion of the head of the malleus. There was no erosion of the otic capsule. Diffuse sclerosis of the mastoid along with diploe widening and sclerosis of the adjacent squamous temporal bone was seen.

Positron emission tomography (PET) CT imaging showed focal FDG (fluorodeoxyglucose)-avid extraosseous lesions

published online
June 30, 2022

DOI <https://doi.org/10.1055/s-0042-1744523>.
ISSN 0971-3026.

© 2022. Indian Radiological Association. All rights reserved.

This is an open access article published by Thieme under the terms of the Creative Commons Attribution-NonDerivative-NonCommercial-License, permitting copying and reproduction so long as the original work is given appropriate credit. Contents may not be used for commercial purposes, or adapted, remixed, transformed or built upon. (<https://creativecommons.org/licenses/by-nc-nd/4.0/>)

Thieme Medical and Scientific Publishers Pvt. Ltd., A-12, 2nd Floor, Sector 2, Noida-201301 UP, India

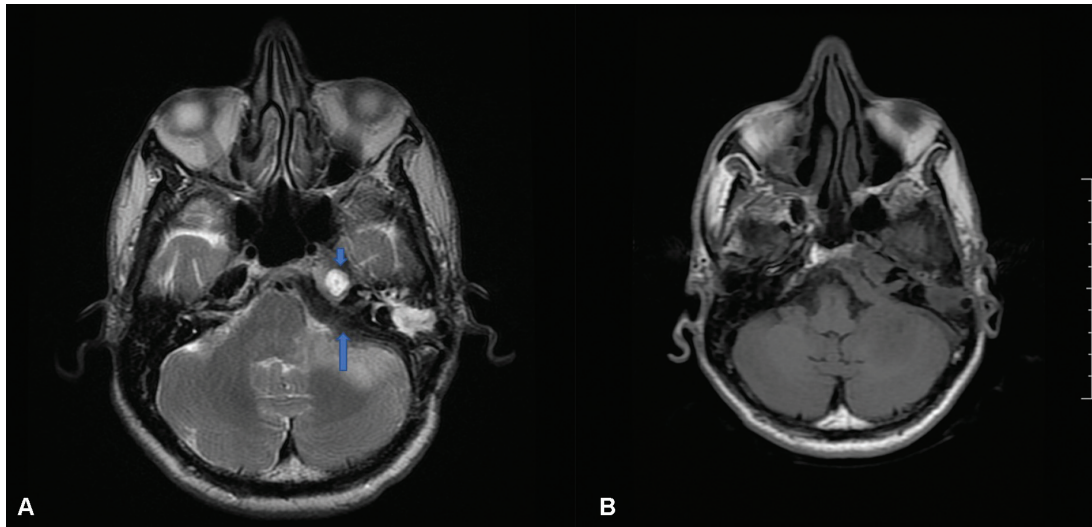


Fig. 1 (A) T2W axial images show hyperintense lesions in the left petrous temporal bone (*short arrow*) and the mastoid region with a T2W hypointense extra-axial lesion at the left cerebellopontine region (*long arrow*). (B) T1W images show isointense signal intensity corresponding to the lesions at the petrous mastoid region and the cerebellopontine region. T1W, T1 weighted.

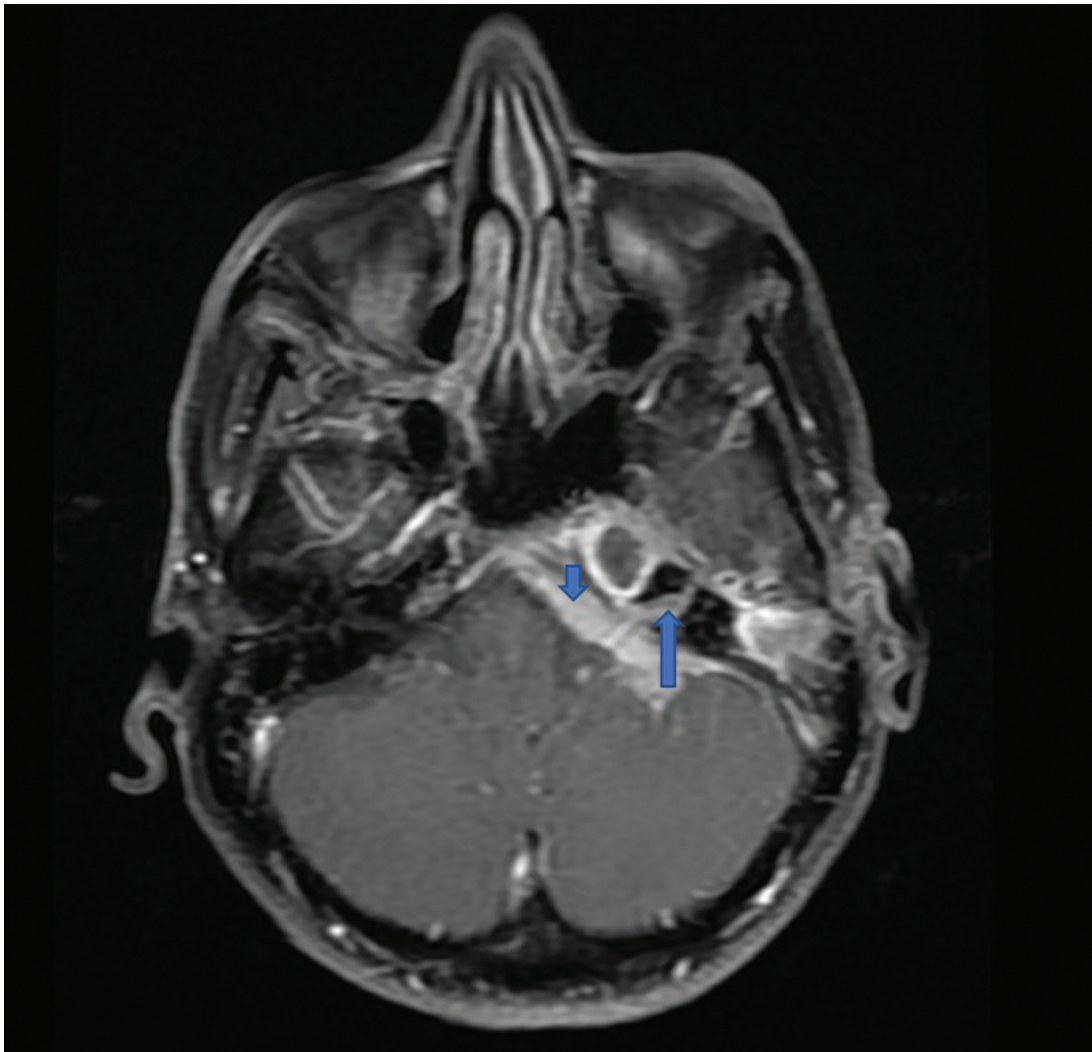


Fig. 2 This figure shows homogeneously enhancing dural-based soft tissue lesion (*short arrow*) in the premedullary cistern and cerebellopontine region extending to the ipsilateral internal acoustic meatus. Enhancing lesions (*long arrow*) in the petromastoid region with enhancement of the vestibulocochlear nerve.

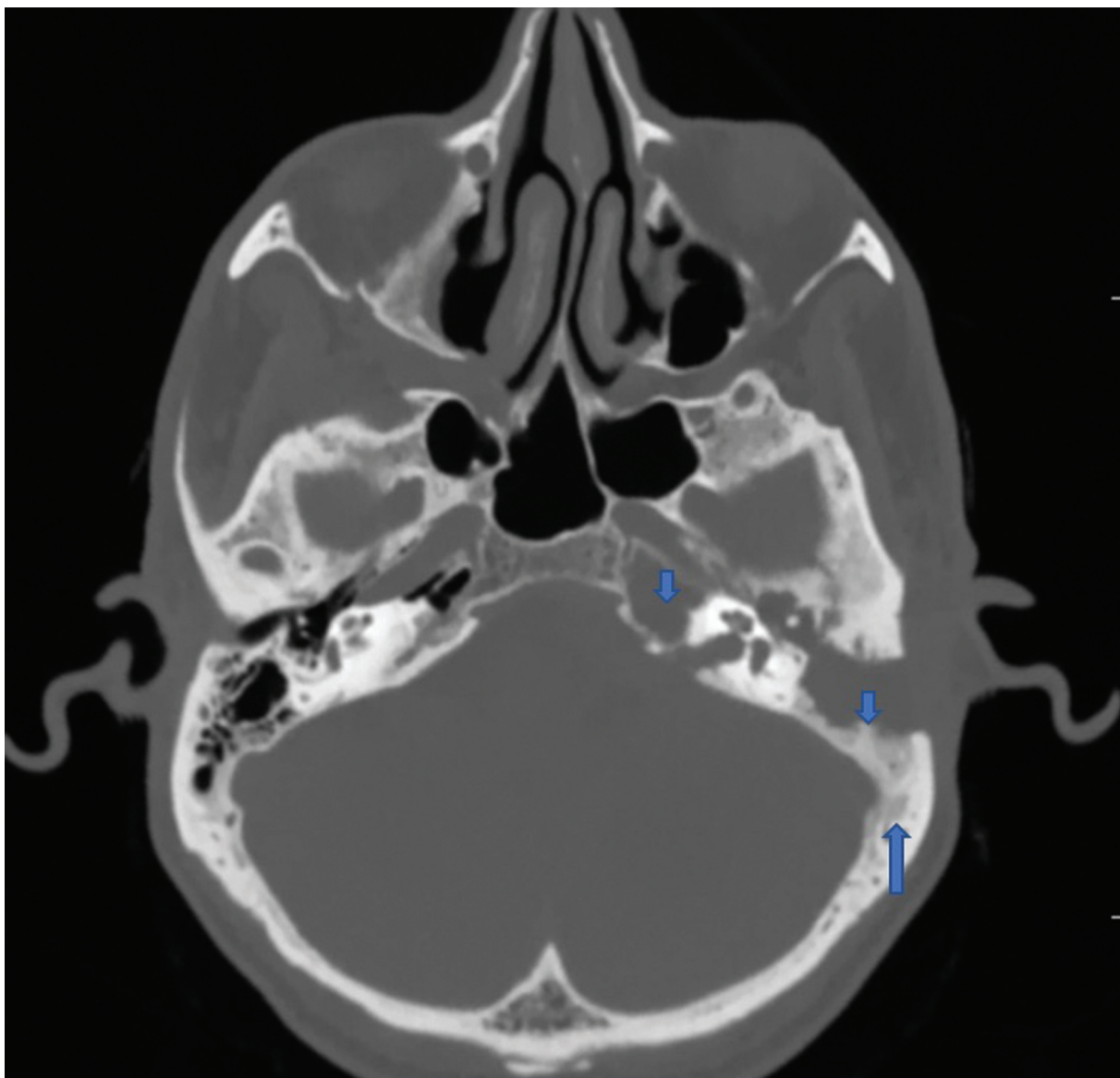


Fig. 3 This figure shows conglomerate lytic sclerotic lesions (*short arrows*) in the left petrous temporal bone, middle ear, and mastoid air cells. Diffuse sclerosis noted with diploe widening seen at the left mastoid and adjacent squamous temporal bone.

(**Fig. 5**) and minimally FDG-avid erosions at the petrous part of the temporal bone. There was no PET uptake in the brain or any other part of the body. *Differential diagnosis that was considered based on imaging includes cholesteatoma, squamous cell carcinoma, skull-based osteomyelitis and secondaries.*

Patient underwent craniotomy and dural biopsy. Pathological examination showed fragments of tissues, with moderate to dense inflammation composed predominantly of plasma cells and lymphocytes. Occasional histiocytes and neutrophils were noted. Exuberant vascular proliferation was seen with prominent endothelial cells. There was one focus of endarteritis obliterans evident and no microorganisms were seen. EVG stain highlighted the endarteritis obliterans (**Fig. 6**). Immunohistochemistry for Kappa and Lambda showed a polyclonal population. The report suggested possibility of syphilis.

A reactive quantitative rapid plasma reagin (RPR) titer measured 1:128, and a fluorescence treponemal antibody absorption test was positive. The patient was treated with intravenous penicillin G, 4 million units every 4 hours for 6 weeks. There was mild improvement in the hearing and other cranial nerve symptoms. There was a drop in the RPR titer to 1:36 after 6 weeks of treatment which empirically confirmed the diagnosis of syphilis. Follow-up review after 2 months showed some improvement in the cranial nerve palsies but the hearing loss had not improved further. A follow-up MRI showed significant reduction in size of the extradural soft tissue at the premedullary cistern and cerebellopontine angle. There was significant reduction in the enhancement in the inner ear. Based on clinical, serological, and imaging findings of gummatous lesions in the temporal bone, meningoneuritis, and labyrinthitis, a final diagnosis of otosyphilis was established.

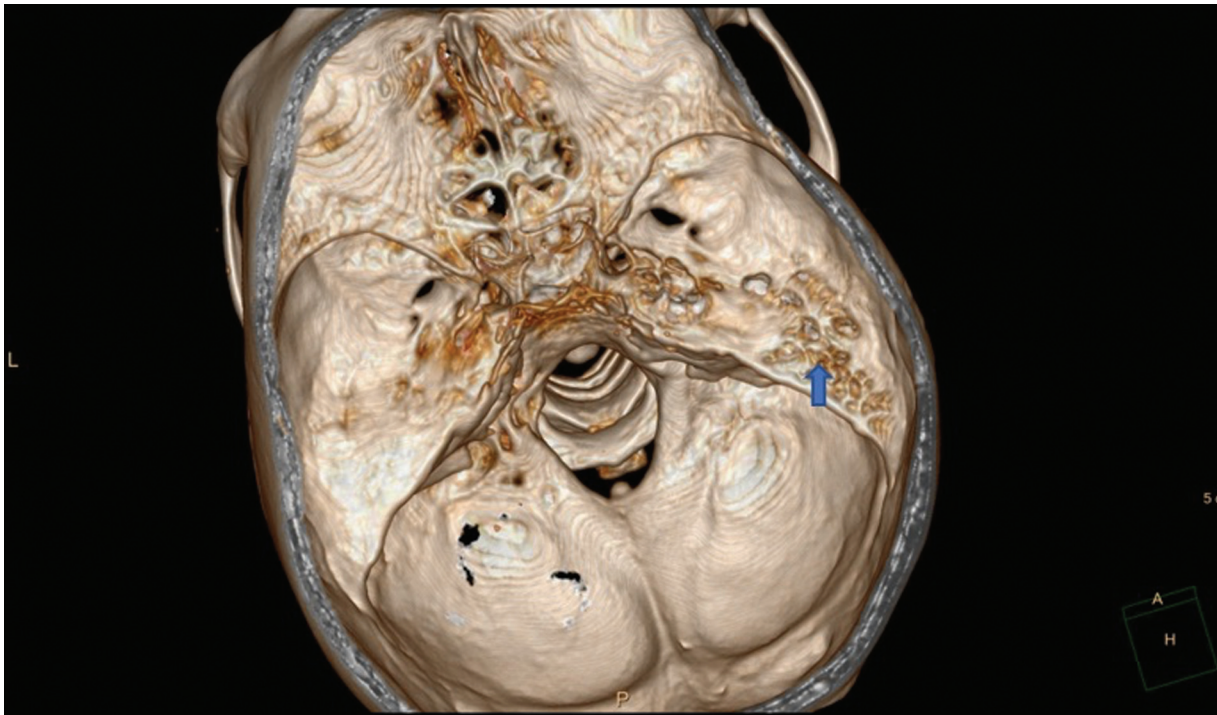


Fig. 4 VRT images showing worm-shaped appearance (*short arrow*) of irregular bone destruction predominantly involving the petrous apex. VRT, volume rendering technique.

Discussion

Syphilis is a complex systemic illness with clinical manifestations caused by the spirochete *Treponema pallidum*. Syphilis can be classified into four stages according to the clinical manifestations of the disease. These include primary, secondary, latent syphilis, and tertiary syphilis.¹

Primary stage occurs 3 to 4 weeks after exposure and presents with the painless chancre.

Secondary stage presents usually with rashes that occurs 4 to 8 weeks after that latent syphilis is the asymptomatic stage. Tertiary stage may present with cardiovascular and neurological manifestations.

Neurosyphilis is a common clinical manifestation in the tertiary stage that can present with meningitis and encephalitis. The central nervous system involvement in syphilis patients is classified into four syndromes: syphilitic meningitis, meningovascular syphilis, parenchymatous, and gummatous neurosyphilis.²

Otosyphilis may present as a destructive bone disease that may be accompanied by systemic manifestations of syphilis. Involvement of the inner ear is recognized in the late congenital, late latent, and tertiary stages of syphilis.³ Ootosyphilis can manifest as a gummatous lesion of the internal auditory canal, a labyrinthitis, or a luetic osteitis. Other typical pathologic findings are osteomyelitis and periostitis. Histopathologically, otosyphilis is characterized by obliterative endarteritis, multinucleated giant cell, and round cell infiltration. Symptoms may be ranging from sudden or insidious reversible hearing loss, tinnitus, and vestibular symptoms ranging from dizziness to vertigo. *Meniere's dis-*

*ease is close differential diagnosis of this condition with similar clinical and pathological findings.*⁴

When spirochetemia occurs in syphilis, the organisms can infect the deeper vascular areas of the periosteum, with eventual extension into the Haversian canals and medullary spaces, resulting in periostitis, osteitis, or osteomyelitis. Disease progression can develop into osteolytic or osteoblastic changes in the bones, often with superficial bone involvement.⁵ The tumor-like gummatous lesion with formation of the granulation tissue is due to excessive response of the cell-mediated immune system to *T. pallidum*. Gummata are uncommon and usually develop in the dura and pia mater over the cerebral convexity or at the base of brain. In otosyphilis imaging, features like osteitis and osteolysis may be seen in the temporal bone and gummata in the internal auditory canal.⁶ CT features show irregular bone destruction preferentially involving the outer table of the skull with unusual "worm-eaten" pattern that is considered characteristic of calvarial syphilitic involvement on conventional radiographic and gross pathologic assessment.⁵ Single or multiple masses attached to the dura mater can invade the brain parenchyma with development of symptoms similar to that of primary neuroparenchymal tumors. *Other conditions that can mimic such imaging findings include malignancies such as lymphoma, squamous cell carcinoma, cholesteatoma, and infections like chronic otitis media.* Ogungbemi et al reported patients with acquired syphilis who had bilateral hearing loss with CT showing features of luetic osteitis of temporal bone. *In syphilitic meningitis common imaging features may include leptomenigeal enhancement, cranial nerve involvement (such as 7th and 8th nerve), focal pachymeningitis, and syphilitic myelitis.*⁶ *Meningovascular syphilis may present as large*

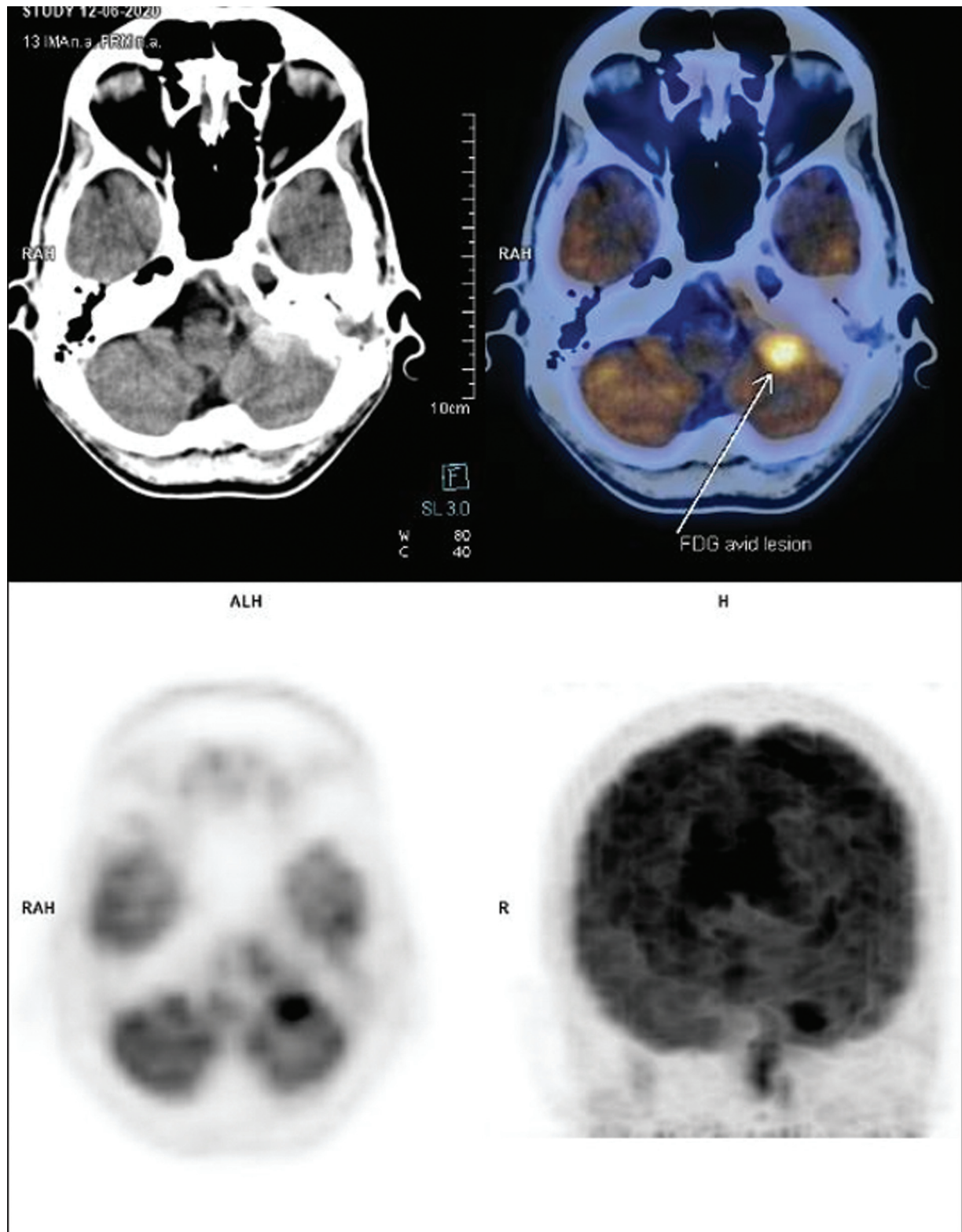


Fig. 5 PET-CT imaging shows high metabolic uptake area (long arrow) corresponding to the enhancing extradural lesion cerebellopontine and premedullary region with no extension to the adjacent cerebellum. PET-CT, positron emission tomography-computed tomography.

vascular infarcts in cortical and subcortical locations.⁶ In our case multiple gummatous lesions were seen in the petrous part of temporal bone sparing the otic capsule. The linear extra-axial enhancing soft tissue adjacent to the premedullary and cerebellopontine cisterns could represent the meningeal involve-

ment (syphilitic meningitis) which correlated with the positive fluorescence treponemal antibody absorption test of the CSF. The bone destruction was demonstrated better by the volume-rendered imaging (using 1-mm thin reconstructed images) than in conventional bone window. Erosions of the otic capsule

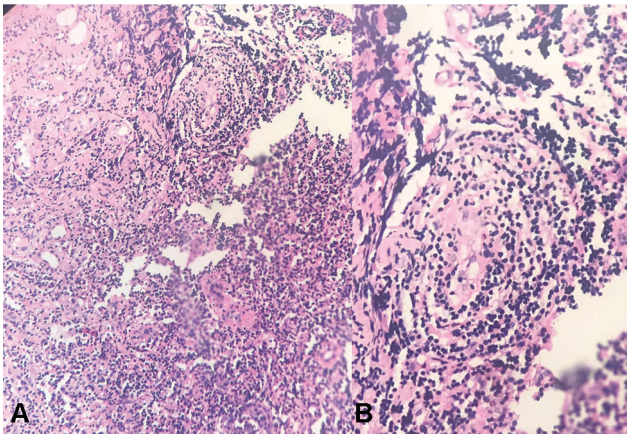


Fig. 6 (A) Pathological examination shows inflammation composed predominantly of plasma cells and lymphocytes with focus of exuberant vascular proliferation seen with very prominent endothelial cells. (B) High power of the end arteritis obliterans.

and moth-eaten demineralization of the temporal bone have been described in the literature.⁷ On MRI, the gummatous lesions are reported to be isointense relative to the gray matter in T1W images, hyperintense in T2W images, and show enhancement in postcontrast imaging. *In summary, otosyphilis can present as a manifestation in early neurosyphilis with or without meningitis or meningovascular manifestation. Imaging presentation in otosyphilis may be variable depending on the manifestations and hence correlation with the serology becomes mandatory for diagnosis.* To the best of our knowledge, MRI in otosyphilis has not been reported previously.

Otosyphilis, though rare, should be considered as the differential diagnosis of a destructive lesion of the petrous bone with or without adjacent meningeal involvement.

Conflict of Interest

There is no conflict of interest among the authors regarding the research paper. No disclosures to make.

References

- 1 Fundamentals of Sexually Transmitted Infections. Syphilis (Chapter 6) . Ayşegül Sevim Keçi. Department of Dermatology, University of Medical Sciences, Haydarpaşa Numune Training and Research Hospital, Istanbul, Turkey Available at: <http://dx.doi.org/10.5772/intechopen.70282> Accessed March 28 2020
- 2 Chu M, Lu Y. MRI of neurosyphilis presenting as brain tumor: A case report. *Radiol Infect Dis* 2015;2(04):197–200
- 3 Gurland IA, Korn L, Edelman L, Wallach F. An unusual manifestation of acquired syphilis. *Clin Infect Dis* 2001;32(04):667–669
- 4 Smith AB, Smirniotopoulos JG, Rushing EJ. From the archives of the AFIP: central nervous system infections associated with human immunodeficiency virus infection: radiologic-pathologic correlation. *Radiographics* 2008;28(07):2033–2058
- 5 Thompson RG, Preston RH. Lesions of the skull in secondary syphilis. *Am J Syph Gonorrhea Vener Dis* 1952;36(04):332–341
- 6 Brightbill TC, Ihmeidan IH, Post MJ, Berger JR, Katz DA. Neurosyphilis in HIV-positive and HIV-negative patients: neuroimaging findings. *AJNR Am J Neuroradiol* 1995;16(04):703–711
- 7 Sonne JE, Zeifer B, Linstrom C. Manifestations of otosyphilis as visualized with computed tomography. *Otol Neurotol* 2002; 23:806–807
- 8 Ogungbemi A, Dudau C, Morley Set al. Computed tomography features of luetic osteitis (otosyphilis) of the temporal bone. *J Laryngol Otol* 2014;128:185–188