

Endoscopic Resection of Localized Pigmented Villonodular Synovitis in the Hoffa Fat Pad



Andrew Ka Hei Fan, M.B.B.S. (H.K.), and Tun Hing Lui, M.B.B.S. (H.K.)

Abstract: Pathologies within the fat pad can have either intrinsic or extrinsic causes. Most of them are the consequences of trauma and degeneration, but inflammatory and neoplastic diseases can arise in the fat pad. Pigmented villonodular synovitis is the most common space-occupying lesion of the Hoffa fat pad, followed by ganglion. The purpose of this Technical Note is to describe the details of endoscopic resection of localized pigmented villonodular synovitis in the Hoffa fat pad. Hopefully, this can allow complete resection of the lesion with minimal surgical trauma and scar tissue formation.

The Hoffa fat pad is an intracapsular but extrasynovial structure.¹ Abnormalities within the fat pad most commonly are the consequences of trauma and degeneration, but inflammatory and neoplastic diseases can arise in the fat pad.¹ Pathologies can be either intrinsic or extrinsic to this fat pad.² Intrinsic pathologies include Hoffa disease, intracapsular chondroma, localized nodular synovitis, or postsurgery or post-traumatic fibrosis. Extrinsic pathologies include articular disorders (e.g., meniscal cyst), synovial abnormalities (e.g., pigmented villonodular synovitis [PVNS]), and anterior extracapsular abnormalities.²

PVNS is a rare, benign, proliferative neoplastic condition characterized by hypertrophy of a synovial membrane by villous, nodular, and villonodular proliferation, with pigmentation secondary to hemosiderin deposition.³ The lesion can be diffuse or localized, with similar histologic features but different clinical presentation, prognosis, and response to treatment.³ Diffuse PVNS tends to have a more rapidly destructive course, and as a result, has a poorer

prognosis.³ Total resection of the lesion is still the gold standard.⁴ This can be done either with open surgery or arthroscopically, depending on location, type, surrounding structure involvement, and invasiveness.⁴ Despite total resection with acceptable margins, there is a risk of recurrence of about 40%.⁴ Extra-articular diffuse PVNS can encroach on major neurovascular structures, making surgical excision more challenging and complete excision difficult.³ In contrast, localized PVNS has a greater chance to be completely resected arthroscopically.

PVNS is the most common space-occupying lesion of the Hoffa fat pad, followed by ganglion.⁵ This extra-articular space is readily accessible by the endoscopic approach.⁶⁻⁸ This report describes the technical details of endoscopic resection of localized PVNS in the Hoffa fat pad. It is indicated for localized PVNS in the Hoffa fat pad. This procedure is contraindicated if the lesion invades the patellar tendon or it is diffuse PVNS extended from the knee joint (Table 1).

Technique

Preoperative Planning and Patient Positioning

Preoperative magnetic resonance imaging of the knee is essential to confirm the diagnosis and localization of

Table 1. Indications and Contraindications of Endoscopic Resection of Localized PVNS in the Hoffa Fat Pad

Indications
Localized PVNS in the Hoffa fat pad.
Contraindications
The PVNS lesion invades the patellar tendon.
It is diffuse PVNS extended from the knee joint.
PVNS, pigmented villonodular synovitis.

From the Department of Orthopaedics and Traumatology, United Christian Hospital (A.K.H.F.), and Department of Orthopaedics and Traumatology, North District Hospital (T.H.L.), Hong Kong SAR, China.

The authors report that they have no conflicts of interest in the authorship and publication of this article. Full ICMJE author disclosure forms are available for this article online, as [supplementary material](#).

Received June 7, 2019; accepted July 4, 2019.

Address correspondence to Tun Hing Lui, M.B.B.S. (H.K.), Department of Orthopaedics and Traumatology, North District Hospital, 9 Po Kin Road, Sheung Shui, NT, Hong Kong SAR, China. E-mail: luithderek@yahoo.co.uk

© 2019 by the Arthroscopy Association of North America. Published by Elsevier. This is an open access article under the CC BY-NC-ND license (<http://creativecommons.org/licenses/by-nc-nd/4.0/>).

2212-6287/19739

<https://doi.org/10.1016/j.eats.2019.07.005>

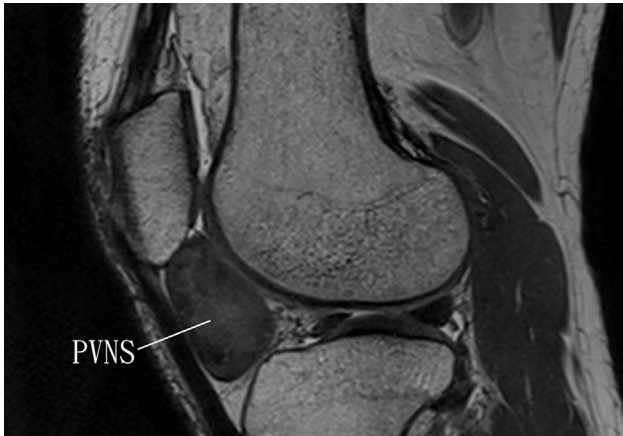


Fig 1. Endoscopic resection of localized pigmented villonodular synovitis (PVNS) in the Hoffa fat pad of the right knee. The patient is in the supine position. Preoperative magnetic resonance imaging of the illustrated knee demonstrated localized PVNS of the Hoffa fat pad.

the lesion (Fig 1). The patient is placed in the supine position. A thigh tourniquet is applied to provide a bloodless operative field. A 4.0-mm 30° arthroscope (DYONICS; Smith & Nephew, Andover, MA) is used for this procedure. Fluid inflow is by gravity, and no arthropump is used.

Portal Placement

The anteromedial and anterolateral portals of knee arthroscopy are used for this procedure. The anteromedial portal is 1 cm above the medial joint line and 1 cm medial to the patellar tendon. The anterolateral

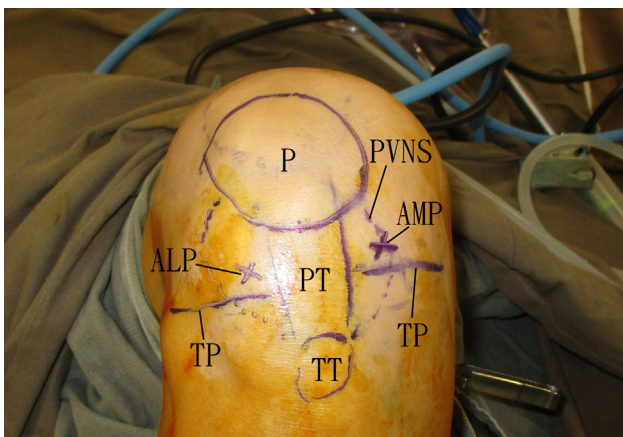


Fig 2. Endoscopic resection of localized PVNS in the Hoffa fat pad of the right knee. The patient is in the supine position. The anteromedial and anterolateral portals of knee arthroscopy are used for this procedure. The anteromedial portal is 1 cm above the medial joint line and 1 cm medial to the patellar tendon. The anterolateral portal is 1 cm above the lateral joint line and 1 cm lateral to the patellar tendon. (ALP, anterolateral portal; AMP, anteromedial portal; P, patella; PT, patellar tendon; PVNS, boundary of the localized pigmented villonodular synovitis; TP, tibial plateau; TT, tibial tuberosity.)

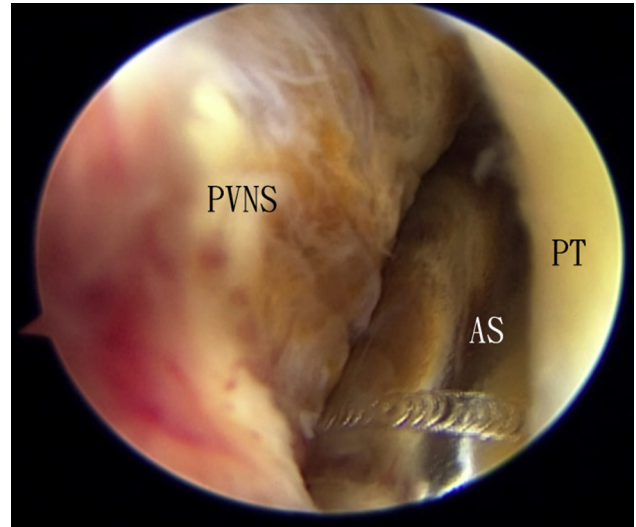


Fig 3. Endoscopic resection of localized PVNS in the Hoffa fat pad of the right knee. The patient is in the supine position. The anterolateral portal is the viewing portal and the anteromedial portal is the working portal. Resection starts at the anterior surface of the lesion by means of an arthroscopic shaver. (AS, arthroscopic shaver; PT, patellar tendon; PVNS, pigmented villonodular synovitis.)

portal is 1 cm above the lateral joint line and 1 cm lateral to the patellar tendon (Fig 2). Five-millimeter incisions are made at the portal sites. The deep surface of the patellar tendon is bluntly dissected with a hemostat, and this is the initial endoscopic working space of this procedure.

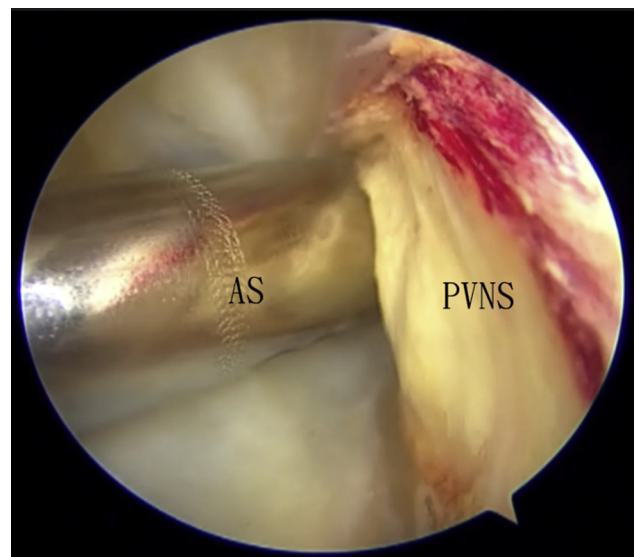


Fig 4. Endoscopic resection of localized PVNS in the Hoffa fat pad of the right knee. The patient is in the supine position. The anteromedial portal is the viewing portal and the anterolateral portal is the working portal. The resection starts at the lateral edge of the lesion. (AS, arthroscopic shaver; PVNS, pigmented villonodular synovitis.)

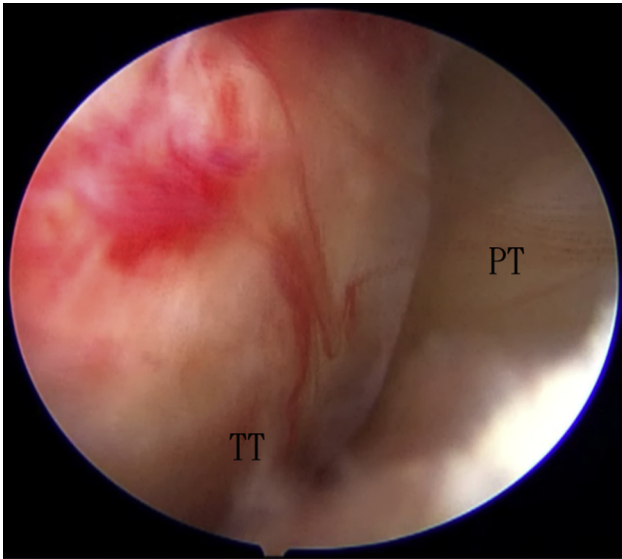


Fig 5. Endoscopic resection of localized PVNS in the Hoffa fat pad of the right knee. The patient is in the supine position. The anterolateral portal is the viewing portal. After resection of the PVNS, the whole span of Hoffa fat pad is examined for any residual lesion. (PT, patellar tendon; PVNS, pigmented villonodular synovitis; TT, tibial tuberosity.)

Endoscopic Resection of PVNS in the Hoffa Fat Pad

The anteromedial and anterolateral portals are interchangeable as the viewing and working portals for resection of PVNS in the Hoffa fat pad. The anterolateral portal is the viewing portal and the anteromedial portal

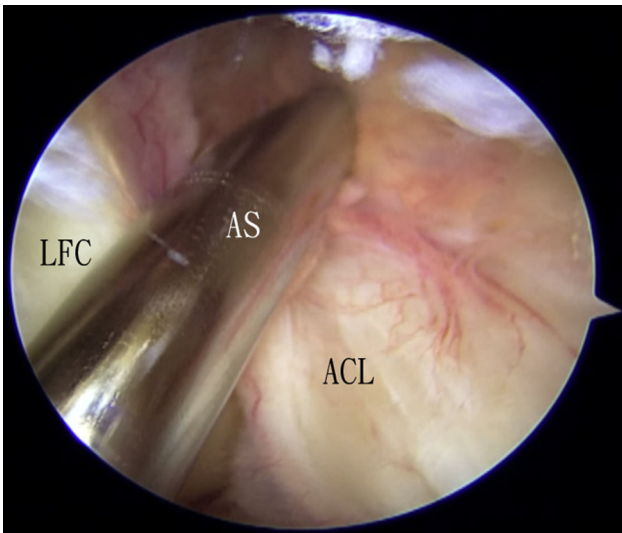


Fig 6. Endoscopic resection of localized PVNS in the Hoffa fat pad of the right knee. The patient is in the supine position. The anteromedial portal is the viewing portal and the anterolateral portal is the working portal. The knee joint is examined and any inflamed synovium is resected. Any PVNS fragments dropped into the joint are removed. (ACL, anterior cruciate ligament; AS, arthroscopic shaver; LFC, lateral femoral condyle; PVNS, pigmented villonodular synovitis.)

Table 2. Pearls and Pitfalls of Endoscopic Resection of Localized PVNS in the Hoffa Fat Pad

Pearls

Resection of the PVNS from its anterior surface can enlarge the initial endoscopic working space, which can facilitate subsequent identification of the medial and lateral edges of the lesion.

Resection of the PVNS always starts at its edges towards the center of the lesion. This can reduce the chance of incomplete resection.

Pitfalls

Fragments of the PVNS may drop into the knee joint.

PVNS, pigmented villonodular synovitis.

is the working portal. Resection starts at the anterior surface of the lesion by means of an arthroscopic shaver (DYONICS; Smith & Nephew) (Fig 3). This increases the working space. After that, the medial edge of the lesion can be identified. Resection of the medial half of the lesion starts at its medial edge with an arthroscopic punch forceps (Arthrex, Naples, FL) and shaver.

The anteromedial portal is the viewing portal and the anterolateral portal is the working portal. The lateral edge of the lesion is identified (Fig 4). Resection of the remaining lesion continues from its edges by means of the punch forceps, shaver, and Kerrison rougeur. After resection of the PVNS, the whole span of Hoffa fat pad is examined for any residual lesion (Fig 5).

Knee Arthroscopy

Frequently, the lining of the knee joint is breached during resection of the lesion. Fragments of PVNS may drop into the joint proper. Knee arthroscopy is performed via the anteromedial and anterolateral portals, and these PVNS fragments are removed. The knee joint is examined and any inflamed synovium is resected (Fig 6, Video 1, Table 2).

Discussion

The goal of surgical management of PVNS is complete resection. However, there is a significant risk of recurrence despite total resection with acceptable margins.⁴ Theoretically, a wide margin of resection can further reduce the risk of recurrence. However, it may not be possible for PVNS in the Hoffa fat pad because it is bounded anteriorly by the patellar tendon and posteriorly by the knee joint. Both structures are not sacrificable. The patient should be informed about the risk of recurrence.

Table 3. Advantages and Risks of Endoscopic Resection of Localized PVNS in the Hoffa Fat Pad

Advantages

Better cosmetic result

Less pain

Less surgical trauma

Risks

Injury to the infrapatellar branch of saphenous nerve

Seeding of PVNS into the knee joint proper

PVNS, pigmented villonodular synovitis.

Endoscopic resection of localized PVNS in the Hoffa fat pad has the advantages of better cosmetic result, less pain, and less surgical trauma. The potential risks of this technique include injury to the infrapatellar branch of saphenous nerve and seeding of PVNS into the knee joint proper (Table 3). This technique is not technically demanding and can be attempted by the average knee arthroscopist.

References

1. Albergio JI, Gaston CL, Davies M, et al. Hoffa's fat pad tumours: What do we know about them? *Int Orthop* 2013;37:2225-2229.
2. Jacobson JA, Lenchik L, Ruhoy MK, Schweitzer ME, Resnick D. MR imaging of the infrapatellar fat pad of Hoffa. *Radiographics* 1997;17:675-691.
3. Simonetta R, Florio M, Familiari F, Gasparini G, Rosa MA. All-arthroscopic treatment of intra- and extra-articular localized villonodular synovitis of knee. *Joints* 2017;5:184-187.
4. Daoud J, Aouad D, Hassan Y, El Rassi G. Localized pigmented villonodular synovitis of the posterior knee compartment with popliteal vessel compression: A case report of arthroscopic resection using only anterior knee portals. *Case Rep Orthop* 2018;2018:7532358.
5. Dean BJF, Reed DW, Matthews JJ, et al. The management of solitary tumours of Hoffa's fat pad. *Knee* 2011;18:67-70.
6. Lui TH. Endoscopic resection of lipoma of the patellar tendon. *Arthrosc Tech* 2015;4:e19-e22.
7. Lui TH. Endoscopic resection of gouty tophus of the patellar tendon. *Arthrosc Tech* 2015;4:e379-e382.
8. Chechik O, Amar E, Khashan M, Morag G. Giant cell tumors in the patellar tendon area. *J Knee Surg* 2010;23:115-119.