

The superior eyelid crease approach with retroseptal dissection: A modified access to the superomedial intraconal space. Treatment of a cavernous hemangioma: Case report and literature review

ABSTRACT

The orbit can be affected by primary intraconal lesions as well as cavernous hemangiomas. This article illustrates for the first time the retroseptal dissection (RD) route combined to the superior eyelid crease approach (SECA) to treat a symptomatic hemangioma inside the superomedial intraconal space. It also reviews the main studies about the argument. A 42-year-old woman affected by a mild painful proptosis and some accommodation difficulties in her right eye. The magnetic resonance imaging revealed a soft intraconal mass in the superomedial quadrant of the right orbit. The lesion was removed performing a SECA with RD through an incision inside a natural eyelid crease. Disappearance of pain with an improvement of accommodation was reported immediately. During the whole follow-up, the visual acuity, field examinations, and ocular motility did not reveal any impairment. Our approach represents a valid, quick, not technically demanding and mini-invasive method to access the superomedial intraconal space. Finally, it gives excellent functional and cosmetic results.

Keywords: Case report, literature review, proptosis, retroseptal dissection, superior eyelid crease approach, superomedial intraconal hemangioma

INTRODUCTION

Cavernous hemangiomas (CHs) are the most common benign vascular tumor of the head and neck. One of the most involved regions is the orbit. Observation is indicated in not growing asymptomatic lesions while surgical treatment is always indicated in symptomatic cases.^[1]

In this report, the authors present a symptomatic case of a superomedial intraconal CH, successfully treated by surgical removal through a superior eyelid crease approach (SECA). The novelty is that it has been combined it with a new pathway to reach the superomedial intraconal space: the retroseptal dissection (RD) route [Figure 1]. This case report has been reported in line with the SCARE criteria.

CASE REPORT

A 42-year-old female was referred to us because of a mild, axial, and painful proptosis in the right eyeball without visual field loss and diplopia. The patient declared only

FRANCESCO DE FEUDIS, RICCARDO GIROTTO, PAOLO BALERCIA

Division of Maxillofacial Surgery, Department of Neurological Sciences, University Hospitals of Ancona, Ancona, Italy


Address for correspondence: Dr. Francesco De Feudis, Division of Maxillofacial Surgery, Department of Neurological Sciences, University Hospitals of Ancona, Via Conca 71, 60126, Ancona, Italy.
E-mail: franc.de.feudis@gmail.com

Received: 13 June 2021, **Revised:** 18 July 2021, **Accepted:** 25 August 2021, **Published:** 13 December 2021

This is an open access journal, and articles are distributed under the terms of the Creative Commons Attribution-NonCommercial-ShareAlike 4.0 License, which allows others to remix, tweak, and build upon the work non-commercially, as long as appropriate credit is given and the new creations are licensed under the identical terms.

For reprints contact: WKHLRPMedknow_reprints@wolterskluwer.com

How to cite this article: De Feudis F, Girotto R, Balercia P. The superior eyelid crease approach with retroseptal dissection: A modified access to the superomedial intraconal space. Treatment of a cavernous hemangioma: Case report and literature review. Natl J Maxillofac Surg 2021;12:410-3.

Access this article online	
Website: www.njms.in	Quick Response Code 
DOI: 10.4103/njms.NJMS_420_21	

worsening at short distance accommodation in the right eye. The magnetic resonance imaging (MRI) revealed a neoplasm in the right intraconal area, behind the eyeball, dislocating the optical nerve [Figure 2a and b]. According

to the neuroradiologist and our clinical evaluation, the lesion could be a hemangioma. Therefore, considering the location, the anatomic relationships and the sizes,^[2] the patient was candidate to remove the tumor through a SECARD.

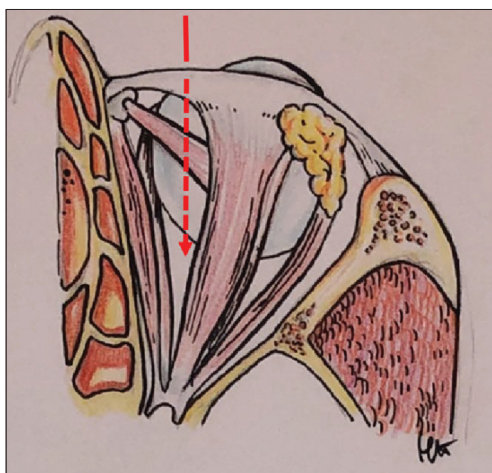


Figure 1: Illustration of the dissection pathway through the superior eyelid approach with retroseptal dissection to access the superomedial intraconal space. The continuous arrow shows the direction toward the space; the dashed arrow demonstrates the path once the eyelid is passed

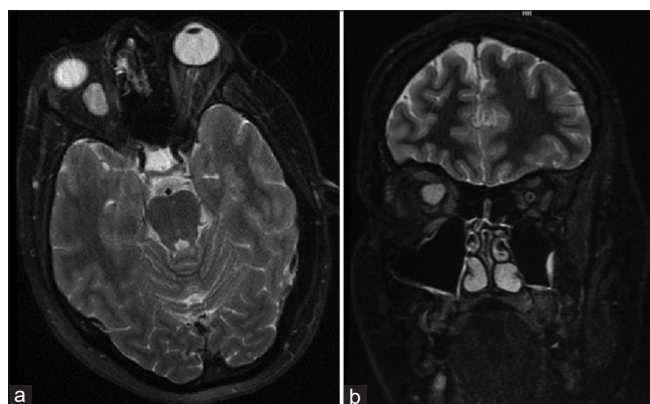


Figure 2: Preoperative magnetic resonance imaging with contrast showing the mass inside the superomedial intraconal space, behind the right globe, between the optic nerve and the external ocular muscles. (a) Axial T2-weighted sequences. (b) Coronal STIR sequences: the optic nerve was dislocated downward

A natural eyelid crease was chosen [Figure 3a]. A curvilinear incision <3 cm long was made through the skin and orbicularis muscle. Dissection was conducted in a plane between the orbicularis muscle and the orbital septum toward the frontal bone, until the supra-orbital and supra-trochlear nerves were exposed, lateralized, and protected [Figure 3b]. The periosteum was incised over the superior orbital rim [Figure 3c] and elevated to realize a sub-periosteal plane. The trochlea was visualized; the periorbita was entered from above in a retroseptal route, proceeding with blunt dissection through the intraorbital fat until the exposure of the tendon of the underneath superior oblique muscle. Blunt dissection was continued under the tendon toward the posterior pole of the eye, then passing in between the superior and medial rectus muscles, gently retracting them to access the superomedial intraconal space and its content. The lesion was seen as a dark red soft mass [Figure 4a] and released by the surrounding muscles, intermuscular orbital fat and finally by the optic nerve. The tumor was removed *en bloc* [Figure 4b] without noble structures damage. The procedure was performed in 45 minutes.

No visual impairment, no mydriasis, no ophthalmoplegia or any duction weakness was objectified. The intraorbital throbbing pain as well as the accommodation disturbance disappeared after surgery.

The histopathological examination revealed a CH. After 3 months the MRI demonstrated complete removal of the hemangioma [Figure 5a and b]; the clinical assessment showed normal ocular motility and with an almost invisible scar hidden by the patient's own skin excess [Figure 6a and b].

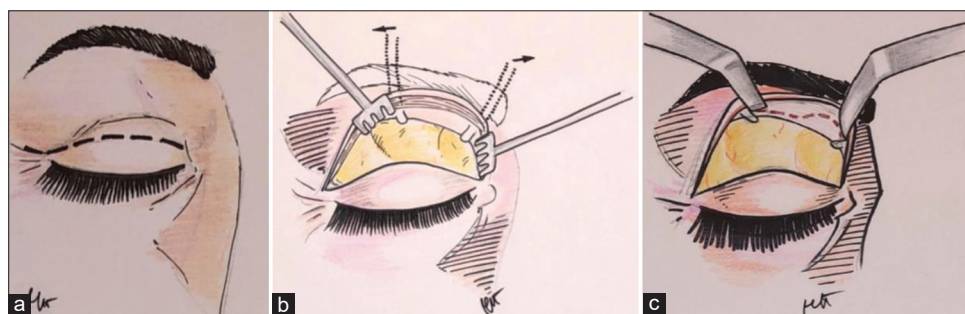


Figure 3: The superior eyelid approach with retroseptal dissection illustrated. (a) A natural eyelid was chosen (a lateral extension is possible). (b) A skin-muscle flap was developed; blunt dissection and lateralization of the supra-orbital and supra-trochlear nerves. (c) The superior orbital rim reached and the periosteum incised

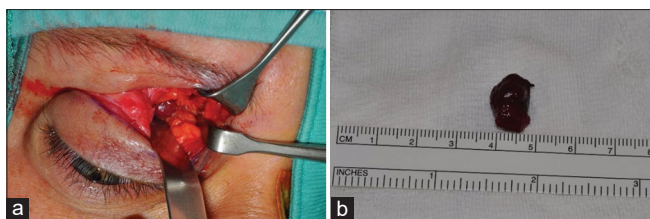


Figure 4: (a) The superior eyelid crease approach with retroseptal dissection: intraoperative view of the intraconal lesion. (b) The specimen after surgical resection: the histopathological examination revealed a cavernous hemangioma

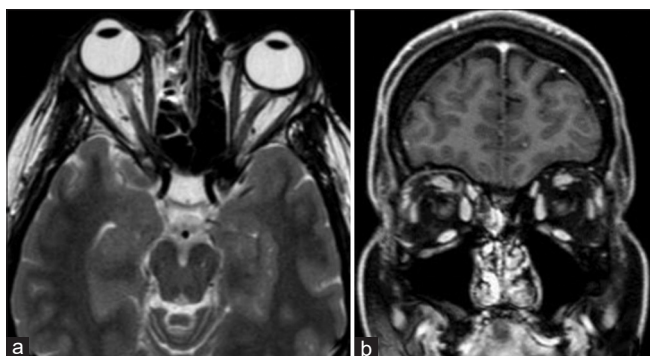


Figure 5: (a and b) Postoperative magnetic resonance imaging and clinical follow-up (c and d) 3 months later. (a) Axial T2-weighted and (b) coronal postcontrast sequences demonstrating complete removal of the intraconal tumor with a normal position of the optic nerve

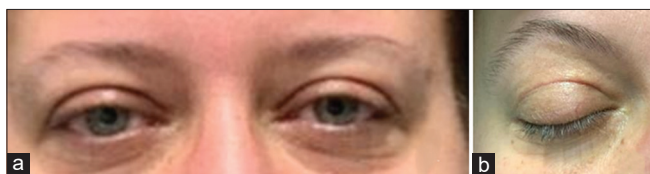


Figure 6: (a) Complete resolution of the initial proptosis. (b) The excellent result of the superior eyelid approach with retroseptal dissection in terms of healing of skin wound: eyelid closed with skin lifted by the operator to show the healed incision inside the patient's own skin excess

DISCUSSION

CHs are congenital low flow vascular malformations. Being slow-growing masses,^[1] their most common clinical sign is painless proptosis, without motility disorders or compression of the optic nerve. If the optic nerve is compressed, progressive alterations of vision are possible until blindness. Due to orbital anatomy and its noble structures, before surgery is taken a judicious medical evaluation is needed; therefore, treatment is recommended in symptomatic cases.^[3,4] Surgical treatment is usually definitive,^[1] although rare cases of local recurrence are described in literature,^[5] perhaps related to incomplete resection. The diagnosis is made by computed tomography or MRI.^[2] Most of CHs occupy the lateral intraconal space with a higher morbidity than extraconal hemangiomas.^[6]

In this article a case of a CH in the superomedial intraconal space is described. Clinically, this CH was causing a

throbbing retrobulbar pain, a mild proptosis, and disturbing accommodation. At the MRI evaluation, the lesion was dislocating downward, and laterally, the optic nerve and compressing the posterior pole of the eye.

Considering the clinical and radiological features, the authors performed an upper eyelid crease access with a retro-septal dissection route (SECARD) which has not been described before, to our knowledge. It has the advantage of not requiring the violation of orbital septum, avoiding its enfeeblement and fat herniation, which could happen through the standard upper eyelid crease access. Compared to a medial approach, the SECARD is more direct to the superomedial intraconal space [Figure 1 and 4a], avoiding any disinsertion and reinsertion of extraocular muscles and every matter related. Compared to an endoscopic endonasal approach, the SECARD is more conservative: it does not need demolition of the medial wall to enter the orbit, neither its reconstruction to avoid postoperative orbital volume changes with a possible enophthalmos. It does not need any middle turbinectomy and any nasal septum resection to gain adequate space for endoscopic manoeuvres. Besides, it does not require any expertise in endoscopic endonasal surgery, which is mandatory to get good outcomes and to keep risks low.^[7,8] A lateral approach^[9] was also excluded firstly because it is best suitable for reaching the lateral intraconal space,^[3,8] secondly because external scars, bony marginotomies, heavy extraocular muscular and bulbar retractions are inevitable. Moreover, it needs dissection through important nerves and vessels which are lateral to the optic nerve,^[10] to reach the medial part of the intraconal space. All these more invasive and time-consuming procedures can result in serious postoperative complications, such as strabismus (due to extraocular muscular transection and misposition), or muscle palsy (due to heavy tractions). Indeed, by a SECARD, it is possible to realize a more direct and rapid route with less muscular traction, bleeding, edema, orbital tissue dissection, morbidity and, therefore, better functional and cosmetic outcomes. Even if SECARD is an external approach which implies a skin scar, it requires only one incision, always well hidden inside a natural crease of the superior eyelid, without any bony osteotomy. It is also not technically demanding because of its similarity to the superior eyelid approach for the reduction and osteosynthesis of the frontozygomatic fractures.

Therefore, with regard to its low morbidity, rapidity, brilliant esthetic, and functional results, the upper blepharoplasty approach with RD route proved to be a safe promising method for removing retrobulbar intraconal superomedial masses.

Declaration of patient consent

The authors certify that they have obtained all appropriate patient consent forms. In the form, the patient has given her consent for her images and other clinical information to be reported in the journal. The patient understands that her name and initials will not be published and due efforts will be made to conceal identity, but anonymity cannot be guaranteed.

Financial support and sponsorship

Nil.

Conflicts of interest

There are no conflicts of interest.

REFERENCES

1. Alfred PR, Char DH. Cavernous hemangiomas of the orbit. *Orbit* 1996;15:59-66.
2. Gönül E, Timurkaynak E. Lateral approach to the orbit: An anatomical study. *Neurosurg Rev* 1998;21:111-6.
3. Markiewicz MR, Bell RB. Traditional and contemporary surgical approaches to the orbit. *Oral Maxillofac Surg Clin North Am* 2012;24:573-607.
4. Shields JA, Shields CL, Scartozzi R. Survey of 1264 patients with orbital tumors and simulating lesions: The 2002 Montgomery Lecture, part 1. *Ophthalmology* 2004;111:997-1008.
5. Limawararut V, Davis G, Crompton J, Leibovitch I, Selva D. Recurrent multiple cavernous hemangiomas of the orbit in association with systemic tumors. *Am J Ophthalmol* 2006;141:943-5.
6. Paolini S, Santoro A, Missori P, Pichierrri A, Esposito V, Ciappetta P. Surgical exposure of lateral orbital lesions using a coronal scalp flap and lateral orbitozygomatic approach: Clinical experience. *Acta Neurochir (Wien)* 2006;148:959-63.
7. Gazioglu N, Abuzayed B, Tanriover N. Neuronavigation-guided endoscopic endonasal excision of an intraorbital intraconal cavernous hemangioma. *J Craniofac Surg* 2011;22:1802-5.
8. Paluzzi A, Gardner PA, Fernandez-Miranda JC, Tormenti MJ, Stefkó ST, Snyderman CH, *et al.* "Round-the-Clock" surgical access to the orbit. *J Neurol Surg B Skull Base* 2015;76:12-24.
9. Arai H, Sato K, Katsuta T, Rhoton AL Jr., Lateral approach to intraorbital lesions: Anatomic and surgical considerations. *Neurosurgery* 1996;39:1157-62.
10. Stallard HB. A plea for lateral orbitotomy: With certain modifications. *Br J Ophthalmol* 1960;44:718-23.