

Research paper

Functional neurodevelopment of working memory in early-onset schizophrenia: A longitudinal fMRI study

Vasileios Ioakeimidis^a, Corinna Haenschel^a, Anne-Kathrin Fett^a, Marinos Kyriakopoulos^{b,c,1}, Danai Dima^{a,d,*}

^a Department of Psychology, School of Arts and Social Sciences, City, University of London, London, United Kingdom

^b National and Specialist Acorn Lodge Inpatient Children Unit, South London & Maudsley NHS Trust, London, United Kingdom

^c Department of Child and Adolescent Psychiatry, Institute of Psychiatry, Psychology and Neuroscience, King's College London, London, United Kingdom

^d Department of Neuroimaging, Institute of Psychiatry, Psychology and Neuroscience, King's College London, London, United Kingdom

ARTICLE INFO

Keywords:

Early-onset schizophrenia
Working memory
Longitudinal
fMRI
Maturation

ABSTRACT

Schizophrenia, a debilitating disorder with typical manifestation of clinical symptoms in early adulthood, is characterized by cognitive impairments in executive processes such as in working memory (WM). However, there is a rare case of individuals with early-onset schizophrenia (EOS) starting before their 18th birthday, while WM and its neural substrates are still undergoing maturation. Using the WM n-back task with functional magnetic resonance imaging, we assessed the functional neurodevelopment of WM in adolescents with EOS and age- and gender-matched typically developing controls. Participants underwent neuroimaging in the same scanner twice, once at age 17 and at 21 (mean interscan interval = 4.3 years). General linear model analysis was performed to explore WM neurodevelopmental changes within and between groups. Psychopathological scores were entered in multiple regressions to detect brain regions whose longitudinal functional change was predicted by baseline symptoms in EOS. WM neurodevelopment was characterized by widespread functional reductions in frontotemporal and cingulate brain areas in patients and controls. No between-group differences were found in the trajectory of WM change. Baseline symptom scores predicted functional neurodevelopmental changes in frontal, cingulate, parietal, occipital, and cerebellar areas. The adolescent brain undergoes developmental processes such as synaptic pruning, which may underlie the refinement WM of network. Prefrontal and parieto-occipital activity reduction is affected by clinical presentation of symptoms. Using longitudinal neuroimaging methods in a rare diagnostic sample of patients with EOS may help the advancement of neurodevelopmental biomarkers intended as pharmacological targets to tackle WM impairment.

1. Introduction

Schizophrenia is a psychiatric disorder with a complex phenotype, characterized by positive, negative, and cognitive symptoms. Early-onset schizophrenia (EOS) patients get diagnosed with the disorder earlier than their 18th birthday and constitute around 5 % of all schizophrenia cases (Cannon et al., 1999). While EOS is considered continuous with its adult-onset counterpart (Kyriakopoulos and Frangou, 2007), two different cut-off points for onset-age, one at 12 and one at 17, may characterize incrementally worse outcome in EOS (Kyriakopoulos and Frangou, 2007), whereas the younger the onset-age is,

the more severe premorbid deficits may be, i.e., educational, social, and cognitive impairments (Jacobsen and Rapoport, 1998). The neurodevelopmental model suggests that schizophrenia is associated with disrupted brain maturation stemming from genetic, perinatal, and environmental factors (Mané et al., 2009). Individuals who develop EOS and schizophrenia experience premorbid neurocognitive deficits by early childhood. These are expressed as a neurodevelopmental delay in the acquisition of cognitive skills (neurodevelopmental model) rather than cognitive decline of skills that have already been acquired (neurodegenerative model) (Bora, 2015). Evidence that further reinforce the neurodevelopmental basis of schizophrenia involve structural

* Corresponding author at: Department of Psychology, School of Arts and Social Sciences, City, University of London, 10 Northampton Square, London EC1V 0HB, United Kingdom.

E-mail address: danai.dima@city.ac.uk (D. Dima).

¹ Joint last authors.

<https://doi.org/10.1016/j.scog.2022.100268>

Received 24 May 2022; Received in revised form 5 August 2022; Accepted 5 August 2022

2215-0013/© 2022 The Authors. Published by Elsevier Inc. This is an open access article under the CC BY-NC-ND license (<http://creativecommons.org/licenses/by-nc-nd/4.0/>).

and functional brain changes in patients with first-episode psychosis (Li et al., 2018), individuals at clinical high risk for developing schizophrenia (Fryer et al., 2013), healthy siblings of schizophrenia patients (Loeb et al., 2018) and adolescent cases with the disorder (Haenschel et al., 2007).

Schizophrenia neurodevelopmental changes precede the overt manifestation of symptoms in early adulthood (Fatemi and Folsom, 2009) and therefore understanding typical brain development is important (Frangou et al., 2021; Dima et al., 2021). Adolescence is an especially critical period for the developmental maturation of executive function such as, cognitive control, working memory (WM) and error monitoring (Luna et al., 2015), and their neural substrates that continue to develop up to the third decade of life (Tamnes et al., 2013). Cortical and subcortical grey matter volume decreases from childhood to adulthood, while white matter increases, following normative maturation processes that include synaptic pruning and myelination, respectively (Marsh et al., 2008). Longitudinal WM functional brain changes are found to fluctuate in typically developing (TD) individuals from 8 to 30 years in sensorimotor and executive brain regions (Simmonds et al., 2017). From 16 to 23 years old, functional WM development involves progressively reduced recruitment in the anterior cingulate cortex (ACC), the insula and inferior parietal lobule, while DLPFC activity is less engaged in adulthood compared to childhood (Simmonds et al., 2017).

Cognitive brain function in EOS is manifested, at large, as hypoactivation in key executive areas that include the ACC and posterior parietal cortices (Ioakeimidis et al., 2020), relative to age-matched typically developing adolescents. WM function is further associated with aberrant brain activity in occipital, temporal, ACC regions (White et al., 2011), in bilateral middle frontal gyri (DLPFC) (Bittner et al., 2015), similar to adult-onset cases (Glahn et al., 2005). It is not clear, however, whether these cross-sectional functional changes are due to clinical illness characteristics or abnormal neurodevelopment. While there is a considerable wealth of evidence concerned with cross-sectional function and long-term longitudinal structural neurodevelopment of EOS (Thompson et al., 2001; Alexander-Bloch et al., 2014), there are no studies, to date, to investigate the longitudinal functional neurodevelopmental course of patients with onset-age strictly below 18 years. In fact, majority of longitudinal functional imaging studies in schizophrenia include samples mixed with post-adolescent patients and are primarily focused on the effects of short pharmacological interventions in longitudinal brain function rather than the neurodevelopmental course of the illness. Such short-term longitudinal studies explore task-dependent BOLD changes relative to pharmacological interventions and symptomatic recovery and predominantly report increases in activation in patients after interventions that last 2–14 weeks (and up to 6 months in the studies listed below); these are found in frontal (dorsolateral, ventrolateral, medial, precentral, postcentral), cingulate (ACC), temporal (inferior, middle, superior), insular, parietal (inferior, precuneus), occipital (fusiform, cuneus, lingual), as well as subcortical areas (striatum, cerebellum) (Honey et al., 1999; Aasen et al., 2005; Reske et al., 2007; Smee et al., 2011; Cadena et al., 2018; Gurler et al., 2020; Meisenzahl et al., 2006; Schlagenhaut et al., 2010). These intervention-related increases have been reported in fMRI studies focusing on WM (Meisenzahl et al., 2006; Schlagenhaut et al., 2010), verbal fluency (Smee et al., 2011), cognitive control (Cadena et al., 2018), sustained attention (Aasen et al., 2005) and memory encoding (Gurler et al., 2020), as well as social cognition (Reske et al., 2007). Even though such studies are extremely helpful to elucidate functional brain changes associated with changes in medication intake and recovery from acute episodes, they do not provide any insight on the functional neurodevelopment of patients with schizophrenia.

Here we studied longitudinal functional brain changes during WM performance in adolescents with EOS and age- and gender-matched typically developing controls into early adulthood. Research in adolescents with EOS is important because it allows to examine disorder-

specific brain changes during a developmentally sensitive period wherein cognitive functions and their neural substrates still mature. It also removes variance introduced by confounding characteristics of the illness such as age-of-illness onset and cumulative exposure to antipsychotic medication. We examined differences in WM functional maturation by employing a longitudinal fMRI design that allowed us to scan EOS and controls twice with a 4.3-year inter-scan interval (mean age at first scan 17 years old and at second 21) using the same scanner and the same n-back paradigm. This aimed to identify longitudinal BOLD activity change from adolescence to early adulthood associated with WM. To our knowledge, this is the first longitudinal task-dependent fMRI investigation of whole-brain changes in functional brain recruitment in a developing sample of patients with schizophrenia onset before their 18th year of age.

2. Methods

2.1. Participants

The baseline sample included 45 EOS and control participants aged 16.2 (± 1.8) years (Kyriakopoulos et al., 2012) at the time of recruitment. Thirty-four participants returned for the follow-up session, with twenty-nine (age 21.08 \pm 1.78) being fully eligible for image analysis (due to missing baseline scans for two controls and three EOS had accuracy below criterion, explained in next section) (Table 1). Patients were recruited from the South London and Maudsley NHS Foundation Trust Child and Adolescent mental health services based on the following criteria: (a) fulfilling Diagnostic and Statistical Manual of Mental Disorders - Fourth Edition (DSM-IV) criteria for schizophrenia; (b) aged 12–19 years; (c) age-of-illness onset (AIO) before the 18th birthday; (d) no co-morbid Axis I diagnosis; and (e) IQ > 70. Psychopathology was assessed in patients with the Positive and Negative Syndrome Scale (PANSS) (Kay et al., 1987). Total cumulative antipsychotic exposure was calculated in chlorpromazine equivalents (CPZE). The demographic, clinical and medication status of patients that were present in both baseline and follow-up scanning sessions are summarized in Table 1. Seventeen EOS and seventeen healthy individuals who were recruited from the same geographic area and had no personal history of psychiatric disorder and no family history of psychosis in their first-degree relatives, returned for the follow-up study. Exclusion criteria for all participants were: (a) history of head injury; (b) lifetime history of substance dependence as defined by the DSM-IV; (c) substance abuse as defined by the DSM-IV within the 6 months preceding study entry; (d) any concomitant medical condition; and (e) history of hereditary neurological disorders. All participants were assessed by one qualified child psychiatrist using the Structured Clinical Interview for DSM-IV Axis I Disorders (First et al., 2002a; First et al., 2002b). In all participants, the National Adult Reading Test (NART) (Nelson, 1982) was used to obtain an estimate of general intellectual ability and the Annett handedness scale (Annett, 1970) to assess hand dominance. Patients filled in the PANSS positive syndrome sub-scale for two consecutive weeks prior to scanning to ensure that they were clinically stable defined as scoring ≤ 3 on each item. For more information see the Supplementary Material, online.

The study was approved by the Joint South London and Maudsley and Institute of Psychiatry Research Ethics Committee. All participants and their parents or guardians, as appropriate, provided written informed consent or assent after detailed description of the study.

2.2. N-back task

The n-back task was administered as a block design, incorporating alternating active and control conditions. At the beginning of each condition, participants were explicitly instructed to respond by button press to the target letter. In the control condition (X-back) the designated target letter was “X”. In the active conditions (one-, two-, and

Table 1

Demographic, clinical, and behavioral characteristics for adolescents with EOS and typically developing adolescent groups at baseline and follow-up with respective *p*-values for longitudinal within-group change.

	Baseline (t1)		Follow-up (t2)		Within-group longitudinal change (<i>p</i> -value)	
	EOS	TD	EOS	TD	EOS	TD
	n = 14	n = 15	n = 14	n = 15		
Demographic data						
Age (years)	17.03 (1.42)	16.51 (2.22)	21.01 (1.60)	21.15 (1.99)		
Range (years)	14.75 - 19.75	13.00 - 20.83	18.08 - 23.92	18.08 - 25.83		
Gender (M/F)	9/5	10/5				
Handedness (L/R)	13/1	13/2				
NART	97.57 (10.65)	100.71 (8.02)	100.33 (7.87)	111.41 (4.35)	0.149	<0.001
Clinical data						
Symptoms						
PANSS positive	9.21 (1.81)	–	10.36 (3.43)	–	0.271	–
PANSS negative	14.00 (1.80)	–	12.21 (4.66)	–	0.229	–
PANSS total	47.21 (4.19)	–	47.64 (10.21)	–	0.879	–
Medication (mg)						
Cumulative CPZE	10,967.86 (16,292.93)	–	27,683.57 (31,708.83)	–	0.001	–
Behavioral data						
Accuracy (% correct); Median (IQR)						
One-back	100 % (19 %)	100 % (0 %)	100 % (25 %)	100 % (13 %)	0.739	0.705
Two-back	81.25 % (44 %)	100 % (13 %)	93.75 % (56 %)	100 % (13 %)	0.506	0.234
Three-back	56.25 % (44 %)	62.5 (50 %)	81.25 % (53 %)	87.5 % (25 %)	0.031	0.051
Reaction time (s); Mean (SD)						
One-back	0.58 (0.12)	0.51 (0.08)	0.58 (0.12)	0.53 (0.08)	0.924	0.716
Two-back	0.62 (0.12)	0.57 (0.11)	0.58 (0.25)	0.56 (0.11)	0.587	0.994
Three-back	0.66 (0.14)	0.65 (0.14)	0.71 (0.29)	0.62 (0.13)	0.413	0.450

Abbreviations: **CPZE**: chlorpromazine equivalents; **EOS**: early-onset schizophrenia; **F**: female; **IQR**: interquartile range; **L**: left; **M**: male; **mg**: milligrams; **NART**: national adult reading test; **PANSS**: positive and negative syndrome scale; **R**: right; **TD**: Typically developing participants.

three-back), the target letter was defined as any letter that was identical to the one presented one, two or three trials back, respectively. In each condition, a series of 14 letters were presented visually, with each letter displayed for 2 s. Responses were monitored via an MRI-compatible button box held in the subject's dominant hand. Performance of the n-back was recorded as the number of correct responses (accuracy) and reaction time. Exclusion criterion was at accuracy score < 50 % at the low-load conditions (X- and one-back) at baseline or follow-up, leading to the exclusion of three EOS patients from analysis. This resulted in a longitudinal sample of 14 EOS patients. All participants received training before scanning to ensure they understood the task instructions. Within group longitudinal differences for n-back accuracy were assessed with the Wilcoxon test due to non-normal distribution of performance accuracy.

2.3. Image acquisition

The same scanner and image acquisition parameters were used at baseline and at follow-up. fMRI and anatomical data were acquired during the same session on a 1.5-T imaging system (Signa; GE Medical Systems, Milwaukee, Wisconsin) using a gradient-echo echo-planar imaging sequence and a 3D T1-weighted Inversion Recovery prepared Spoiled GRASS sequence respectively. The scanners were calibrated monthly using the same proprietary phantom to ensure stability and accuracy of measurements. A total of 270 T2*-weighted gradient echo-planar imaging (EPI) brain volumes depicting blood-oxygenation level-dependent (BOLD) contrasts were acquired at each of 16 axial planes (echo time = 40 ms, repetition time = 2 s, voxel dimensions = 3.75 × 3.75 × 7 mm³, interslice gap = 0.7 mm, matrix size = 64 × 64, flip angle = 70°). Structural images were acquired using a 3D axial T1-weighted Inversion Recovery prepared Spoiled GRASS sequence from 128 slices (echo time = 5.1 ms, repetition time = 2 s, inversion time = 450 ms, voxel dimensions = 0.9375 × 0.9375 × 1.5 mm³, matrix size = 256 × 192, field of view = 240 × 180 mm², flip angle = 20°, number of

excitations = 1).

2.4. Image analysis

2.4.1. Pre-processing

Image processing and analysis were implemented using the Statistical Parametric Mapping (SPM12) software (www.fil.ion.ucl.ac.uk/spm/). Pre-processing involved realignment (slice timing and motion correction) of the functional images, co-registration of the mean functional image to each participant's structural one, normalization into standard stereotactic space to the Montreal Neurological Institute (MNI) template and smoothing with an isotropic Gaussian kernel of 8 mm full-width-at-half-maximum. No subjects were excluded due to excessive inter-scan motion (defined as >4 mm translation, >4° rotation). The groups did not differ in terms of in-scanner head motion.

2.4.2. First-level image analysis

fMRI responses were high-pass filtered (128 s) and modelled using a canonical hemodynamic response function convolved with the vectors of interest, namely the one-, two-, and three-back blocks. First-level models were constructed for each subject whereby scans from both time points were modelled as different sessions with their respective motion parameters as nuisance regressors in the fMRI model specification module on SPM12. Therefore, longitudinal first-level images were constructed to examine baseline (t1) to follow-up (t2) BOLD activity changes (Δ_{BOLD}) for each different load of n-back blocks (one-, two-, three-back), and these images were used as the dependent variable in all subsequent second-level analysis.

2.4.3. Second-level statistical analysis

2.4.3.1. General linear model. Longitudinal first-level images (Δ_{BOLD} ; term used to abbreviate longitudinal BOLD change) for the three n-back loads were entered in a 3 × 2 flexible factorial model with task (one-,

two-, three-back) and group (typically developing adolescents, adolescents with EOS) as within- and between-subject factors, respectively. We were interested in within-, and between-group differences in Δ_{BOLD} , expressed as reduction or increase across the two time points for the three n-back loads separately (one-, two-, three-back) and together (one-, two-, three-back combined; process-general contrast). We examined Δ_{BOLD} with the following main effects and interactions: main effects of task, main effects of group, and the interactions of task \times group. Therefore, we assessed the main effects of task on Δ_{BOLD} in all n-back levels (we named it *process-general* contrast) as well as in each level individually, across diagnosis status. Additionally, we were interested in the main effects of group on Δ_{BOLD} in process-general and in individual loads of the n-back, for within- and between-groups contrasts.

An exploratory GLM was conducted for the EOS group, to account for any effects of antipsychotic medication in cumulative CPZE, age of illness onset, and interscan interval.

Gender and age at follow-up were used as covariates of no interest. Results are reported at FWE $p < 0.05$.

2.4.3.2. Multiple regressions. First-level images of Δ_{BOLD} at one-, two-, and three-back were entered into multiple regression models in SPM12 with baseline PANSS symptoms scores as covariates of interest, to explore whether symptoms could predict Δ_{BOLD} in EOS patients. Multiple regression analyses were further employed to explore whether Δ_{BOLD} would be predicted by age-of-onset or cumulative medication intake in CPZE. Gender was used as a covariate of no-interest in all analyses. Reported results were thresholded at FWE of $p < 0.05$.

Illicit drug use was not accounted for by any of the analyses as it was an exclusion criterion for all participants.

3. Results

Cross-sectional baseline effects are reported in Kyriakopoulos and colleagues (Kyriakopoulos et al., 2012). The results presented in the following sections only concern the longitudinal cohort present in both scanning sessions.

3.1. Participants

The longitudinal sample consisted of twenty-nine individuals (fifteen TD and fourteen EOS adolescents, Table 1). Supplementary Fig. S1 (online) shows the distribution of ages in both time points. The interscan interval between baseline and follow-up was 4.3 (± 0.82) years for all participants.

Mean age of schizophrenia onset was 14.87 years (± 1.28) (age range 11.70–17.14) (Table 1; Fig. S1), while illness duration at baseline was 2.20 years (± 1.44) and 6.14 (± 1.62) years at follow-up. PANSS scores (positive, negative, and total) remained stable through the 4-year course of the longitudinal study ($p > 0.271$). Cumulative antipsychotic exposure (in chlorpromazine equivalents) increased significantly across the 4-year follow-up (Table 1).

NART scores increased, yet not significantly, in patients with EOS but were significantly improved in typically developing adolescents from baseline to follow-up (Table 1). Accuracy in one- and two-back blocks did not change significantly from baseline to follow-up, in neither of the groups. Three-back accuracy was significantly improved in individuals with EOS ($Z = -2.157$, $p = 0.031$), whereas typically developing adolescents showed a trend of accuracy improvement ($Z = -1.949$, $p = 0.051$) (Table 1). Pairwise t -tests for RT were not statistically different from baseline to follow-up in any n-back level ($p > 0.413$).

3.2. Longitudinal BOLD activity change in the entire sample

Main effects of task (one-, two-, three-back) in the entire sample showed that there were only longitudinal reductions ($\Delta_{\text{BOLD}(t1>t2)}$; $t1 >$

$t2$ subscript abbreviates longitudinal reduction); these were in the right superior frontal gyrus (SFG), bilaterally in the middle frontal gyri (MFG), the right fusiform gyrus, bilateral in the superior temporal poles, and from middle to posterior cingulate gyrus, for the process-general contrast (Fig. 1.A; Table S1, online). There was significant $\Delta_{\text{BOLD}(t1>t2)}$ at the highest n-back load (three-back) which was observed in a cluster expanding from the right SFG to the ACC and supplementary motor area (SMA). One- and two-back blocks did not show significant longitudinal main effects of task.

3.3. Longitudinal BOLD activity change within and between groups

Process-general task main effects for TD adolescents showed $\Delta_{\text{BOLD}(t1>t2)}$ in medial areas bilaterally in the precuneus and the ACC expanding posteriorly to the posterior cingulate portion (Fig. 1.B; Table 2). Significant $\Delta_{\text{BOLD}(t1>t2)}$ was also apparent for the three-back in the ACC.

Adolescents with EOS had significant process-general $\Delta_{\text{BOLD}(t1>t2)}$ in more lateral regions in the cortex; these were observed in the right middle occipital and the SFG, and the left middle frontal gyrus (DLPFC) and the precuneus expanding to the superior parieto-occipital gyri (Fig. 1.B; Table 2). Additionally, patients with EOS showed $\Delta_{\text{BOLD}(t1>t2)}$ at the right putamen/insula (BA 13) during the one-back (Table 2).

In addition to the previous analyses, we performed an exploratory GLM in the EOS group only, where we added the clinical covariates of age of illness-onset, cumulative CPZE and the interscan interval. This was done to identify changes in longitudinal brain activity after ruling out variance caused by confounding factors that are secondary to the illness (Karlsgodt et al., 2008), such as antipsychotic medication, age of illness onset or time between scans. Duration of illness was not included as a covariate to this model because it is strongly correlated with age at follow-up ($r = 0.682$, $p = 0.007$) which would violate the collinearity assumption of ANCOVA. Clusters of significant process-general $\Delta_{\text{BOLD}(t1>t2)}$ are reported in Table S2, online. Significant clusters were located at the right middle occipital gyrus and left parieto-occipital regions, similar to the original analysis without the clinical covariates, but the effect in left middle frontal gyrus ($x = -30$, $y = 38$, $z = 38$, $k_e = 34$, $Z = 4.35$) was now at trend level (*peak-FWE* $p = 0.063$). Furthermore, process-general $\Delta_{\text{BOLD}(t1>t2)}$ was seen in the SMA, the right insula and parietooccipital region (Table S2, online). Unlike the model without the clinical covariates, there were no voxels surviving correction for multiple comparisons for the EOS \times one-back interaction. In contrast, $\Delta_{\text{BOLD}(t1>t2)}$ in the SMA and the left superior temporal gyrus were found during three-back (Fig. 1.C; Table S2, online).

No between-group effects that survived FWE correction were found for Δ_{BOLD} . Therefore, longitudinal changes were not significantly different between the two groups.

3.4. Prediction of longitudinal BOLD activity change by clinical characteristics of EOS

PANSS total, PANSS positive, and PANSS negative scores at $t1$ were entered in multiple regression models to examine if baseline symptoms could predict $\Delta_{\text{BOLD}(t1>t2)}$ in EOS at one-, two-, three-back, and process-general contrasts. At one-back, total PANSS symptoms scores predicted increased reduction in $\Delta_{\text{BOLD}(t1>t2)}$ in the left inferior frontal gyrus and right middle frontal gyrus, whereas positive PANSS symptoms predicted increased reduction in $\Delta_{\text{BOLD}(t1>t2)}$ in the right portions of middle frontal, lingual, and angular gyri, as well as in the left inferior frontal gyrus (Fig. 2.A–B, Table 3). For the two-back n-back, higher baseline scores in PANSS positive and total scales predicted lower reduction in $\Delta_{\text{BOLD}(t1>t2)}$ changes around the ACC (Fig. 2.C) and SMA, while more severe negative symptoms predicted lower reduction in $\Delta_{\text{BOLD}(t1>t2)}$ in the cerebellum (Table 3).

Age of illness-onset and antipsychotic medication (in cumulative CPZE) did not account for significant prediction of $\Delta_{\text{BOLD}(t1>t2)}$ changes.

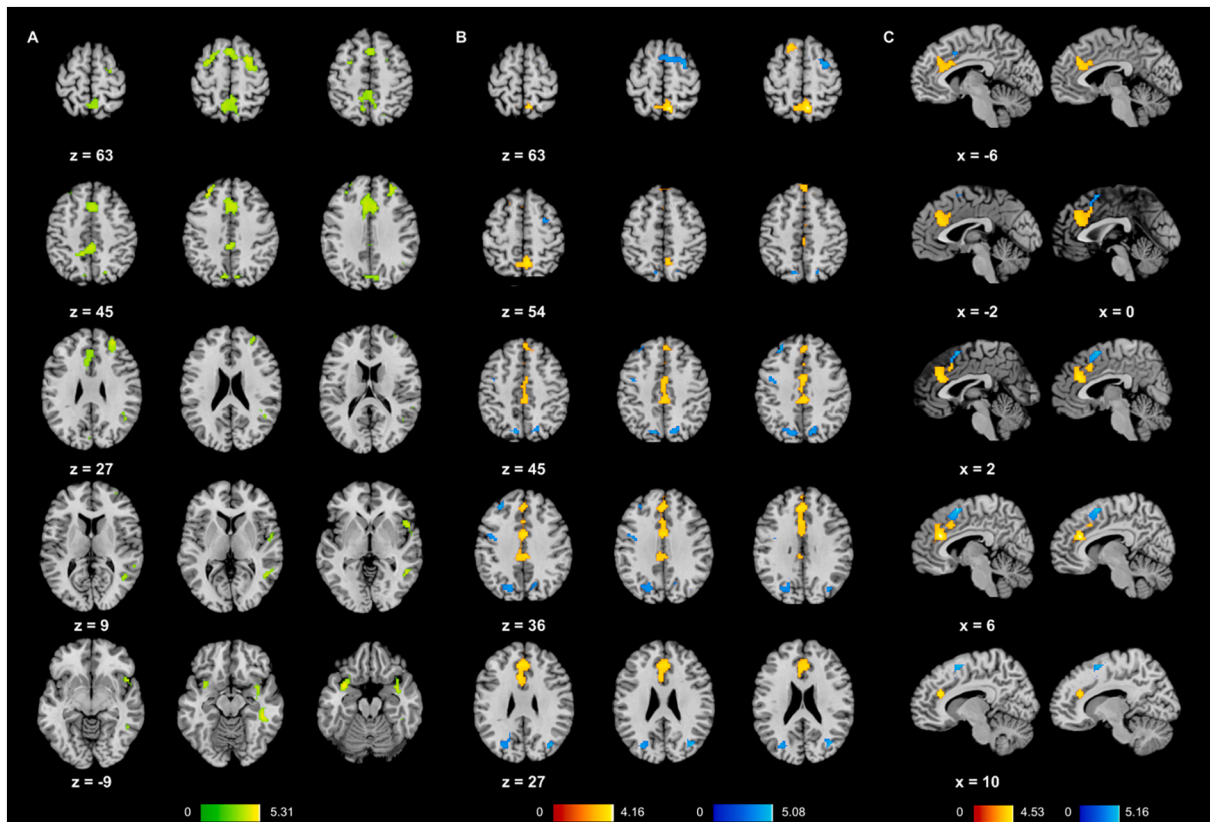


Fig. 1. A) Process-general $\Delta_{BOLD}(t1>t2)$ effects in the entire sample of developing adolescents; B) process-general $\Delta_{BOLD}(t1>t2)$ effects in typically developing adolescents (red) and in adolescents with EOS (blue). C) Sagittal layout of $\Delta_{BOLD}(t1>t2)$ in typical adolescents (red) and adolescents with EOS (blue), shows absence of overlapping reductions in ACC (red) and SMA (blue) areas at three-back trials. The EOS map was extracted from the model with the clinical covariates where three-back effects were found. Color bars represent the T-values of the overlain clusters. Multiple comparisons correction at FWE $p < 0.05$.

Table 2

Main effects of group (\times task) on Δ_{BOLD} while controlling for gender and age at follow-up.

#	k	Regions	BA	L/ R	Peak coordinates			Z-value
					x	y	z	
Typically developing adolescents ($t1 > t2$)								
Process-general								
1	146	Precuneus	7	L/ R	6	-61	56	4.26
2	755	Anterior/middle cingulate gyrus	32	L/ R	3	35	26	4.02
Three-back								
1	345	Anterior cingulate gyrus	24	L/ R	9	29	20	4.26
Adolescents with early onset schizophrenia ($t1 > t2$)								
Process-general								
1	75	Middle occipital gyrus	19	R	39	-76	23	4.73
2	77	Superior frontal gyrus	6	R	30	-1	59	4.35
3	34	Middle frontal gyrus	9	L	-33	35	38	4.30
4	205	Precuneus/superior occipital gyrus	7	L	-12	-76	44	4.09
One-back								
1	68	Putamen/Insula	13	R	30	8	20	4.32

Process-general refers to the model that contains all three n-back loads; FWE correction for multiple comparisons at $p < 0.05$.

4. Discussion

To our knowledge, this is the first longitudinal fMRI study to investigate the functional development of WM in patients with EOS and age-

matched controls from adolescents to early adulthood. We found that (1) functional brain changes associated with WM did not differ between patients with EOS and typically developing participants in a 4-year period, while (2) WM development is associated with widespread functional reductions in frontotemporal and cingulate regions in the entire sample. Finally, (3) severity of schizophrenia symptoms at baseline predicted functional longitudinal changes in frontal, cingulate, and parietooccipital areas.

EOS patients displayed stable WM performance and did not show any deterioration in their positive and negative symptoms at the time of testing, which is in line with the neurodevelopmental model (Zipursky et al., 2013). Accuracy was developed at adult levels for the one-back and two-back in both groups, since there were no differences from baseline-to-follow-up. However, the ability to perform the three-back accurately continued to increase into early adulthood in both groups of developing adolescents. In the 4-year period spanning from adolescence to early adulthood, WM-related brain activation did not differ between EOS patients and typically developing participants. Similar neuroimaging findings were reported in a longitudinal study exploring cognitive control in young patients (12–28 years) with recent-onset schizophrenia which identified stable activation in DLPFC over a 1.5-year period in both schizophrenia and healthy controls (Niendam et al., 2018).

Even though longitudinal functional change between the groups was statistically comparable, the functional reductions in typically developing controls and those in EOS patients do not overlap. EOS adolescents had reduced recruitment of brain areas located more laterally, in posterior parietooccipital, prefrontal, as well putamen and, insular areas. These reductions were seen despite the patients' longitudinal cognitive performance and symptom status that remained stable across the 4-year

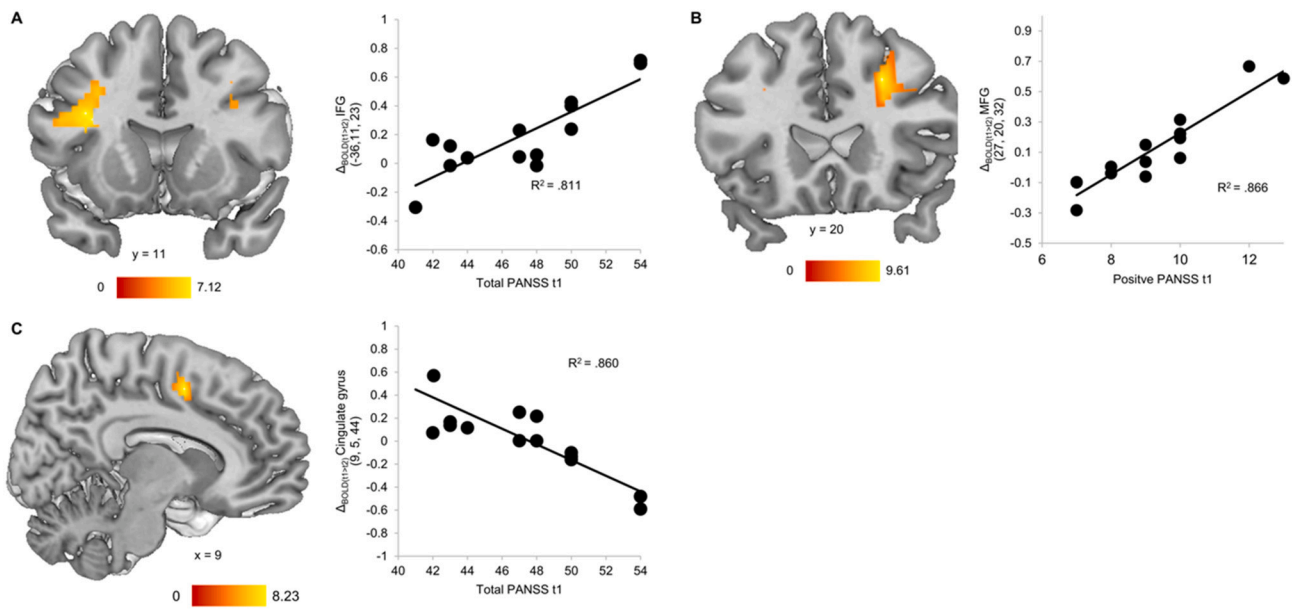


Fig. 2. Higher PANSS symptoms at baseline predicted: A), B) increased $\Delta_{BOLD(t1>t2)}$ in the left inferior frontal and the right middle frontal gyri during one-back, and C) lower $\Delta_{BOLD(t1>t2)}$ in the middle cingulate gyrus during two-back. Color bars represent the T-values of the overlay clusters. Multiple comparisons correction at FWE $p < 0.05$.

Table 3

Brain areas with $\Delta_{BOLD(t1>t2)}$ predicted by baseline PANSS (total, positive, negative) scores in individuals with EOS.

#	k	Regions	BA	L/ R	Peak coordinates			Z-value
					x	y	z	
One-back								
Total symptoms: positive regression								
1	174	Inferior frontal gyrus, opercular	13	L	-36	11	23	4.26
2	88	Middle frontal gyrus	9	R	30	23	35	4.14
Positive symptoms: positive regression								
1	219	Middle frontal gyrus	9	R	27	20	32	4.87
2	131	Lingual gyrus	19	R	27	-61	-1	4.70
3	78	Angular gyrus	39	R	33	-61	35	4.38
4	92	Inferior frontal gyrus, opercular	9	L	-45	11	23	4.12
Two-back								
Total symptoms: negative regression								
1	177	Anterior Cingulate gyrus	32	L/ R	9	5	44	4.56
Positive symptoms: negative regression								
1	136	Supplementary motor area	23	L/ R	-6	-1	50	4.45
Negative symptoms: negative regression								
1	79	Cerebellum, Vermis, 3		L	0	-34	-13	5.22

FWE correction for multiple comparisons at $p < 0.05$.

follow-up period. Hence, WM functional neurodevelopment in EOS is manifested by reduced recruitment in executive brain regions that do not overlap with the developmental reductions in TD. Longitudinally, activity reductions in brain areas of the posterior parietal and occipital cortex together with prefrontal areas may be specific to schizophrenia dysfunction as the disease-duration progresses (Hahn et al., 2018). Such dysfunction may result from altered brain maturation mechanisms in EOS, such as synaptic pruning. The hypothesis that progressive grey matter change could reflect dendritic retraction and synaptic pruning is supported by evidence on positron emission tomography (PET) scans of greater activated microglia in patients with schizophrenia as well as neuroinflammatory markers elevated in post-mortem neural tissue from

patients with schizophrenia, markers associated with microglial-mediated synaptic pruning and dendritic retraction (Cannon, 2015). It is also possible that EOS is characterized by additional factors like social adversity and stress during this later maturational period that affect the refinement of the executive circuitry and the elimination of extraneous synapses that normally occur in typical development (Karlsgodt et al., 2008) to the degree of observable reduction in function over time. This could then translate into progressively different functional reorganization of WM in EOS adolescents and TD ones during transition into adulthood. The socio-developmental model of Howes & Murray (Howes and Murray, 2014) integrates that socioeconomic adversity alongside genetic vulnerability may initiate and maintain a vicious cycle of stress leading to neurodevelopmental abnormalities and dopamine dysregulation that are strongly linked to psychosis (Howes and Murray, 2014).

Irrespective of group membership and n-back load, WM maturation was associated with reduced recruitment in bilateral prefrontal cortex (right superior and left middle frontal), bilateral superior temporal poles, right fusiform gyrus, and posterior cingulate gyrus. Reductions were also seen in ACC, SFG, and SMA area at three-back; as adolescents matured to adulthood, they relied less in those regions to complete the n-back task. Similarly, Simmonds and colleagues (Simmonds et al., 2017) found reductions in executive regions during typical development of WM function from childhood to adulthood. Hence, decreasing WM brain function in development consists of a normal process that is seen in both EOS and typically developing adolescents in executive brain areas and it parallels normative structural developmental trajectories (Gogtay et al., 2004). Our results indicate that typical WM maturation in the transition to adulthood is associated with decreased activation in regions in the medial wall that spanned from the anterior to the posterior cingulate and to the precuneus. Activation of the ACC/midcingulate cortex is relevant to conflict and error monitoring, redirection of attention and action whereas the posterior cingulate and precuneus are more related to self-referential activity (Rolls, 2019). Decreased activation in these areas could be related to performing the n-back by doing less errors, while also relying less on internalized thinking processes in early adulthood. It could also highlight the refinement of error monitoring to guide action towards more successful trials, which is suggested by the trend improvement in the three-back performance which is paralleled by the significant reduction on the activation in ACC and SMA during these

high-load and error-prone blocks. Functional activity reduction in the ACC was not only significant in the whole n-back process-general and the three-back contrasts, but it was also predicted by improving accuracy at the two-back. Taken together these results indicate a central role of the ACC in WM development during late adolescence.

Positive, negative, and total schizophrenia psychopathology at baseline was associated with functional longitudinal changes in a widespread brain network including midline cingulate, frontal, parietal, and occipital areas, as well as the cerebellum. Importantly, more severe initial total and positive PANSS scores predicted greater degree of hypoactivation in middle and inferior frontal areas located in the DLPFC in adulthood in EOS patients. Reduced DLPFC activation in adolescent EOS patients has been consistently reported (Bittner et al., 2015; Kyriakopoulos et al., 2012). In our study, EOS patients with more severe adolescent psychopathology at age 17 had less DLPFC engagement in early adulthood at age 21. This hypoactivity is consistent with findings from previous adult schizophrenia studies in WM (Wu and Jiang, 2019). On the other hand, more severe initial positive and total symptoms predicted linearly reduced functional change in the ACC. This means that EOS patients that scored higher at PANSS total scales had less functional reductions in the ACC. These results are consistent with previous meta-analyses on schizophrenia and WM memory (Wu and Jiang, 2019). The hypo-activation of the DLPFC and the hyper-activation of the dorsal ACC appear to be intrinsically linked; the DLPFC provides top-down cognitive control (Miller and Cohen, 2001) and the ACC is responsible for conflict monitoring (Kerns et al., 2004). Within this framework, the hyper-activation of the ACC could occur if the hypo-activation of the DLPFC leads to impaired cognitive control and demands increased conflict monitoring and adjustments in control from the ACC (Carter et al., 2001). Crucially, clinical characteristics in EOS also associate with structural abnormalities in the ACC: ACC volume and neuronal density decrease with younger age of onset (Brüne et al., 2010), while aberrant white matter integrity is associated with psychotic symptoms (Tang et al., 2010). Our results enrich the evidence implicating DLPFC and ACC pathology in the pathogenesis of schizophrenia and the relationship of observed activation in these areas with clinical severity.

Several methodological issues require further consideration. First, our study's small sample size. EOS is a rare disorder, which makes enrolment and retention of participants more difficult, thus almost all recent longitudinal studies that include neuroimaging and EOS patients have similar sample sizes. However, we improved our power by acquiring a homogeneous diagnostic sample that is matched to the TD group. Second, possible medication effects on the study results cannot be conclusively refuted. However, we found no significant relationship between medication and measures of regional activation. Finally, potential signal drifts of MRI scanners are a common problem in longitudinal studies. Nevertheless, the same MRI scanner was used for baseline and follow-up investigations and was frequently tested for signal stability.

In conclusion, we showed that EOS patients demonstrate developmental trajectories of functional WM reductions in posterior parietooccipital, prefrontal, as well putamen and, insular areas. These could serve as endophenotypic markers for disrupted WM maturation as they were independent of medication or illness duration. On the other hand, WM functional developmental changes in ACC and DLPFC were correlated with initial positive and negative symptoms scores. It may be that genetic susceptibility for schizophrenia increases the vulnerability of fronto-parietal and cingulate areas that deteriorate as the symptoms of the disease progress. The clinical implications of studying the longitudinal correlates of WM functional maturation in EOS are crucial in promoting the advancement of pharmacological targets that could one day alleviate the cognitive impairment in schizophrenia which currently has no known effective medication.

CRedit authorship contribution statement

Vasileios Ioakeimidis: Formal analysis; Methodology; Validation; Visualization; Roles/Writing - original draft; Writing - review & editing.

Corinna Haenschel: Methodology; Supervision; Validation; Roles/Writing - original draft; Writing - review & editing.

Anne-Kathrin Fett: Methodology; Supervision; Validation; Visualization; Roles/Writing - original draft; Writing - review & editing.

Marinos Kyriakopoulos: Conceptualization; Data curation; Formal analysis; Funding acquisition; Project administration; Supervision; Roles/Writing - original draft; Writing - review & editing.

Danai Dima: Conceptualization; Funding acquisition; Investigation; Methodology; Supervision; Validation; Roles/Writing - original draft; Writing - review & editing.

Funding sources

This work was supported by a Pump Priming Grant awarded to Danai Dima by City, University of London. Vasileios Ioakeimidis is funded by a City, University of London, PhD studentship.

Declaration of competing interest

None.

Appendix A. Supplementary data

Supplementary data to this article can be found online at <https://doi.org/10.1016/j.scog.2022.100268>.

References

- Aasen, I., Kumari, V., Sharma, T., 2005. Effects of rivastigmine on sustained attention in schizophrenia: an fMRI study. *J. Clin. Psychopharmacol.* 25 (4), 311–317. <https://doi.org/10.1097/01.jcp.0000169267.36797.76>.
- Alexander-Bloch, A.F., Reiss, P.T., Rapoport, J., et al., 2014. Abnormal cortical growth in schizophrenia targets normative modules of synchronized development. *Biol. Psychiatry* 76 (6), 438–446. <https://doi.org/10.1016/j.biopsych.2014.02.010>.
- Annett, M., 1970. A classification of hand preference by association analysis. *Br. J. Psychol.* 61 (3), 303–321. <https://doi.org/10.1111/j.2044-8295.1970.tb01248.x>.
- Bittner, R.A., Linden, D.E.J., Roebroek, A., et al., 2015. The when and where of working memory dysfunction in early-onset Schizophrenia—A functional magnetic resonance imaging study. *Cereb. Cortex* 25 (9), 2494–2506. <https://doi.org/10.1093/cercor/bhu050>.
- Bora, E., 2015. Neurodevelopmental origin of cognitive impairment in schizophrenia. *Psychol. Med.* 45 (1), 1–9. <https://doi.org/10.1017/S0033291714001263>.
- Brüne, M., Schöbel, A., Karau, R., et al., 2010. Von economo neuron density in the anterior cingulate cortex is reduced in early onset schizophrenia. *Acta Neuropathol.* 119 (6), 771–778. <https://doi.org/10.1007/s00401-010-0673-2>.
- Cadena, E.J., White, D.M., Kraguljac, N.V., Reid, M.A., Lahti, A.C., 2018. Evaluation of fronto-striatal networks during cognitive control in unmedicated patients with schizophrenia and the effect of antipsychotic medication. *NPJ Schizophr.* 4 (1) <https://doi.org/10.1038/s41537-018-0051-y>.
- Cannon, T.D., 2015. How schizophrenia develops: cognitive and brain mechanisms underlying onset of psychosis. *Trends Cogn. Sci.* 19 (12), 744–756. <https://doi.org/10.1016/j.tics.2015.09.009>.
- Cannon, M., Jones, P., Huttunen, M.O., et al., 1999. School performance in Finnish children and later development of schizophrenia: a population-based longitudinal study. *Arch. Gen. Psychiatry* 56 (5), 457–463. <https://doi.org/10.1001/archpsyc.56.5.457>.
- Carter, C.S., MacDonald, A.W., Ross, L.L., Stenger, V.A., 2001. Anterior cingulate cortex activity and impaired self-monitoring of performance in patients with schizophrenia: an event-related fMRI study. *Am. J. Psychiatry* 158 (9), 1423–1428. <https://doi.org/10.1176/appi.ajp.158.9.1423>.
- Dima, D., Modabbernia, A., Papachristou, E., et al., 2021. Subcortical volumes across the lifespan: data from 18,605 healthy individuals aged 3–90 years. *Hum. Brain Mapp.* (December 2020), hbm.25320 <https://doi.org/10.1002/hbm.25320>.
- Fatemi, S.H., Folsom, T.D., 2009. The neurodevelopmental hypothesis of schizophrenia, revisited. *Schizophr. Bull.* 35 (3), 528–548. <https://doi.org/10.1093/schbul/sbn187>.
- First, M.B., Spitzer, R.L., Gibbon, M.L., Williams, J.B.W., 2002. Structured Clinical Interview for DSM-IV-TR Axis I Disorders, Research Version, Non-patient Edition. In: (SCID-I/P). Biometrics Research, New York State Psychiatric Institute, New York.
- First, M.B., Spitzer, R.L., Gibbon, M.L., Williams, J.B.W., 2002. Structured Clinical Interview for DSM-IV-TR Axis I Disorders, Patient Edition. In: (SCID-I/P). Biometrics Research, New York State Psychiatric Institute, New York.

- Frangou, S., Modabbernia, A., Williams, S.C.R., 2021. Cortical thickness across the lifespan: data from 17,075 healthy individuals aged 3–90 years. *Hum. Brain Mapp.* 1–21. <https://doi.org/10.1002/hbm.25364>. Published online February.
- Fryer, S.L., Woods, S.W., Kiehl, K.A., et al., 2013. Deficient suppression of default mode regions during working memory in individuals with early psychosis and at clinical high-risk for psychosis. *Front. Psych.* 4 (SEP), 1–17. <https://doi.org/10.3389/fpsy.2013.00092>.
- Glahn, D.C., Ragland, J.D., Abramoff, A., et al., 2005. Beyond hypofrontality: a quantitative meta-analysis of functional neuroimaging studies of working memory in schizophrenia. *Hum. Brain Mapp.* 25 (1), 60–69. <https://doi.org/10.1002/hbm.20138>.
- Gogtay, N., Giedd, J.N., Lusk, L., et al., 2004. Dynamic mapping of human cortical development during childhood through early adulthood. *Proc. Natl. Acad. Sci. U. S. A.* 101 (21), 8174–8179. <https://doi.org/10.1073/pnas.0402680101>.
- Gurler, D., White, D.M., Kraguljac, N.V., 2020. Neural signatures of memory encoding in schizophrenia are modulated by antipsychotic treatment. *Neuropsychobiology* 1–13. <https://doi.org/10.1159/000506402>. Published online.
- Haenschel, C., Bittner, R.A., Haertling, F., et al., 2007. Contribution of impaired early-stage visual processing to working memory dysfunction in adolescents with schizophrenia. *Arch. Gen. Psychiatry* 64 (11), 1229. <https://doi.org/10.1001/archpsyc.64.11.1229>.
- Hahn, B., Robinson, B.M., Leonard, C.J., Luck, S.J., Gold, J.M., 2018. Posterior parietal cortex dysfunction is central to working memory storage and broad cognitive deficits in schizophrenia. *J. Neurosci.* 38 (39), 8378–8387. <https://doi.org/10.1523/JNEUROSCI.0913-18.2018>.
- Honey, G.D., Bullmore, E.T., Soni, W., Varatheesan, M., Williams, S.C.R., Sharma, T., 1999. Differences in frontal cortical activation by a working memory task after substitution of risperidone for typical antipsychotic drugs in patients with schizophrenia. *Proc. Natl. Acad. Sci. U. S. A.* 96 (23), 13432–13437. <https://doi.org/10.1073/pnas.96.23.13432>.
- Howes, O.D., Murray, R.M., 2014. Schizophrenia: an integrated sociodevelopmental-cognitive model. *Lancet* 383 (9929), 1677–1687. [https://doi.org/10.1016/S0140-6736\(13\)62036-X](https://doi.org/10.1016/S0140-6736(13)62036-X).
- Ioakeimidis, V., Haenschel, C., Yarrow, K., Kyriakopoulos, M., Dima, D., 2020. A meta-analysis of structural and functional brain abnormalities in early-onset schizophrenia. *Schizophr. Bull. Open* 1 (1), 1–12. <https://doi.org/10.1093/schizbullopen/sgaa016>.
- Jacobsen, L.K., Rapoport, J.L., 1998. Research update: childhood-onset schizophrenia: implications of clinical and neurobiological research. *J. Child Psychol. Psychiatry* 39 (1), 101–113. <https://doi.org/10.1111/1469-7610.00305>.
- Karlsgodt, K.H., Sun, D., Jimenez, A.M., et al., 2008. Developmental disruptions in neural connectivity in the pathophysiology of schizophrenia. *Dev. Psychopathol.* 20 (4), 1297–1327. <https://doi.org/10.1017/S095457940800062X>.
- Kay, S.R., Fiszbein, A., Opler, L.A., 1987. The positive and negative syndrome scale (PANSS) for schizophrenia. *Schizophr. Bull.* 13 (2), 261–276. <https://doi.org/10.1093/schbul/13.2.261>.
- Kerns, J.G., Cohen, J.D., Iii, A.W.M., Cho, R.Y., Stenger, A., Carter, C.S., 2004. Anterior cingulate conflict monitoring and adjustments in control. *Science* (80-) 303 (5660), 1023–1026.
- Kyriakopoulos, M., Frangou, S., 2007. Pathophysiology of early onset schizophrenia. *Int. Rev. Psychiatry* 19 (4), 315–324. <https://doi.org/10.1080/09540260701486258>.
- Kyriakopoulos, M., Dima, D., Roiser, J.P., Corrigan, R., Barker, G.J., Frangou, S., 2012. Abnormal functional activation and connectivity in the working memory network in early-onset schizophrenia. *J. Am. Acad. Child Adolesc. Psychiatry* 51 (9), 911–920. <https://doi.org/10.1016/j.jaac.2012.06.020>.
- Li, M., Deng, W., Das, T., et al., 2018. Neural substrate of unrelenting negative symptoms in schizophrenia: a longitudinal resting-state fMRI study. *Eur. Arch. Psychiatry Clin. Neurosci.* 268 (7), 641–651. <https://doi.org/10.1007/s00406-017-0851-5>.
- Loeb, F.F., Zhou, X., Craddock, K.E.S., et al., 2018. Reduced functional brain activation and connectivity during a working memory task in childhood-onset schizophrenia. *J. Am. Acad. Child Adolesc. Psychiatry* 57 (3), 166–174. <https://doi.org/10.1016/j.jaac.2017.12.009>.
- Luna, B., Marek, S., Larsen, B., Tervo-Clemmens, B., Chahal, R., 2015. An integrative model of the maturation of cognitive control. *Annu. Rev. Neurosci.* 38 (1), 151–170. <https://doi.org/10.1146/annurev-neuro-071714-034054>.
- Mané, A., Falcon, C., Mateos, J.J., et al., 2009. Progressive gray matter changes in first episode schizophrenia: a 4-year longitudinal magnetic resonance study using VBM. *Schizophr. Res.* 114 (1–3), 136–143. <https://doi.org/10.1016/j.schres.2009.07.014>.
- Marsh, R., Gerber, A.J., Peterson, B.S., 2008. Neuroimaging studies of Normal brain development and their relevance for understanding childhood neuropsychiatric disorders. *J. Am. Acad. Child Adolesc. Psychiatry* 47 (11), 1233–1251. <https://doi.org/10.1097/CHI.0b013e318185e703>.
- Meisenzahl, E.M., Scheuerecker, J., Zipse, M., et al., 2006. Effects of treatment with the atypical neuroleptic quetiapine on working memory function: a functional MRI follow-up investigation. *Eur. Arch. Psychiatry Clin. Neurosci.* 256 (8), 522–531. <https://doi.org/10.1007/s00406-006-0687-x>.
- Miller, E., Cohen, J., 2001. An integrative theory of prefrontal cortex function. Published online *Annu. Rev. Neurosci.* 167–202. <http://www.annualreviews.org/doi/abs/10.1146/annurev.neuro.24.1.167>. (Accessed 20 November 2014).
- Nelson, H.E., 1982. *The National Adult Reading Test (NART): test manual*. Wind UK NFER-Nelson 124 (3).
- Niendam, T.A., Ray, K.L., Iosif, A.M., et al., 2018. Association of age at onset and longitudinal course of prefrontal function in youth with schizophrenia. *JAMA Psychiatry* 75 (12), 1217–1224. <https://doi.org/10.1001/jamapsychiatry.2018.2538>.
- Reske, M., Kellermann, T., Habel, U., et al., 2007. Stability of emotional dysfunctions? A long-term fMRI study in first-episode schizophrenia. *J. Psychiatr. Res.* 41 (11), 918–927. <https://doi.org/10.1016/j.jpsychires.2007.02.009>.
- Rolls, E.T., 2019. The cingulate cortex and limbic systems for emotion, action, and memory. *Brain Struct. Funct.* 224 (9), 3001–3018. <https://doi.org/10.1007/s00429-019-01945-2>.
- Schlagenhauf, F., Dinges, M., Beck, A., et al., 2010. Switching schizophrenia patients from typical neuroleptics to aripiprazole: effects on working memory dependent functional activation. *Schizophr. Res.* 118 (1–3), 189–200. <https://doi.org/10.1016/j.schres.2010.01.022>.
- Simmonds, D.J., Hallquist, M.N., Luna, B., 2017. Protracted development of executive and mnemonic brain systems underlying working memory in adolescence: a longitudinal fMRI study. *NeuroImage* 157 (January), 695–704. <https://doi.org/10.1016/j.neuroimage.2017.01.016>.
- Smee, C., Krabbendam, L., O'Daly, O., et al., 2011. An fMRI study of prefrontal dysfunction and symptomatic recovery in schizophrenia. *Acta Psychiatr. Scand.* 123 (6), 440–450. <https://doi.org/10.1111/j.1600-0447.2010.01632.x>.
- Tames, C.K., Walhovd, K.B., Grydeland, H., et al., 2013. Longitudinal working memory development is related to structural maturation of frontal and parietal cortices. *J. Cogn. Neurosci.* 25 (10), 1611–1623. https://doi.org/10.1162/jocn_a_00434.
- Tang, J., Liao, Y., Zhou, B., et al., 2010. Abnormal anterior cingulum integrity in first episode, early-onset schizophrenia: a diffusion tensor imaging study. *Brain Res.* 1343, 199–205. <https://doi.org/10.1016/j.brainres.2010.04.083>.
- Thompson, P.M., Vidal, C., Giedd, J.N., et al., 2001. Mapping adolescent brain change reveals dynamic wave of accelerated gray matter loss in very early-onset schizophrenia. *Proc. Natl. Acad. Sci.* 98 (20), 11650–11655. <https://doi.org/10.1073/pnas.201243998>.
- White, T., Hongwanishkul, D., Schmidt, M., 2011. Increased anterior cingulate and temporal lobe activity during visuospatial working memory in children and adolescents with schizophrenia. *Schizophr. Res.* 125 (2–3), 118–128. <https://doi.org/10.1016/j.schres.2010.11.014>.
- Wu, D., Jiang, T., 2019. Schizophrenia-related abnormalities in the triple network: a meta-analysis of working memory studies. *Brain Imaging Behav.* 14 (4), 971–980. <https://doi.org/10.1007/s11682-019-00071-1>.
- Zipursky, R.B., Reilly, T.J., Murray, R.M., 2013. The myth of schizophrenia as a progressive brain disease. *Schizophr. Bull.* 39 (6), 1363–1372. <https://doi.org/10.1093/schbul/sbs135>.