

## Usefulness of laparoscopic subtotal cholecystectomy with operative cholangiography for severe cholecystitis

Jun Kuwabara · Yuji Watanabe · Kazuhiro Kameoka · Atsushi Horiuchi · Kouichi Sato · Shungo Yukumi · Motohira Yoshida · Yuji Yamamoto · Hiroki Sugishita

Received: 14 March 2012 / Accepted: 16 January 2013 / Published online: 5 June 2013  
© The Author(s) 2013. This article is published with open access at Springerlink.com

### Abstract

**Purpose** Cholecystectomy can become hazardous when inflammation develops, leading to anatomical changes in Calot's triangle. We attempted to study the safety and efficacy of laparoscopic subtotal cholecystectomy (LSC) to decrease the incidence of complications and the rate of conversion to open surgery.

**Methods** Patients who underwent LSC between January 2005 and December 2008 were evaluated retrospectively. The operations were performed laparoscopically irrespective of the grade of inflammation estimated preoperatively. However, patients with severe inflammation of the gallbladder underwent LSC involving resection of the anterior wall of the gallbladder, removal of all stones and placement of an infrahepatic drainage tube. To prevent intraoperative complications, including bile duct injury, intraoperative cholangiography was performed.

**Results** LSC was performed in 26 elective procedures among 26 patients (eight females, 18 males). The median patient age was 69 years (range 43–82 years). The median operative time was 125 min (range 60–215 min) and the median postoperative inpatient stay was 6 days (range 3–21 days). Cholangiography was performed during surgery in 24 patients. One patient underwent postoperative endoscopic sphincterotomy for a retained common bile duct stone that was found on cholangiography during surgery. Neither complications nor conversion to open surgery were encountered in this study.

**Conclusions** LSC with the aid of intraoperative cholangiography is a safe and effective treatment for severe cholecystitis.

**Keywords** Operative cholangiography · Laparoscopic cholecystectomy · Subtotal cholecystectomy

### Introduction

Laparoscopic cholecystectomy has replaced open cholecystectomy as the surgical procedure of choice for treating symptomatic gallstones. Whichever approach is used, performing standard cholecystectomy requires safe dissection of the structures in Calot's triangle. This becomes difficult in the presence of acute or chronic inflammation, dense omental adhesions or gangrene of the gallbladder, resulting in higher rates of bile duct injury [1]. The traditional response to encountering a difficult laparoscopic cholecystectomy procedure is to perform conversion to an open procedure; however, this may result in increased postoperative pain, delayed mobility, prolonged hospitalization, adhesion formation and incisional hernia formation. In addition, conversion does not necessarily improve exposure or facilitate cystic duct identification [2]. Laparoscopic subtotal cholecystectomy (LSC) has been reported to be a safe and feasible alternative to conversion to open surgery during difficult laparoscopic cholecystectomy [1, 3–6]. These reports describe the use of excision of the anterior wall of the gallbladder, largely as a means of preventing undue bleeding from the gallbladder fossa. The present study assessed the feasibility of performing LSC with operative cholangiography, thus avoiding the need for potentially hazardous dissection in the area of Calot's triangle and confirming the existence of a common bile duct

J. Kuwabara (✉) · Y. Watanabe · K. Kameoka · A. Horiuchi · K. Sato · S. Yukumi · M. Yoshida · Y. Yamamoto · H. Sugishita  
Second Department of Surgery, Ehime University School of Medicine, Shitsukawa, Toon, Ehime 791-0295, Japan  
e-mail: kuwa-la-pa-jun@hotmail.co.jp;  
kuwabara@m.ehime-u.ac.jp

stone. We herein assessed the safety and effectiveness of this approach.

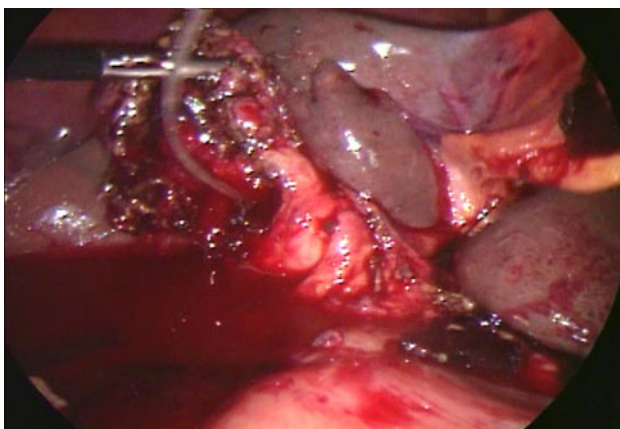
## Materials and methods

### Patients

All patients who underwent laparoscopic cholecystectomy at our hospital between January 1, 2005 and December 31, 2008 were included in this study. All patients underwent laparoscopic cholecystectomy after recovering from severe inflammation of the gallbladder [7]. The case notes for patients who underwent LSC were retrieved and analyzed for demographic data, operative findings, the duration of the procedure, the duration of hospitalization, complications and long-term outcomes.

### Operative procedure

First, we divided the gallbladder neck and Calot's triangle. After skeletonizing the cystic duct and artery, operative cholangiography was attempted in all patients. The cystic duct and artery were closed using clips or ligation. When significant difficulties were encountered in dissecting the gallbladder neck and Calot's triangle and further dissection would expose the patient to a higher risk of common bile duct injury or hemorrhage, the cystic duct was not isolated. Total cholecystectomy was performed even if the inflammation was severe. The operative method was changed to subtotal cholecystectomy when the operation was judged to be excessively high risk. We often performed cholangiography by puncturing the gallbladder or cannulating the cystic duct from inside the gallbladder after incising the gallbladder neck wall (Fig. 1). We then gradually excised



**Fig. 1** Laparoscopic subtotal cholecystectomy. The cystic duct is cannulated from inside the gallbladder after incising the gallbladder neck wall

the anterior wall of the gallbladder and sutured the wall of the gallbladder neck using forceps for laparoscopic surgery (knocked suturing). The inferior wall was cauterized with the electric scalpel to prevent relapse of cholecystolithiasis. A subhepatic drain was often placed.

## Results

LSC was performed in 26 patients (eight females, 18 males). During the 48-month study period, 246 laparoscopic cholecystectomies were performed at our institution. The incidence of LSC was therefore 10.6 %. The median age at the time of surgery was 69 years (range 43–82 years). The median duration from the onset of symptoms to surgery was 81 days (range 12–231 days). All patients, who were unable to undergo early surgery, were receiving antibiotics and exhibited an acute condition. Percutaneous transhepatic gallbladder drainage (PTGBD) was performed preoperatively in four patients (Table 1). The median operative time was 125 min (range 60–215 min). The median duration of postoperative hospitalization was 6 days (range 3–21 days). Subhepatic drains were placed in 15 patients and remained in situ for a median of 2 days (range 1–3 days). Operative cholangiography was performed in 24 patients. Two patients were unable to undergo this evaluation due to cystic duct obstruction.

One patient underwent postoperative EST for a retained common bile duct stone diagnosed on operative cholangiography. The underlying pathology was acute cholecystitis in four cases and chronic cholecystitis in 22 cases. No malignancies were found in any case. No complications or conversion to open surgery were encountered (Table 2).

**Table 1** Patient characteristics

	<i>n</i> = 26
Age (years)	69 (range 43–82)
Sex (female:male)	8:18
Duration of symptoms (days)	81 (range 12–231)
PTGBD	4

PTGBD Percutaneous transhepatic gallbladder drainage

**Table 2** Outcomes

	<i>n</i> = 26
Operative time (min)	125 (range 60–215)
Postoperative hospital stay (days)	6 (range 3–21)
Drain placed (days in place)	15 (2 range 1–3)
Operative cholangiography	24
Conversion and complication rate (%)	0 ( <i>n</i> = 0)

Subhepatic drains were placed in 15 patients and remained in situ for a median of 2 days (range 1–3 days)

## Discussion

Safely dissecting the structures in Calot's triangle, when treating cases of cholecystitis, can pose a considerable challenge in both laparoscopic and open procedures. During open surgery, partial cholecystectomy with drainage of the gallbladder stump is occasionally used when the tissues in Calot's triangle prove hostile [8]. As in many other areas of surgical practice, the lessons of open surgery can be relearned and adapted to laparoscopy. The present results show that LSC represents a viable alternative to open conversion when performing dissection of Calot's triangle is deemed unsafe.

The primary reasons for conversion include factors such as difficulties in dissecting the tissues of Calot's triangle, an unclear anatomy, bleeding from the gallbladder fossa and bile duct injury [9, 10]. In the early edematous phase that occurs within 3–4 days from symptom onset, a plane exists between the gallbladder and surrounding viscera that assists in dissection [11]. Conversely, scarring and dense fibrotic adhesions render performing dissection more difficult in the delayed phase, increasing the conversion rate. Many reports thus recommend performing surgery early, within 3–4 days after symptom onset [12–15]. However, many patients are actually referred to the department of surgery after this early period and, therefore undergo elective surgery. In this study, the duration from the onset of symptoms to surgery was more than 2 months. Using methods to decrease the conversion rate is necessary in patients undergoing elective laparoscopic cholecystectomy for acute cholecystitis.

Twenty-two patients in this study were discharged within 1 week after undergoing surgery. Importantly, no wound infections were identified in any patient undergoing LSC. Our study group was relatively small; however, this finding may simply reflect the reduced wound infection rates observed in laparoscopic surgery [16].

When performing subtotal cholecystectomy, dissecting and ligating the cystic duct are very difficult. Using methods to close the cystic duct and prevent postoperative bile leakage is thus crucial. In this study, when significant difficulty was encountered in dissecting the gallbladder neck and Calot's triangle, we changed the procedure, suturing the remnant wall in the gallbladder neck for closure instead of ligating the cystic duct.

Intraoperative cholangiography is useful for improving the safety of LSC. In fact, no complications were encountered in the present study. One patient underwent postoperative EST for a retained common bile duct stone diagnosed on intraoperative cholangiography. Therefore, this procedure appears to help clinicians to understand the anatomy of the bile duct and avoid complications.

We cut open the part identified as most likely representing the cystic duct and performed operative cholangiography. If this process can correct a diagnosis intraoperatively, even if symptoms of common bile duct injury are identified, the damage can at least be stopped. As biliary tract problems can develop postoperatively, operative cholangiography should be performed in as many patients as possible.

One study reported a risk of conversion of 36.0 % and an overall incidence of postoperative complications of 18.5 % in patients with severe acute cholecystitis treated with laparoscopic cholecystectomy [17]. In comparison to the present findings, a previous study evaluating the use of LSC without operative cholangiography reported a similar postoperative patient stay and median operative time, with a superior rate of conversion and fewer complications [18]. Performing LSC with operative cholangiography appears to be a very useful manual skill.

One of the problems of LSC is that patients exhibiting complications of gallbladder cancer are not identified preoperatively. Gallbladder cancer is reportedly found unexpectedly in 0.2–0.8 % of patients undergoing laparoscopic cholecystectomy [19, 20]. If the gallbladder wall is cut open in patients with gallbladder cancer, abdominal dissemination and remnant tumors are always observed. In our series of LSC, no cases of unexpected gallbladder cancer were identified. No reports have described diagnosing gallbladder cancer after LSC at our hospital. Distinguishing gallbladder tumors from simple inflammatory wall thickness can be difficult. At our institute, we carefully examine the thickness of the gallbladder wall preoperatively, and when laboratory findings, such as ultrasonography, contrast-enhanced computed tomography or tumor markers, show results suspicious of cancer, we perform open cholecystectomy. When even the slight suspicion of cancer is present, we perform laparoscopic total cholecystectomy, taking care to prevent leakage of bile juice. The rate of gallbladder cancer recurrence increases when the gallbladder is punctured intraoperatively and pancreatic juice leaks into the peritoneal cavity [19]. LSC should not be performed in patients with gallbladders with an increased wall thickness due to cancer, and gallbladder tumors must be excluded preoperatively. The use of LSC should thus be restricted to patients with benign gallbladders in which dissecting the neck and wall is difficult. Providing additional treatment can be considered when cancer is diagnosed on pathological examinations after surgery. General treatments for gallstones include bile duct resection, liver floor excision, lymph node dissection and port site excision.

We do not advocate the use of LSC as a routine procedure or consider it to be a substitute for the presence of

an experienced and skilled laparoscopic surgeon. However, we have demonstrated that LSC is a viable technique that reduces the risk of bile duct injury in the most difficult cases of emergency or elective cholecystectomy while maintaining the other benefits of a laparoscopic approach.

Performing LSC for acute cholecystitis is safe and particularly effective in patients unable to undergo early surgery. Using this procedure, if difficulty is encountered when dissecting the neck and Calot's triangle, isolating the cystic duct is unnecessary; and the conversion rate decreases by devising suitable treatments of the gallbladder neck. Although our method has shown good results with minimal invasiveness, the risk of recurrence of gallstones cannot be completely denied. Ablation of the mucosa of the gallbladder may indeed minimize the recurrence of gallstones; however, we should evaluate the outcomes based on the long-term follow-up.

**Conflict of interest** None of the authors have any conflicts of interest to declare.

**Open Access** This article is distributed under the terms of the Creative Commons Attribution License which permits any use, distribution, and reproduction in any medium, provided the original author(s) and the source are credited.

## References

- Beldi G, Glattli A. Laparoscopic subtotal cholecystectomy for severe cholecystitis. *Surg Endosc*. 2003;17:1437–9.
- Lawes D, Motson RW. Anatomical orientation and cross-checking: the key to safer laparoscopic cholecystectomy. *Br J Surg*. 2005;92:663–4.
- Chowbey PK, Sharma A, Khullar R, Mann V, Baijal M, Vashistha A. Laparoscopic subtotal cholecystectomy: a review of 56 procedures. *J Laparoendosc Adv Surg Tech A*. 2000;10:31–4.
- Michalowski K, Bornman PC, Krige JE, Gallaher PJ, Terblanche J. Laparoscopic subtotal cholecystectomy in patients with complicated acute cholecystitis or fibrosis. *Br J Surg*. 1998;85:904–6.
- Ransom KJ. Laparoscopic management of acute cholecystitis with subtotal cholecystectomy. *Am Surg*. 1998;64:955–7.
- Ikeda T, Yonemura Y, Ueda N, Kabashima A, Mashino K, Yamashita K, Fujii K, Tashiro H, Sakata H. Intraoperative cholangiography using an endoscopic nasobiliary tube during a laparoscopic cholecystectomy. *Surg Today*. 2011;41(5):667–73.
- Watanabe Y, Sato M, Abe Y, Iseki S, Sato N, Kimura S. Preceding PTGBD decreases complications of laparoscopic cholecystectomy for patients with acute suppurative cholecystitis. *J Laparoendosc Surg*. 1996;6:161–5.
- Cottier DK, McKay C, Anderson JR. Subtotal cholecystectomy. *Br J Surg*. 1991;78:1326–8.
- Bingener-Casey J, Richards ML, Strodel WE, Schwesinger WH, Sirinek KR. Reasons for conversion from laparoscopic to open cholecystectomy: a 10-year review. *J Gastrointest Surg*. 2002;6:800–5.
- Lo CM, Liu CL, Fan ST, Lai EC, Wong J. Prospective randomized study of early versus delayed laparoscopic cholecystectomy for acute cholecystitis. *Ann Surg*. 1998;227:461–7.
- Knight JS, Mercer SJ, Somers SS, Walters AM, Sadek SA, Toh SK. Timing of urgent laparoscopic cholecystectomy does not influence conversion rate. *Br J Surg*. 2004;91:601–4.
- Gharaibeh KI, Osaimeh GR, Al-Heiss H, Ammari F, Bani-Hani K, Al-Jaberi TM, et al. Effect of timing of surgery, type of inflammation, and sex on outcome of laparoscopic cholecystectomy for acute cholecystitis. *J Laparoendosc Adv Surg Tech A*. 2002;12:193–8.
- Lau H, Lo CY, Patil NG, Yuen WK. Early versus delayed-interval laparoscopic cholecystectomy for acute cholecystitis: a metaanalysis. *Surg Endosc*. 2006;20:82–7.
- Pessaux P, Tuech JJ, Rouge C, Duplessis R, Cervi C, Arnaud JP. Laparoscopic cholecystectomy in acute cholecystitis. A prospective comparative study in patients with acute vs. chronic cholecystitis. *Surg Endosc*. 2000;14:358–61.
- Serralta AS, Bueno JL, Planells MR, Rodero DR. Prospective evaluation of emergency versus delayed laparoscopic cholecystectomy for early cholecystitis. *Surg Laparosc Endosc Percutan Tech*. 2003;13:71–5.
- Chuang SC, Lee KT, Chang WT, Wang SN, Kuo KK, Chen JS, et al. Risk factors for wound infection after cholecystectomy. *J Formos Med Assoc*. 2004;103:607–12.
- Giuseppe B, Stefan S, Anna MM, Giuseppe B. Laparoscopic cholecystectomy for severe acute cholecystitis. A meta-analysis of result. *Surg Endosc*. 2008;22:8–15.
- Philips JAE, Lawes DA, Cook AJ, Arulampalam TH. The use of laparoscopic subtotal cholecystectomy for complicated cholelithiasis. *Surg Endosc*. 2008;22:1697–700.
- Ouchi K, Mikuni J, Kakugawa Y, Organizing Committee of the 30th Annual Congress of the Japanese Society of Biliary Surgery. Laparoscopic cholecystectomy for gallbladder carcinoma: results of a Japanese survey of 498 patients. *J Hepatobiliary Pancreat Surg*. 2002;9:256–60.
- Yamamoto H, Hayakawa N, Kitagawa Y, Katohno Y, Sasaya T, et al. Unsuspected gallbladder carcinoma after laparoscopic cholecystectomy. *J Hepatobiliary Pancreat Surg*. 2005;12:391–8.