



Contents lists available at ScienceDirect

Journal of Hand Surgery Global Online

journal homepage: www.JHSGO.org

Case Report

Spontaneous Extensor Pollicis Longus Rupture Associated With an Extensor Digitorum Brevis Manus

Andrew Z. Coskey, MD, * Grant R. McChesney, MD, * John J. Faillace, MD *

* Department of Orthopaedic Surgery and Rehabilitation, The University of Texas Medical Branch, Galveston, TX



ARTICLE INFO

Article history:

Received for publication July 25, 2022
 Accepted in revised form October 5, 2022
 Available online November 3, 2022

Key words:

Anatomic variation
 Interphalangeal joint of finger
 Surgical procedures
 Tendon injuries
 Tendon transfer

A 64-year-old left-handed man with no history of rheumatoid arthritis or distal radius fracture presented with spontaneous loss of thumb interphalangeal joint extension. Intraoperatively, the patient was found to have a variant extensor indicis proprius with extensor digitorum brevis manus. Prior extensor digitorum communis ruptures have been reported in the literature secondary to the distal extensor digitorum brevis manus muscle belly, but there are no prior reports of extensor pollicis longus rupture. This case demonstrates a unique etiology of extensor pollicis longus rupture and highlights the alteration in the surgical plan required secondary to the absence of an extensor indicis proprius tendon.

Copyright © 2022, THE AUTHORS. Published by Elsevier Inc. on behalf of The American Society for Surgery of the Hand. This is an open access article under the CC BY-NC-ND license (<http://creativecommons.org/licenses/by-nc-nd/4.0/>).

Spontaneous extensor pollicis longus (EPL) tendon ruptures are rare and typically occur in patients with underlying rheumatoid arthritis or after distal radius fracture. Less commonly, EPL ruptures have been reported after a history of steroid injection, chronic overuse, or tenosynovitis.^{1,2} Because of its role in thumb extension, as well as its contribution to strong grip and pinch, repair of a ruptured EPL is often indicated. Occasionally, EPL ruptures may be repaired end-to-end; however, this is the exception. Tendon transfers are the most often employed method.^{3,4} The preferred tendon transfer is extensor indicis proprius (EIP) to EPL. In cases where EIP may be insufficient, a split-thickness transfer of extensor digitorum communis to the index finger (EDC2) may be used.³ Additional transfer options include extensor carpi radialis longus, palmaris longus, and extensor pollicis brevis.^{5,6}

The authors present a case of spontaneous EPL rupture in a patient with no known risk factors for rupture, with a unique anatomic variation. The extensor digitorum brevis manus (EDBM) is an aberrant finger extensor that inserts into either the index or middle finger. It may exist in concert with a variation of the EIP or be the only muscle responsible for the extension of the index finger.^{1,2} An EDBM is typically clinically asymptomatic but may

present as a painful mass.² Rupture of the third extensor digitorum communis (EDC) tendon secondary to the presence of an EDBM is reported in the literature.³ In our case, the discovery of an EDBM in the absence of an EIP forced an alteration of our surgical plan to split the EDC2 transfer.

Case

Informed consent was obtained from the patient for the publication of this case report and accompanying images. A 64-year-old left-handed man presented to our clinic with insidious onset of left wrist and arm pain and numbness over the dorsal left thumb for the past 2 months. He stated that he reached down to grab something and felt a “pop” in his left thumb, with the inability to extend the digit. He denied any history of trauma or a distal radius fracture. He had no prior hand surgeries. His medical history includes transient ischemic attacks without residual deficits. There was no history of steroid injections into the wrist or rheumatoid arthritis, confirmed by a negative rheumatoid factor, antibodies to the nuclear antigen, anti-cyclic citrullinated peptide, and without erythrocyte sedimentation rate or C-reactive protein elevations. Operative treatment options were discussed, and the patient elected to have tendon transfer and EPL reconstruction.

The operation started with a small transverse incision made over the second metacarpal to release the EIP distally for harvest. The EIP was dissected free and transected as distally as the wound allowed. Then, a second incision was made between the third and fourth extensor compartments over the carpus. The fourth

Declaration of interests: No benefits in any form have been received or will be received related directly or indirectly to the subject of this article.

Corresponding author: John J. Faillace, MD, Department of Orthopaedic Surgery and Rehabilitation, The University of Texas Medical Branch, 2.316 Rebecca Sealy, 301 University Blvd, Galveston, TX 77555-0165.

E-mail address: jofailla@utmb.edu (J.J. Faillace).

<https://doi.org/10.1016/j.jhsg.2022.10.006>

2589-5141/Copyright © 2022, THE AUTHORS. Published by Elsevier Inc. on behalf of The American Society for Surgery of the Hand. This is an open access article under the CC BY-NC-ND license (<http://creativecommons.org/licenses/by-nc-nd/4.0/>).

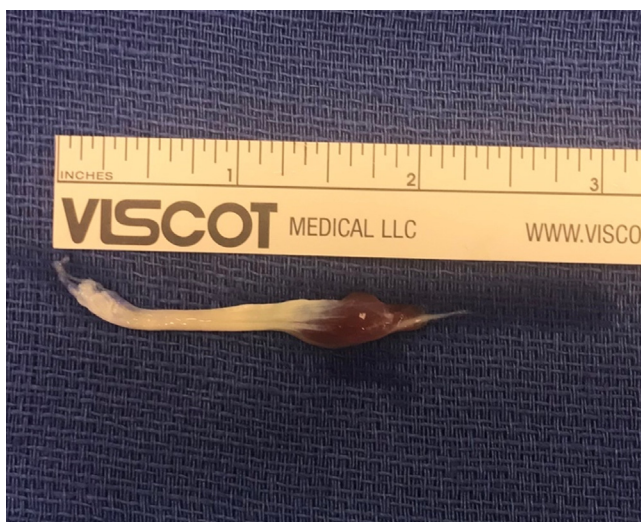

Figure 1. The extensor digitorum brevis manus excised with the short muscle belly and the tendon.

compartment was identified, and the retinaculum was partially incised with a pair of tenotomy scissors. No effect on the tendons within the fourth compartment was identified when tension was applied to the cut end of the EIP distally. The incision was extended distally to explore the EIP tendon. The tendon was truncated with a distal muscle belly underlying the fourth compartment tendons (Fig. 1). The length and position were inadequate to transfer to the EPL (Fig. 2), and the decision was made to harvest half of the second EDC back to the level of the wrist crease for transfer. A third incision was made dorsal to the ulnar insertion over the thumb at the distal end of the ruptured EPL tendon. The EDC split graft was tunneled from the wrist crease to the third incision. A Pulvertaft weave was performed and secured with 4-0 Fiberwire (Arthrex). The tenodesis effect was checked thereafter to confirm the adequate tension of the repair (Fig. 3).

The patient was followed up for 2 weeks postoperatively with improvement in his numbness. No range of motion or strength examination was performed at that time, secondary to the earlier nature of the repair. He was scheduled for a follow-up 1 month later, with plans for hand therapy for range of motion exercises. At his 2-year follow-up, the patient had a full range of motion of the thumb without notable deficits.

Discussion

Spontaneous rupture of the EPL continues to be rare and creates functional limitations for patients. While there are known risk factors that contribute to EPL rupture, the exact pathophysiology is unknown. There are 2 working theories: mechanical irritation and/or vascular insult.^{4–6} The close anatomic relationship of the EPL tendon to Lister's tubercle makes this a site of irritation. In this region, the tendon slowly transitions into its thin synovial sheath, allowing for smooth gliding of the tendon. While the synovial sheath provides some protection for the tendon, it is not sturdy enough to protect it from the sharp cortical bone or osteophytes that form in response to callous formation in nondisplaced or minimally displaced distal radius fractures.

The mechanical irritation theory follows the logic that bony irritation causes tearing of the tendon as it slides across any sharp cortical step-off formed during fracture healing.⁴ In addition, as the tendon traverses toward its attachment at the dorsal base of the

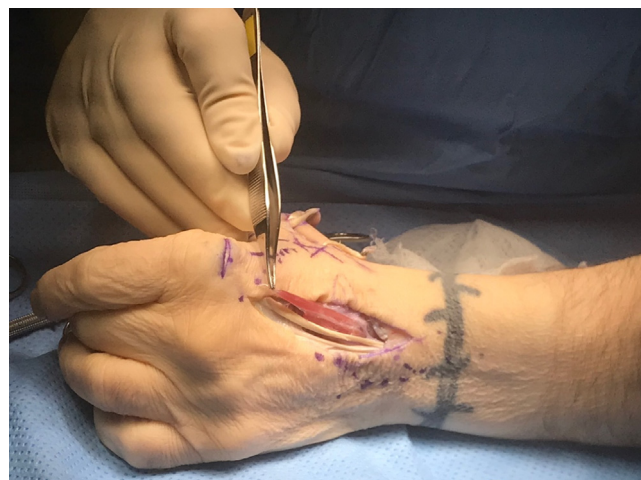

Figure 2. The appearance of the extensor digitorum brevis manus encountered intraoperatively.

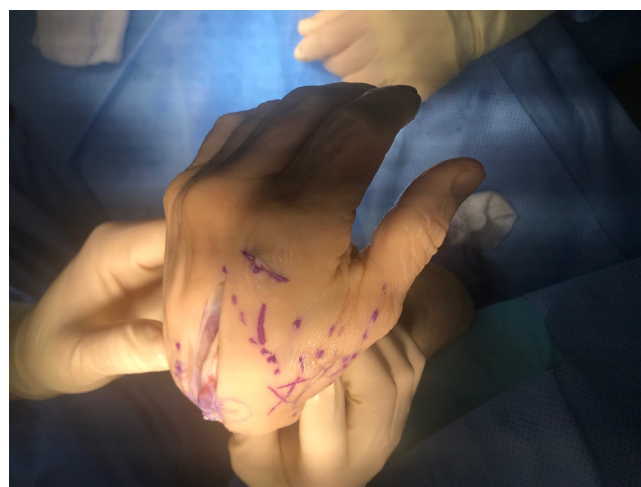


Figure 3. A display of the tenodesis effect after completion of the extensor pollicis longus repair.

thumb interphalangeal joint, it passes by Lister's tubercle, which acts as a site of tension and can cause tearing of the tendon. In the vascular insult theory, it is thought that the portion of the tendon that passes by Lister's tubercle is a relatively avascular zone. Avascular areas are completely dependent on the surrounding synovial fluid for nutrition.^{4–6} Any insult that compromises the synovium, such as a hematoma during fracture, can injure the tendon, which predisposes it to rupture. Acute hematoma can constrict the surrounding vasculature and produce an oxygen-deprived environment. Thus, the area of the tendon that is already vulnerable to injury and reliant on a poor nutrition source, the synovium, is under stress by the surrounding environment.

During the surgical dissection of the EIP, we encountered a small tendon with a muscle belly that was subsequently identified as an EDBM. This muscle is a normal variant of the hand that has received more attention recently.¹ The EDBM has been described in the literature with an incidence of approximately 3%.^{2,7} Ogura et al⁷ described a classification system for the EDBM variant based on the origin of insertion in relation to the EIP (Table 1). The EDBM encountered during our dissection is a type I EDBM. A newer and more complex classification has been recently described.¹

Table 1
Classification System for the Extensor Digitorum Brevis Manus Variant Based on the Origin and Insertion in Relation to the Extensor Indicis Proprius (EIP)

Type	Origin	Insertion
I (absent EIP)	Proximal posterior radiocarpal ligament near the lunate	Dorsal aponeurosis of the index finger
IIa	With vestigial EIP at the ulna	Separate tendon with shared insertion of EIP at the index finger
IIb	With vestigial EIP at the ulna	Distal muscle belly joins EIP with single tendon insertion at the index finger
IIc	With vestigial EIP at the ulna	Separate tendon with ulnar insertion at the index finger
III	With vestigial EIP at the ulna	Long finger insertion with or without the accessory EIP

Several authors have described EDBM as being misdiagnosed as a dorsal wrist ganglion or identifying EDBM with a ganglion present.^{8–10} This space-occupying ganglion could be a potential source of EIP rupture, given its anatomic relation to Lister's tubercle; however, this is purely speculative.

While EIP variations have been discussed in the literature, we are not aware of any literature describing their effects on hand surgery or causing a tendon rupture. While there is no other identified cause for this patient's EPL rupture, there is no clear evidence as to the EDBM's contribution to the EPL rupture. More work is needed to understand this relationship and how it affects outcomes in hand surgery.

In conclusion, knowing that anatomical variants exist while planning hand surgery is important for being prepared with multiple options to accomplish the surgical goals. While we have better anatomical knowledge of EIP variants like EDBM, we still do not have good diagnostic tools to determine their presence prior to surgery. Ultimately, this case highlighted the need for the surgeon to have a good backup plan and our need to have a better understanding of the relationship of EDBM to EPL ruptures.

References

- Georgiev GP, Tubbs RS, Iliev A, Kotov G, Landzhov B. Extensor indicis proprius muscle and its variants together with the extensor digitorum brevis manus muscle: a common classification. Clinical significance in hand and reconstructive surgery. *Surg Radiol Anat.* 2018;40(3):271–280.
- Ranade AV, Rai R, Prabhu LV, et al. Incidence of extensor digitorum brevis manus muscle. *Hand (N Y).* 2008;3(4):320–323.
- Ishizuki M, Furuya K, Kumakura T. Extensor digitorum brevis manus associated with attrition rupture of a common extensor tendon. *J Hand Surg Am.* 1986;11(4):582–584.
- Engkvist O, Lundborg G. Rupture of the extensor pollicis longus tendon after fracture of the lower end of the radius—a clinical and microangiographic study. *Hand.* 1979;11(1):76–86.
- Hu CH, Fufa D, Hsu CC, Lin YT, Lin CH. Revisiting spontaneous rupture of the extensor pollicis longus tendon: eight cases without identifiable predisposing factor. *Hand (N Y).* 2015;10(4):726–731.
- Kim CH. Spontaneous rupture of the extensor pollicis longus tendon. *Arch Plast Surg.* 2012;39(6):680–682.
- Ogura T, Inoue H, Tanabe G. Anatomic and clinical studies of the extensor digitorum brevis manus. *J Hand Surg Am.* 1987;12(1):100–107.
- Fernandez Vazquez JM, Linscheid RL. Anomalous extensor muscles simulating dorsal wrist ganglion. *Clin Orthop Relat Res.* 1972;83:84–86.
- Slavchev SA, Georgiev GP. Ultrasound diagnosis of a ganglion cyst within an extensor digitorum brevis manus muscle. *Chir Main.* 2015;34(5):269–271.
- Murakami Y, Todani K. The extensor indicis brevis muscle with an unusual ganglion. *Clin Orthop Relat Res.* 1982;(162):207–209.