



Review Article

# Spinal arachnoiditis and syringomyelia: Review of literature with emphasis on postinfectious inflammation and treatment

Syed Faisal Nadeem<sup>1</sup>, Ahmer Nasir Baig<sup>2</sup>, Qurat ul Ain Tariq<sup>2</sup>, Muhammad Shahzad Shamim<sup>2</sup>

<sup>1</sup>Department of Neurosurgery, Medical College, The Aga Khan University, <sup>2</sup>Department of Neurosurgery, Aga Khan University Hospital, Karachi, Sindh, Pakistan.

E-mail: Syed Faisal Nadeem - syed.nadeem@aku.edu; Ahmer Nasir Baig - ahmer.baig@aku.edu; Qurat ul Ain Tariq - quratulain.tariq@aku.edu;

\*Muhammad Shahzad Shamim - shahzad.shamim@aku.edu



**\*Corresponding author:**

Muhammad Shahzad Shamim,  
Department of Neurosurgery,  
Aga Khan University Hospital,  
Karachi, Sindh, Pakistan.

shahzad.shamim@aku.edu

Received : 24 April 2022

Accepted : 23 June 2022

Published : 15 July 2022

DOI

10.25259/SNI\_383\_2022

Quick Response Code:



## ABSTRACT

**Background:** Arachnoiditis refers to chronic inflammation of the arachnoid mater and subarachnoid space due to three major etiologies: chemical, mechanical, and postinfectious. As a rare disease with variable symptomatology and severity at presentation, arachnoiditis can be extremely debilitating with many complications, prominent among which is syringomyelia.

**Methods:** We reviewed current literature concerning postinfectious spinal arachnoiditis and associated syringomyelia with emphasis on the treatment options that have been used to date and discuss their respective benefits and drawbacks.

**Results:** It is critical to understand the natural history and potential complications of patient with postinfectious arachnoiditis. Surgical and medical treatments both have their own merits and demerits. Different surgical approaches have been employed with variable success rates.

**Conclusion:** At present, no consensus exists regarding management of these patients due to the variable nature of the disease that affects treatment efficacy; however, surgical intervention in selected cases may be beneficial.

**Keywords:** Arachnoiditis, Meninges, Scarring, Shunt, Syringomyelia

## INTRODUCTION

Arachnoiditis is a persistent inflammation of the arachnoid mater and the subarachnoid space due to a diverse range of etiologies that can be grouped into three major categories: chemical, mechanical, and postinfectious.<sup>[6]</sup> Often in the literature, the term arachnoiditis has been used to refer specifically to inflammation of the spinal meninges rather than the intracranial ones, for which the more common term “meningitis” is used.<sup>[16]</sup> In this review, we focus on infections involving the spinal cord and the meninges as a cause of spinal arachnoiditis.

## REVIEW OF LITERATURE

Inflammation in the arachnoid mater results in the deposition of collagen and generation of scar tissue that encapsulates nerve roots of the spinal cord, tethering them together and depriving

This is an open-access article distributed under the terms of the Creative Commons Attribution-Non Commercial-Share Alike 4.0 License, which allows others to remix, transform, and build upon the work non-commercially, as long as the author is credited and the new creations are licensed under the identical terms.

©2022 Published by Scientific Scholar on behalf of Surgical Neurology International

them of adequate blood supply. This leaves the nerve roots undernourished, hypoxic, and exposed to waste metabolites, eventually culminating in spinal nerve atrophy and its associated neurologic deficits.<sup>[2,13]</sup>

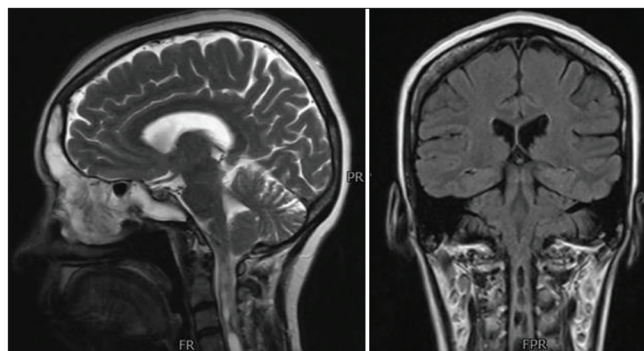
Arachnoiditis as a condition has variable severity and clinical manifestations with many of the cases being mild or subclinical and hence going undiagnosed. These factors, together with the absence of a unified nomenclature to describe the condition, make it difficult to estimate epidemiological parameters (most notably the incidence) for the disease.<sup>[2,10,30]</sup> Di Ieva *et al.* postulated though that despite the rarity, clinical arachnoiditis cases are rising globally, a development they believe to be associated with the increasing incidence of immunocompromised states and their resulting opportunistic infections.<sup>[9]</sup>

A review of literature suggests a number of different infectious agents to be involved in causing arachnoiditis including *Mycobacterium tuberculosis*, *Cryptococcus*, *Coccidioides*, *Taenia solium* (neurocysticercosis), and *Histoplasma* to name a few.<sup>[4,5,24,25,27]</sup> Of these pathogens, tuberculosis appears to be significantly associated in patients having a positive HIV status.<sup>[1,28]</sup>

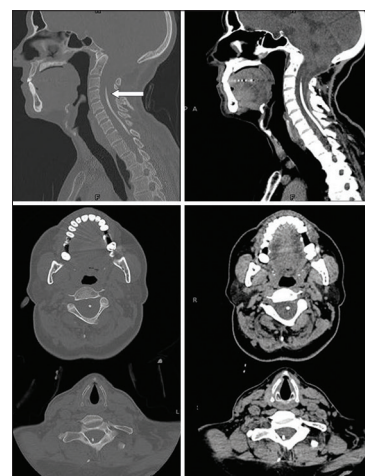
Clinical arachnoiditis presents very similarly to other diseases involving spinal nerve compression with a range of symptoms including burning lower back pain that radiates down the legs – urinary urgency, frequency, and incontinence – muscle spasms in the back and legs – sensory deficits below the lesion site – and paraplegia or paraparesis. Due to the insidious development of the disease, finding an underlying cause can often be difficult.<sup>[33]</sup>

Syringomyelia has been frequently associated with arachnoiditis [Figure 1]. When caused by adhesive arachnoiditis, the incidence is 2–4 cases/100,000 population<sup>[34]</sup> while it is estimated that around 1–2% of patients with active tuberculous meningitis will go on to develop syringomyelia.<sup>[17,34]</sup> A number of cases of infectious spinal arachnoiditis progressing to syringomyelia have been reported in the literature including those involving Pott's disease, *Listeria monocytogenes* meningoencephalitis, tuberculous arachnoiditis, and *Candida tropicalis* spinal arachnoiditis.<sup>[11,12,14,15,17,18,23,26]</sup> Interestingly, the direct association between syringomyelia and arachnoiditis is relatively rare as compared to the association of both arachnoiditis and syringomyelia with Chiari malformation, suggesting that the two may also be indirectly related through an underlying anatomical deformity.<sup>[8,20,29]</sup> Caplan *et al.* presented a five patients case series of patients with arachnoiditis who went on to develop syringomyelia.<sup>[3]</sup> They provide two possible theories for how arachnoiditis could lead to syrinx formation:

i. The meningeal scarring produces pathologic changes in the meningeal vessels and in extension those supplying the spinal cord, causing focal ischemia and resulting necrosis which causes syrinx formation,



**Figure 1:** A patient who developed syringomyelia after postinfectious arachnoiditis.



**Figure 2:** A patient who underwent surgical insertion of a syngo-subdural shunt (white arrow) after developing postinfectious arachnoiditis and syringomyelia.

ii. The scarring itself impedes communication between the subdural and subarachnoid spaces and impedes cerebrospinal fluid flow through the spinal cord, causing it to move out of these spaces and into the central canal, producing a syrinx.

Another theory for syringomyelia formation secondary to a tethered spinal cord (a spinal cord adhered to the tissues surrounding it, often a sequela of arachnoiditis) is proposed by Tsitouras and Sgouros.<sup>[31]</sup> According to them, not only does the scarring impair normal cerebrospinal fluid flow in the subarachnoid space but it also exerts an outward radial traction on the spinal cord, causing widening of the central canal and development of negative pressure inside it, causing accumulation of extracellular fluid within it. The extracellular fluid collection can cause further widening of the cavity if its flow through the central canal is impeded.<sup>[31]</sup>

Complete alleviation of the pain and debility associated with spinal arachnoiditis is often not possible and the target

of intervention is to reduce the pain experienced by the patient to the greatest extent.<sup>[33]</sup> Since arachnoiditis is an inflammatory disorder at its core, the literature advocates for the use of anti-inflammatory agents (NSAIDs and steroids) to slow the progression of the disease.<sup>[8]</sup> These drugs, along with opioid analgesics, can also be used to reduce the pain experienced by the patients. In patients who are refractory to pharmacologic treatment, direct spinal cord stimulation can be used to provide analgesia by causing synaptic inhibition within the spinal cord.<sup>[33]</sup> Thalamic stimulation has also been used by Turnbull *et al.* to relieve arachnoiditis pain, achieving pain relief in five of nine patients with lumbar arachnoiditis.<sup>[32]</sup> Surgical management of spinal arachnoiditis, aimed at removing scar tissue, is a last resort treatment used only when all conservative treatment options have been exhausted due to the high risk of precipitating further scarring due to the surgery itself.<sup>[33]</sup> Esses and Morley's review on surgical management of spinal arachnoiditis does not offer encouraging results. While short-term pain reduction was achieved after decompressive laminectomy and microscopic lysis of arachnoid lesions, the symptoms recurred in the long term due to the formation of scar tissue.<sup>[10]</sup> They also discuss possible adjuvant treatments to reduce postprocedure fibrosis, including colchicine, intrathecal steroids, and radiotherapy. In addition to the standard decompressive laminectomy and removal of scar tissue under microscope, Wright and Denney also shed light on the placement of a shunt to bypass the stenosed portions of the spinal cord to allow uninterrupted cerebrospinal fluid flow, as well as vertebral fusion to prevent postoperative arachnoiditis since spinal mobility was found to be associated with the development of arachnoiditis [Figure 2].<sup>[33]</sup> This surgical method saw an 80% success rate in significantly reducing pain in its patient population over an average follow-up period of more than 4 years.

Surgical management of syringomyelia in patients with preexisting arachnoiditis also appears to have mixed success rates in the current literature. Davidoff *et al.* review the treatment received by eight patients who had syringomyelia secondary to craniocervical junction arachnoiditis.<sup>[7]</sup> All eight patients received posterior fossa decompression, division of adhesions, and expansile duroplasty, six of the eight patients had a shunt inserted between the fourth ventricle and spinal subarachnoid space, and two patients received titanium mesh plate cranioplasty to expand the subarachnoid space by pulling the implanted dural substitute tissue outward. All patients experienced marked clinical improvement and a significant reduction in syrinx cavity size over a mean follow-up time of 27 months (range 10–60 months). Three patients had to be reoperated due to recurrence of syrinx at an average of 32 months from the first procedure (range 24–39 months): the second operation involved revision of the fourth ventricle to spinal subarachnoid space shunt in all cases, revision

posterior fossa decompression in two cases, and revision duroplasty in one case. In one case, a shunt had to be placed connecting the syrinx with the subarachnoid space due to persistence of a symptomatic syrinx in the thoracic spinal cord 5 months postprocedure despite regression of the more rostral portion of the syrinx. In all four cases undergoing reoperation, there was no further syrinx recurrence 15–52 months following the second procedure.<sup>[7]</sup>

Zuev *et al.* discussed their experience on surgically treating 34 patients with syringomyelia secondary to adhesive arachnoiditis.<sup>[34]</sup> Twenty-five patients underwent pathogenetic treatment involving microscopic dissection of adhesions, spinal cord detethering, and restoration of normal cerebrospinal fluid flow through the previously stenosed region. In the remaining nine patients, a silicone shunt was placed into the syrinx and connected with the subarachnoid, pleural, or peritoneal spaces. These nine patients had either refused pathogenetic treatment in favor of shunt placement or were not suitable candidates for it since they had more advanced arachnopathy. In the nine patients treated with shunt placement, seven demonstrated immediate postoperative reduction in syrinx size and eight of nine showed significant clinical improvement postprocedure. However, four began to suffer an increase in cyst size, seven returned to baseline functionality, and six saw further progression of disease within the 1<sup>st</sup> postoperative year. With pathogenetic treatment, promising long-term improvement was seen only in those with Grades 1–2 arachnopathy. In those with Grade 3 arachnopathy, although none showed worsening disease in the immediate postoperative period, just 50% of patients were clinically stabilized by the end of the 1<sup>st</sup> postoperative year. In the four patients with Stage 4 arachnopathy, two showed immediate postoperative worsening of their symptoms, and progression of disease could only be halted in one patient. Postoperative reduction in syrinx size also followed a similar pattern, with 73.3% of patients with Grades 1–2 and 30% of patients with Grades 3–4 arachnopathy demonstrating reduction in syrinx size during the follow-up period. About 9% of patients with Grades 1–2 arachnopathy demonstrated a postoperative increase in syrinx size compared to 50% in patients with Grades 3–4 arachnopathy. It seems from these results that the stage of arachnoiditis is a significant determinant as to the efficacy of surgical intervention, with more advanced disease being accompanied by worse postoperative prognoses. Restoration of proper spinal cord and meningeal anatomy allowing for unimpeded cerebrospinal fluid flow is imperative for the prevention of syrinx recurrence and a prerequisite, according to Tsitouras and Sgouros for subsequent surgical intervention directly against the syringomyelia itself.<sup>[31]</sup> This might explain why surgical efficacy is reduced with advancing stage of disease: since

the baseline anatomy of the spinal cord and its meninges is so profoundly deteriorated, even after intervention, there remains impediment to the unrestricted flow of cerebrospinal fluid that, coupled with the scarring induced by the surgical procedure itself, reduces the long-term benefits of surgical intervention.

Kannapadi *et al.*<sup>[17]</sup> reviewed literature around the treatment of syringomyelia associated with tuberculous arachnoiditis. They provide a comparison between medical versus surgical intervention. Thirty-three patients were studied in total of which 11 were only medically treated, a further 19 received surgical treatment (of which 12 also received concomitant medical therapy), and three received no treatment. Of the medically treated patients, 25 received some combination of the four standard anti-TB drugs and eight of these 25 also received adjunctive steroids. Of the 19 patients surgically managed, 15 received syringo-subarachnoid, syringoperitoneal, or syringopleural shunts, and six underwent laminectomy. The results showed surgery to be more efficacious than sole medical treatment as 74% of surgically treated patients reported improvement in any symptom versus 45% of medically treated patients. About 47% and 37% of surgically treated patients reported improvement in motor and sensory function, respectively, versus 36% and 9% of their conservatively managed counterparts. About 16% of surgical patients complained of worsening of any symptoms versus 18% of medically treated patients. About 32% of surgically managed patients saw a complete or partial resolution of their syrinx compared to 27% of medically managed patients. These results should, however, be interpreted with caution as none were found to reach statistical significance. None of the patients achieved a complete recovery back to their usual state of health before tuberculous arachnoiditis. A rather unique observation in this study was that at the time of syringomyelia presentation, patients managed medically only were significantly more likely to have paralysis compared to those managed surgically ( $P < 0.05$ ). It is plausible the caregivers chose to surgically intervene or not based on how much benefit each patient could potentially get from surgery.<sup>[17]</sup>

Naito *et al.* provided a retrospective analysis of the safety and efficacy of syringoperitoneal shunting in patients with syringomyelia secondary to spinal adhesive arachnoiditis. Average functionality (measured using the modified McCormick functional schema) was preserved at 4.8 at the most recent follow-up visit (compared to 4.7 preoperatively) while there was significant improvement in pain (measured using the sensory pain scale), which reduced from 2.9 preoperatively to 2.5 at the most recent follow-up visit. About 93.3% of patients reviewed showed radiographic improvement in their syringomyelia and there were no reported recurrences postoperatively. Comparing it to microsurgical

arachnoidolysis, Naito *et al.* champion CSF shunt placement as a safer treatment option, since arachnoidolysis is both more technically demanding and associated with a high risk of postoperative neurologic deterioration due to iatrogenic meningeal scarring.<sup>[22]</sup> This opinion is seconded by Morisako *et al.* who also express the importance of MRI diagnosis to determine microsurgical arachnoidolysis indication in these patients since such interventions are mostly efficacious in localized disease.<sup>[21,32,33]</sup> Klekamp *et al.* found that while 83% of patients with a focal arachnoid scar experienced a stabilization in their preoperative symptoms after undergoing microsurgical arachnoid scar dissection, just 17% of patients with extensive multilevel scarring experienced similar postoperative stabilization, further adding to the notion that patients with localized arachnoid scarring are the best candidates for microsurgical arachnoidolysis.<sup>[19]</sup>

## CONCLUSION

The literature concerning management of patients with infectious arachnoiditis and concomitant syringomyelia lacks consensus on whether surgical management is better than conservative management or vice versa and also provides different levels of efficacy for each based on the extent and severity of the underlying disease. A number of different surgical techniques have also been elucidated with their own benefits and drawbacks in individual conditions, they were applied in. It would thus be prudent to conclude that management of the patient population in question should be closely tailored to the individual patients' needs, taking into account their preoperative level of functionality and extent of disease. Imaging studies may prove helpful for selecting treatment options for these patients.

## Declaration of patient consent

Patients' consent not required as patients' identity is not disclosed or compromised.

## Financial support and sponsorship

Nil.

## Conflicts of interest

There are no conflicts of interest.

## REFERENCES

1. Alatorre-Fernández CP, Venzor-Castellanos JP, Contreras-Cabrera JA, Fuentes-venegas A, Castro-Martínez E. Arachnoiditis and tuberculous cortical encephalitis in an HIV+ patient. *Gaceta Medica Mexico* 2009;145:239-40.
2. Anderson TL, Morris JM, Wald JT, Kotsenas AL. Imaging appearance of advanced chronic adhesive arachnoiditis:

- A retrospective review. *AJR Am J Roentgenol* 2017;209:648-55.
3. Caplan LR, Norohna AB, Amico LL. Syringomyelia and arachnoiditis. *J Neurol Neurosurg Psychiatry* 1990;53:106-13.
  4. Cárdenas G, Aristizábal S, Salinas C, Delgado-Hernández R, Angeles-Morales V, Soto-Hernández J, et al. Coccidioidal meningitis in non-AIDS patients. A case series at a Mexican neurological referral center. *Clin Neurol Neurosurg* 2020;196:106011.
  5. Cherian A, Ajitha KC, Iype T, Divya KP. Neurotuberculosis: An update. *Acta Neurol Belg* 2021;121:11-21.
  6. Conermann T. Arachnoiditis. Treasure Island, FL: Stat Pearls Publishing; 2021.
  7. Davidoff CL, Liu S, Wong JHY, Koustais S, Rogers JM, Stoodley MA. Treatment of syringomyelia in patients with arachnoiditis at the craniocervical junction. *World Neurosurg* 2017;107:565-73.
  8. Demetriades AK. Arachnoiditis and Chiari I malformation. *Acta Neurochir (Wien)* 2021;163:227-8.
  9. Di Ieva A, Barolat G, Tschabitscher M, Rognone E, Aimar E, Gaetani P, et al. Lumbar arachnoiditis and thecaloscopy: Brief review and proposed treatment algorithm. *Cent Eur Neurosurg* 2010;71:207-12.
  10. Esses SI, Morley TP. Spinal arachnoiditis. *Can J Neurol Sci* 1983;10:2-10.
  11. Fehlings MG, Bernstein M. Syringomyelia as a complication of tuberculous meningitis. *Can J Neurol Sci* 1992;19:84-7.
  12. Garg RK, Malhotra HS, Gupta R. Spinal cord involvement in tuberculous meningitis. *Spinal Cord* 2015;53:649-57.
  13. Guyer DW, Wiltse LL, Eskay ML, Guyer BH. The long-range prognosis of arachnoiditis. *Spine (Phila Pa 1976)* 1989;14:1332-41.
  14. Hui AC, Chan YL, Kay R. Syrinx and tuberculoma formation in tuberculous arachnoiditis. *Can J Neurol Sci* 2001;28:148-9.
  15. Jesrani G, Kaur J, Gupta M, Sawal N. Syringomyelia as a delayed complication of lumbar-sacral adhesive arachnoiditis in Pott's disease. *BMJ Case Rep CP* 2020;13:e234032.
  16. Kalina J. Arachnoiditis. *J Pain Palliat Care Pharmacother* 2012;26:176-7.
  17. Kannapadi NV, Alomari SO, Caturegli G, Bydon A, Cho SM. Management of syringomyelia associated with tuberculous meningitis: A case report and systematic review of the literature. *J Clin Neurosci* 2021;87:20-5.
  18. Kaynar MY, Koçer N, Gençosmanoğlu BE, Hanci M. Syringomyelia as a late complication of tuberculous meningitis. *Acta Neurochir (Wien)* 2000;142:935-8.
  19. Klekamp J, Batzdorf U, Samii M, Bothe HW. Treatment of syringomyelia associated with arachnoid scarring caused by arachnoiditis or trauma. *J Neurosurg* 1997;86:233-40.
  20. Klekamp J, Iaconetta G, Batzdorf U, Samii M. Syringomyelia associated with foramen magnum arachnoiditis. *J Neurosurg* 2002;97:317-22.
  21. Morisako H, Takami T, Yamagata T, Chokyu I, Tsuyuguchi N, Ohata K. Focal adhesive arachnoiditis of the spinal cord: Imaging diagnosis and surgical resolution. *J Craniovertebr Junction Spine* 2010;1:100-6.
  22. Naito K, Yamagata T, Ohata K, Takami T. Safety and efficacy of syringoperitoneal shunting with a programmable shunt valve for syringomyelia associated with extensive spinal adhesive arachnoiditis: Technical note. *World Neurosurg* 2019;132:14-20.
  23. Nardone R, Alessandrini F, Tezzon F. Syringomyelia following *Listeria* meningoencephalitis: Report of a case. *Neurol Sci* 2003;24:40-3.
  24. Nash TE, O'Connell EM. Subarachnoid neurocysticercosis: Emerging concepts and treatment. *Curr Opin Infect Dis* 2020;33:339-46.
  25. Panackal AA, Komori M, Kosa P, Khan O, Hammoud DA, Rosen LB, et al. Spinal arachnoiditis as a complication of cryptococcal meningoencephalitis in Non-HIV previously healthy adults. *Clin Infect Dis* 2017;64:275-83.
  26. Phanthumchinda K, Kaoropthum S. Syringomyelia associated with post-meningitic spinal arachnoiditis due to *Candida tropicalis*. *Postgrad Med J* 1991;67:767-9.
  27. Rangel-Castilla L, Hwang SW, White AC, Zhang YJ. Neuroendoscopic diagnosis of central nervous system histoplasmosis with basilar arachnoiditis. *World Neurosurg* 2012;77:399.E9-13.
  28. Rodriguez ED. Central nervous system tuberculosis following delayed and initially missed lung miliary tuberculosis: A case report. *Infez Med* 2018;26:270-5.
  29. Snyder P. Chiari malformation and syringomyelia. *Radiol Technol* 2008;79:555-8.
  30. Todeschi J, Chibbaro S, Gubian A, Pop R, Proust F, Cebula H. Spinal adhesive arachnoiditis following the rupture of an Adamkiewicz aneurysm: Literature review and a case illustration. *Neurochirurgie* 2018;64:177-82.
  31. Tsitouras V, Sgouros S. Syringomyelia and tethered cord in children. *Childs Nerv Syst* 2013;29:1625-34.
  32. Turnbull IM, Shulman R, Woodhurst WB. Thalamic stimulation for neuropathic pain. *J Neurosurg* 1980;52:486-93.
  33. Wright MH, Denney LC. A comprehensive review of spinal arachnoiditis. *Orthop Nurs* 2003;22:215-9.
  34. Zuev AA, Lebedev VB, Pedyash NV, Epifanov DS, Levin RS. Treatment of syringomyelia associated with adhesive arachnoiditis. *Zh Vopr Neurokhir Im N N Burdenko* 2017;81:39-47.

**How to cite this article:** Nadeem SF, Baig AN, Tariq Q, Shamim MS. Spinal arachnoiditis and syringomyelia: Review of literature with emphasis on postinfectious inflammation and treatment. *Surg Neurol Int* 2022;13:299.