

Case Reports

Myoclonus in Ataxia–Telangiectasia

Pichet Termsarasab^{1*}, Amy C. Yang² & Steven J. Frucht¹

¹ Movement Disorder Division, Department of Neurology, Icahn School of Medicine at Mount Sinai, New York, NY, USA, ² Department of Genetics and Genomic Sciences, Icahn School of Medicine at Mount Sinai, New York, NY, USA

Abstract

Background: Various movement disorders can be found in ataxia–telangiectasia (AT), including ataxia, dystonia, chorea, and myoclonus, but myoclonus has rarely been described as the predominant feature in AT.

Case Report: We report two AT patients with prominent myoclonus, illustrating an unusual presentation of this disorder. Sequencing of the *ATM* gene in the first patient revealed a homozygous truncating mutation, c.5908C>T (p.Q1970*) in exon 38 of the *ATM* gene, which has been previously reported as a founder mutation in the Costa Rican population.

Discussion: Myoclonus can be a predominant or presenting feature in AT, even without dystonia.

Keywords: Ataxia, myoclonus, telangiectasia, founder mutation

Citation: Termsarasab P, Yang AC, Frucht SJ. Myoclonus in ataxia–telangiectasia. *Tremor Other Hyperkinet Mov.* 2015; 5. doi: 10.7916/D88P5Z9X

*To whom correspondence should be addressed. E-mail: Pichet.Termsarasab@mountsinai.org

Editor: Elan D. Louis, Yale University, USA

Received: January 2, 2015 **Accepted:** February 3, 2015 **Published:** March 13, 2015

Copyright: © 2015 Termsarasab et al. This is an open-access article distributed under the terms of the Creative Commons Attribution–Noncommercial–No Derivatives License, which permits the user to copy, distribute, and transmit the work provided that the original author(s) and source are credited; that no commercial use is made of the work; and that the work is not altered or transformed.

Funding: None.

Financial disclosures: None.

Conflict of interest: The authors report no conflict of interest.

Introduction

Ataxia–telangiectasia (AT) is an autosomal recessive deoxy-ribonucleic acid (DNA) repair disorder. Typical clinical features include ataxia, usually as an early feature, oculomotor apraxia, telangiectasia, immunodeficiency, and increased risk of malignancies such as leukemia and lymphoma. Although they constitute the name of this disorder, ataxia and telangiectasias are not always the main or presenting clinical features. In most cases, ataxia occurs early around age 2–4 years.¹ Telangiectasias are usually detected several years after the onset of ataxia, but they may be absent.¹

The phenomenology of movement disorders seen in AT is broad, including ataxia, tremor, chorea, dystonia, and myoclonus. In some cases, dystonia is more prominent than ataxia. Myoclonus is found in about 25% of AT patients¹ and is often accompanied by dystonia;² predominant myoclonus is uncommon. Here we report two patients with myoclonus as a predominant feature of AT, and illustrate the unusual nature of this presentation.

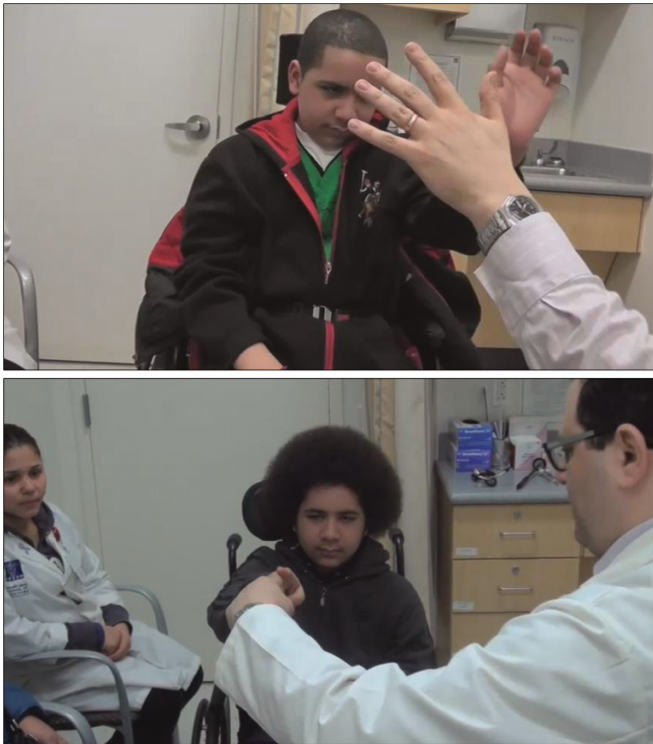
Written informed consent was obtained from the patients for publication of this case report and any accompanying videos.

Case report

Patient 1

A Dominican boy presented to our clinic at age 11 (in March 2013), with a 6-year history of progressive imbalance. Myoclonus of his arms limited his ability to use his hand to reach or transfer objects, such as holding utensils or feed himself. On examination, he was wheelchair-bound, with marked oculomotor apraxia for both vertical and horizontal eye movements. Head thrusts were required to generate saccades, and there was a marked delay of saccade initiation and saccadic hypometria. There were prominent scleral conjunctival vessels, but no overt telangiectasias in any body regions. Frequent, irregular myoclonic jerks of his head, trunk, and arms were present, which became worse with action. It was difficult to evaluate stimulus sensitivity of myoclonus because of the frequency of the jerks. There was marked appendicular and limb ataxia, but no dystonia. Hypotonia in his trunk and extremities was accompanied by decreased reflexes (Video 1).

Family history was negative, and included an older sister and a younger brother. There was no history of consanguinity. Laboratory investigations revealed a markedly elevated alpha-fetoprotein level



Videos: **Video 1.** Examination of the First Patient before the Initiation of Levetiracetam Revealed Frequent Myoclonic Jerks of the Neck and Trunk at Rest. Ocular telangiectasia was not present. There were occasional square wave jerks. Oculomotor apraxia was demonstrated, with marked delay of saccade initiation. Once he generated saccades, they were hypometric, and saccadic velocities were slow. Pursuits were relatively preserved compared with saccades. Horizontal and vertical optokinetic nystagmus was reduced. Myoclonus of bilateral upper extremities was more prominent with action, such as when he held his arms up or moved his hand to the target. **Video 2.** Examination of the First Patient 9 Months after the Examination in Video 1, when the Patient was on Levetiracetam 1,000 mg/day. Neck and truncal myoclonus was mildly improved. There were less axial myoclonic jerks at rest. Myoclonus of the neck was more prominent when he tried to perform tasks such as attempting to move his eyes during the examination. Oculomotor apraxia and other ocular motility examinations had not significantly changed since the examination in Video 1. Myoclonus remained more prominent with action than at rest, but action myoclonus when holding his arms up or moving his arms had slightly improved since the examination in Video 1. The finger-following test demonstrated not only action myoclonus, but also symmetric overshoot dysmetria.

(AFP 624; normal 0–9 ng/ml), and reduced immunoglobulin (Ig)A level. Given the elevated AFP and oculomotor apraxia, the differential diagnosis was narrowed down to AT and ataxia with oculomotor apraxia (AOA) type 2. A routine karyotype was normal without evidence of translocations. Array comparative genomic hybridization was normal. Sequencing of the *ATM* gene revealed a homozygous truncating mutation, c.5908C>T (p.Q1970*) in exon 38 of the *ATM* gene, which has been previously reported as a founder mutation in the Costa Rican population.³

He was treated with levetiracetam 1,000 mg/day (Video 2) with mild improvement in myoclonus. The dose was then increased to 1,500 mg/day with moderate improvement in myoclonus, hand

function, and activities of daily living. Abdominal ultrasound did not reveal evidence of malignancy.

Patient 2

A 12-year-old boy presented for evaluation of jerking movements. He was first noticed to have hypotonia and unsteadiness when he started to walk at age 18 months. When he was 2.5 years old, his 17-month-old brother was noted to have unsteady walking also. AFP at age 3 years was elevated to 29 ng/ml. He and his brother were confirmed to have AT by increased X-ray DNA breakage analysis (2.52 chromosomal abnormalities in the patient; normal 0.08–0.36); *ATM* gene analysis was not performed. The patient had a documented IgA deficiency with low humoral response noted in repeated vaccinations; however, there were no recurrent infections.

On examination at age 12 (in March 2010), there was prominent multifocal myoclonus in the limbs and trunk, during both action and at rest. There was no dystonia. Ocular motor examination revealed slowing of saccades. There were no telangiectasias. Deep tendon reflexes were slightly decreased throughout. Toes were downgoing bilaterally. Appendicular ataxia was prominent, without truncal ataxia. A video of this patient is not available.

Discussion

We report two patients with AT in whom myoclonus was the predominant movement disorder. Both patients had prominent axial and appendicular myoclonic jerks. The differential diagnosis of ataxia with oculomotor apraxia, as seen in the first patient, includes AT, AOA1, AOA2, AT-like disorder due to *MRE11* mutation,⁴ and spinocerebellar ataxia with neuropathy type 1 (SCAN1) due to *TDPI* mutation. The elevation of AFP narrowed the differential diagnosis, and testing confirmed the diagnosis of AT.

DNA breakage due to radiosensitivity can be seen not only in AT but also in various other DNA repair disorders such as Nijmegen breakage syndrome, Fanconi anemia, and AT-like disorder due to *MRE11* gene mutations. However, the first two do not have ocular motor abnormalities, cerebellar ataxia, or neuropathy. Progressive myoclonic ataxia has recently been reported in AT-like disorder due to *MRE11* mutations,⁴ but movement disorders have never been reported in the first two. In *MRE11*-related AT-like disorder, reduced immunoglobulin levels and elevated AFP are generally not seen.⁵

We reviewed the literature of AT patients with myoclonus (Table 1). Most patients reported previously had both myoclonus and dystonia. Myoclonus without dystonia as in our patients is much less common. In previously reported cases, myoclonus involved mainly head or neck and upper limbs, whereas myoclonus in our patients involved neck, trunk and all extremities. Although two patients previously reported by Cummins et al.⁶ and Nakayama et al.⁷ were noted to have truncal extensor dystonia, the phenomenology of the truncal jerking in our patients is clearly myoclonus.

There has been evidence in the literature suggesting the contribution of the cerebellum in myoclonus. In AT, the pathological hallmark is loss of cerebellar Purkinje and granule cells that leads to cerebellar

Table 1. Review of Literature of Ataxia–Telangiectasia Cases with Myoclonus

Authors	Year Published	Number of Patients	Age Patient(s) Developed Myoclonus (years)	Phenomenology	Body Regions Involved
Saunders-Pullman et al. ¹⁴	2012	8 (from 3 families; 3, 1, 4 from each)	Unknown	Myoclonus/jerky dystonia	Neck in 6 patients, arm(s) in 4, lower face in 2, upper face in 1
Shaikh et al. ¹⁵	2013	Unknown	Unknown	All (80 patients) had non-rhythmic adventitious movements on accelerometer, classified into slow and fast movements. The fast movements were “similar to myoclonus or dystonic jerks”, but the number of the patients in this subgroup was not reported	Upper limb
Cummins et al. ⁶	2013	1	46	Myoclonus and dystonia	Head (myoclonus), truncal extensor muscles (dystonia)
Mèneret et al. ²	2014	12 (out of 14 patients)	Unknown	Myoclonus with dystonia in 10 patients; multifocal myoclonus without dystonia in 2	Neck, trunk, upper limbs
Nakayama et al. ⁷	2014	1	8	Myoclonic/dystonic jerks	Neck and truncal extensor muscles
Current cases	2014	2	11 and 12	Myoclonus	One in neck, face, trunk and extremities; the other in the limbs and trunk

The authors, years the cases were published, number of the patients with myoclonus, the phenomenology described in the literature (note that some also described dystonia), and the body regions involved are shown in each column.

atrophy and degeneration.⁸ We suggest the possibility that the same pathological process in the cerebellum leads to myoclonus in AT. Although electrophysiologic testing was not available in our patients, and we were unable to determine clear stimulus sensitivity because of the frequency of the jerks, a cortical origin of the myoclonic jerks was suspected. Prominent action myoclonus with involvement of the distal limbs and the response to levetiracetam in the first patient suggests the possibility of cortical origin. Cerebellar pathology is also known to be associated with cortical myoclonus in celiac disease⁹ and familial cortical myoclonic tremor with epilepsy.^{10–12} Thus circuitry or networks that link the cerebellum to the cerebral cortex may give rise to myoclonic jerks.

A Costa Rican founder mutation was found in Patient 1, who is actually of Dominican descent. Although there are no mutation hot spots in the *ATM* gene, founder mutations have been reported in several ethnic populations including African American, Costa Rican, Iranian, Italian, Japanese, Polish, and Turkish, among others (but not in Dominican). Six Costa Rican founder mutations include c.5908C>T (p.Q1970*), IVS63del17kb, c.7449G>A (p.W2483*), c.4507C>T (p.Q1503*), c.8264_8268del5 (p.Y2755Cfs*12), and c.1120C>T (p.Q374*) with c.5908C>T (p.Q1970*) being the most prevalent.^{3,13} There are no clear genotype-phenotype correlations for most mutations except for c.7271T>G, c.8147T>C, and c.8494C>T, which are associated with

milder phenotypes.¹³ With only one patient, we cannot draw an association between this founder mutation and the myoclonic phenotype.

The prevalence of myoclonus, especially myoclonus without dystonia, has not been studied systematically in AT. When clinicians encounter AT patients with myoclonus along with dystonia, the diagnosis may be less challenging than when patients present with predominant myoclonus, as in our cases. Recognition of this particular phenotype, along with other clues on examination and laboratory testing, can guide clinicians to the correct diagnosis.

In conclusion, myoclonus can be a predominant or presenting feature in AT, even without dystonia. It is crucial to recognize this uncommon phenotype, as patients will need surveillance of immunodeficiency and malignancies, as well as measures to lessen accumulating DNA damage from radiologic exposure and chemotherapeutic agents.

References

1. Perlman SL, Boder E, Sedgewick RP, Gatti RA. Ataxia-telangiectasia. *Handb Clin Neurol* 2012;103:307–332, doi: <http://dx.doi.org/10.1016/B978-0-444-51892-7.00019-X>
2. Meneret A, Ahmar-Beaugendre Y, Rieunier G, et al. The pleiotropic movement disorders phenotype of adult ataxia-telangiectasia. *Neurology* 2014;83:1087–1095, doi: <http://dx.doi.org/10.1212/WNL.0000000000000794>.
3. Telatar M, Wang S, Castellvi-Bel S, et al. A model for ATM heterozygote identification in a large population: Four founder-effect ATM mutations identify most of Costa Rican patients with ataxia telangiectasia. *Mol Genet Metab* 1998;64:36–43, doi: <http://dx.doi.org/10.1006/mgme.1998.2693>.
4. Miyamoto R, Morino H, Yoshizawa A, et al. Exome sequencing reveals a novel MRE11 mutation in a patient with progressive myoclonic ataxia. *J Neurol Sci* 2014;337:219–223, doi: <http://dx.doi.org/10.1016/j.jns.2013.11.032>.
5. Fernet M, Gribaa M, Salih MA, Seidahmed MZ, Hall J, Koenig M. Identification and functional consequences of a novel MRE11 mutation affecting 10 Saudi Arabian patients with the ataxia telangiectasia-like disorder. *Hum Mol Genet* 2005;14:307–318, doi: <http://dx.doi.org/10.1093/hmg/ddi027>.
6. Cummins G, Jawad T, Taylor M, Lynch T. Myoclonic head jerks and extensor axial dystonia in the variant form of ataxia telangiectasia. *Parkinsonism Relat Disord* 2013;19:1173–1174, doi: <http://dx.doi.org/10.1016/j.parkreidis.2013.08.013>.
7. Nakayama T, Sato Y, Uematsu M, et al. Myoclonic axial jerks for diagnosing atypical evolution of ataxia telangiectasia. *Brain Dev* 2014.
8. Verhagen MM, Martin JJ, van Deuren M, et al. Neuropathology in classical and variant ataxia-telangiectasia. *Neuropathology* 2012;32:234–244, doi: <http://dx.doi.org/10.1111/j.1440-1789.2011.01263.x>.
9. Bhatia KP, Brown P, Gregory R, et al. Progressive myoclonic ataxia associated with coeliac disease. The myoclonus is of cortical origin, but the pathology is in the cerebellum. *Brain* 1995;118(Pt 5):1087–1093, doi: <http://dx.doi.org/10.1093/brain/118.5.1087>.
10. Tijssen MA, Thom M, Ellison DW, et al. Cortical myoclonus and cerebellar pathology. *Neurology* 2000;54:1350–1356, doi: <http://dx.doi.org/10.1212/WNL.54.6.1350>.
11. Striano P, Caranci F, Di Benedetto R, Tortora F, Zara F, Striano S. (1)H-MR spectroscopy indicates prominent cerebellar dysfunction in benign adult familial myoclonic epilepsy. *Epilepsia* 2009;50:1491–1497, doi: <http://dx.doi.org/10.1111/j.1528-1167.2008.01900.x>.
12. Buijink AW, Caan MW, Tijssen MA, Hoogduin JM, Maurits NM, van Rootselaar AF. Decreased cerebellar fiber density in cortical myoclonic tremor but not in essential tremor. *Cerebellum* 2013;12:199–204, doi: <http://dx.doi.org/10.1007/s12311-012-0414-2>.
13. Gatti R. Ataxia-telangiectasia. In Pagon R, Adam M, Ardinger H, et al., editors. GeneReviews®. Seattle, WA: University of Washington; 1999 (updated 2010 Mar 11), doi: <http://www.ncbi.nlm.nih.gov/books/NBK26468/>.
14. Saunders-Pullman R, Raymond D, Stoessel AJ, et al. Variant ataxia-telangiectasia presenting as primary-appearing dystonia in Canadian Mennonites. *Neurology* 2012;78:649–657, doi: <http://dx.doi.org/10.1212/WNL.0b013e3182494d51>.
15. Shaikh AG, Zee DS, Mandir AS, Lederman HM, Crawford TO. Disorders of Upper Limb Movements in Ataxia-Telangiectasia. *PLoS One* 2013; 8:e67042, doi: <http://dx.doi.org/10.1371/journal.pone.0067042>.