

Available online at www.sciencedirect.com

ScienceDirect

Biomedical Journal

journal homepage: www.elsevier.com/locate/bj

Original Article

Cone-beam computed tomography assessment of Schneiderian membranes: Non-infected and infected membranes, and membrane resolution following tooth extraction: A retrospective clinical trial



Yuh-Hau Hsu ^a, Whei-Lin Pan ^{a,b,*}, Chiu-Po Chan ^{a,b}, Yi-Ping Pan ^c,
Cho-Ying Lin ^a, Yuan-Min Wang ^a, Chi-Ching Chang ^a

^a Department of Periodontics, Chang Gung Memorial Hospital at Taipei, Taipei, Taiwan

^b Graduate Institute of Dental and Craniofacial Science, Chang Gung University, Taoyuan, Taiwan

^c Department of Nutrition, Chang Gung Memorial Hospital at Keelung, Keelung, Taiwan

ARTICLE INFO

Article history:

Received 27 August 2018

Accepted 27 March 2019

Available online 7 November 2019

Keywords:

Lateral wall thickness

Maxillary sinus

Membrane thickness

Residual bone height

Schneiderian membrane

ABSTRACT

Background: Cone-beam computed tomography (CBCT) presurgical assessment on the maxillary sinus can reduce the possibility of Schneiderian membrane perforation. This study examined Schneiderian membrane thickness (SMT) and its relationship with neighboring hard tissues for patients with and without membrane thickening. For patients with sinus infections, we evaluated dimensional changes of the SMT post-extraction relative to pre-extraction SMT and residual bone height (RBH).

Methods: CBCT images from 93 patients needing single-tooth implant reconstruction without ($n = 83$) and with ($n = 14$) odontogenic infected maxillary sinuses were assessed. SMT, RBH, and lateral wall thickness (LWT) were measured. Causes of extraction, RBH in the infection site, and retrospective post-extraction record of SMT were recorded for the thickened SMT group.

Results: Mean SMT for normal SMT group was 1.13 ± 0.43 mm, RBH was 6.26 ± 2.38 mm; upper and lower LWT was 1.85 ± 0.95 mm, and 3.07 ± 2.26 mm, respectively. RBH and LWT had no significant relationships with SMT. For thickened SMT group, mean values for SMT and RBH prior to extraction were 4.53 ± 2.46 mm and 1.97 ± 1.43 mm, respectively. Pre-extraction SMT had a moderately negative correlation with pre-extraction RBH. SMT resolution in thickened SMT group was observed by 2.80 ± 1.37 months post-extraction; post-extraction SMT was not significantly different from normal SMT group ($p = .187$).

Conclusions: Within the limitation of the sample size, thickened SMT induced by odontogenic infection subsides about 3 months following tooth extraction, and further sinus lifting implant surgery may be considered.

* Corresponding author. Department of Periodontics, Chang Gung Memorial Hospital at Taipei, 199, Dun Hwa North Rd., Taipei 10507, Taiwan.

E-mail address: haopan@cloud.cgmh.org.tw (W.-L. Pan).

Peer review under responsibility of Chang Gung University.

<https://doi.org/10.1016/j.bj.2019.03.001>

2319-4170/© 2019 Chang Gung University. Publishing services by Elsevier B.V. This is an open access article under the CC BY-NC-ND license (<http://creativecommons.org/licenses/by-nc-nd/4.0/>).

At a glance of commentary

Scientific background on the subject

Odontogenic infection in posterior maxillae may cause Schneiderian membrane thickening. Though controversial, thickened Schneiderian membrane relates to higher risk of membrane perforation in sinus lifting surgery. We use cone-beam computed tomography to observe the structural changes of Schneiderian membrane thickness (SMT) before and after tooth extraction.

What this study adds to the field

Thickened SMT caused by odontogenic infection subsides after tooth extraction. Regardless of the SMT before tooth extraction, sinus lifting implant surgery maybe considered in about 3 months after removal of dental infection source.

Tooth extraction in the posterior maxillary region may cause atrophy of the alveolar ridge and pneumatization of the maxillary sinus, resulting in difficulties in implant rehabilitation [1]. First introduced by Tatum in 1980, sinus floor elevation has become an important treatment in implant placement [2,3]. For insufficient residual bone height (RBH), either the lateral wall technique or the osteotome technique is used [4]. A major surgical complication during sinus lifting procedures is Schneiderian membrane perforation [5], which increases the risk of grafted sinus infection [6]. The Schneiderian membrane is composed of pseudostratified ciliated columnar epithelium, connective tissue, and periosteum, and maintains the health and drainage of the maxillary sinus [7]. Maintaining Schneiderian membrane integrity is often considered to lead to a more favorable clinical outcome in sinus lifting surgery, possibly relating to its osteogenic potential [8].

Although several anatomical factors can influence sinus membrane perforation during sinus floor elevation, including sinus septa [9] and RBH [10], Schneiderian membrane thickness (SMT) is also an important factor [11]. SMT can be determined both histologically and radiographically; in healthy populations, the average SMT is less than 2 mm radiographically [11]. An SMT greater than 2 mm is an indication of mucosal thickening [12,13]. Causes of sinus membrane thickening can be dental, such as periodontal or endodontic lesions, or ear–nose–throat-related, such as allergic sinusitis or cystic lesions; the incidence of dental-related sinusitis is 10%–12% [13]. In advanced periodontitis and endodontic infections, the closer the inflammation is to the sinus, the greater the chance for sinus thickening [13]. Advanced periodontitis may cause swelling of the maxillary sinus membrane and periodontal therapy significantly reduces its swelling [14].

To avoid Schneiderian membrane perforation, precise presurgical radiographic assessment is paramount. Cone-beam computed tomography (CBCT) is a widely used and

reliable procedure for characterizing conditions in the maxillary sinus [15,16]. Low-dose CBCT offers more accurate images than 2-dimensional panoramic radiography, which is unclear and can often obscure odontogenic sinusitis [17]. In addition, in sinus lifting surgery, the choice of a crestal approach or lateral window technique depends on the RBH and SMT to avoid perforation of Schneiderian membrane. Therefore, success of sinus lifting surgery for patients with odontogenic sinus membrane thickening requires precise assessment of the relationship between the mucous membrane and surrounding hard tissue, including RBH and LWT. However, few longitudinal studies have assessed the changes in these variables from the time of tooth extraction to the time required for soft-tissue healing. The objectives of the present study were to (1) investigate the relationship between the thickness of the sinus membrane and the surrounding hard tissues in a group of single missing teeth which had no thickening of sinus membrane, and (2) examine changes of SMT before and after extraction in persons with odontogenic sinus infections and determine recovery time post-extraction for the SMT and RBH. We hypothesize that thickened SMT related to odontogenic infection subsides after extracting these infected hopeless teeth.

Methods

Patients and images

Cone-beam computed tomography (CBCT) images of patients were obtained from the department of periodontics at a hospital in northern Taiwan. Patients met the following inclusion criteria: (1) age \geq 18 years and of Taiwanese ethnicity, (2) availability of maxillary CBCT scans for diagnostic assessment of a dental implant following tooth extraction necessitated by a root fracture or other endodontic procedure, or dental inflammation, and (3) nonsmoking status. Patients were divided into two groups: normal SMT, defined by patients with no maxillary sinus infection, and thickened SMT, defined by patients with a poor/hopeless prognosis due to a tooth extraction history of periodontal origin [18], extensive peri-apical lesions, non-restorable dental caries, and vertical root fracture [7].

Patients' CBCT images were taken between January 2010 and November 2017 and met the following inclusion criteria: (1) the image was distinct; (2) the maxillary sinus to be measured was visible from its floor to 15 mm from the alveolar crest of the edentulous ridge; 15 mm is where the lateral window augmentation usually ends [19]; (3) RBH less than 10 mm, and for normal SMT group, (4) only one single missing tooth—either the second premolar, the first molar, or the second molar. Images were excluded if they met the following criteria: (1) the patient had a history of orthodontic treatment, (2) ridge preservation procedure or any other surgical interventions following tooth extraction, (3) or sinus surgery, (4) the edentulous area could not be determined, and for thickened SMT group (5) the reason for extraction was unknown, or (6) without odontogenic infection. Images from the normal SMT group contained SMTs of less than 2 mm, and no sinus pathologies present. Images

from the thickened SMT group showed SMTs of 2 mm or more before extraction. For the thickened SMT group, a second set of CBCT images was generated in the first recall post-extraction after soft tissue healing [20] recovered adequately to commence implant evaluation. Thickened SMT group received regular implant follow-up every four to six months.

Image acquisition

All included CBCT images were acquired using the ISI Cone Beam 3D Dental Imaging System (USA) with a standardized protocol. The acquisition parameters were as follows: slice thickness, 0.25 mm; pixel size, 0.25 mm; tube voltage, 120 kVp; tube current, 36.12 mA/s; and acquisition period, 40 s. Reformatted cross-sectional images were obtained using the dental CT software SIMPLANT® 16 (Dentsply, USA) and presented as real-size images through a thin-film transistor monitor with a resolution of 1600 × 1200.

Measurements to determine SMT

Cross-sectional CBCT images of the center of the implant site [Fig. 1, left] and the maxillary sinus [Fig. 1, right] were obtained for normal SMT group prior to implantation surgery. Measurements for thickened SMT group were obtained from CBCT images pre- and post-extraction [Fig. 2]. Measurements of SMT and surrounding tissues were obtained from the maxillary sinus; all data were measured in terms of SMT, RBH, and LWT. A reference line was drawn on the image from the top of the alveolar crest to the sinus floor in order to determine the value for the RBH. SMT was measured from the lowest point of the sinus floor. Measurements of the upper and lower border of the lateral wall thickness (LWT), which corresponded to the upper and lower border of the lateral window, were obtained at 15 mm (LWT15) and 3 mm (LWT3) from the level of the alveolar

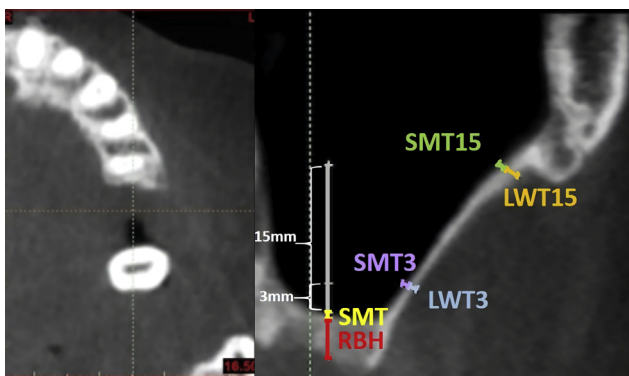


Fig 1 Representative image of an axial cross-sectional cone-beam computed tomography (CBCT) scan used to examine normal SMT and thickened SMT group. Left image shows the absence of a maxillary molar. Right image shows the maxillary sinus and landmarks used for measurements: the center line is for reference (the top of the alveolar crest to the sinus floor); RBH (red), SMT (yellow), LWT3 at 3 mm from sinus floor (light blue), SMT3 at 3 mm from sinus floor (Purple), LWT15 at 15 mm from sinus floor (orange), SMT15 at 15 mm from sinus floor (green).

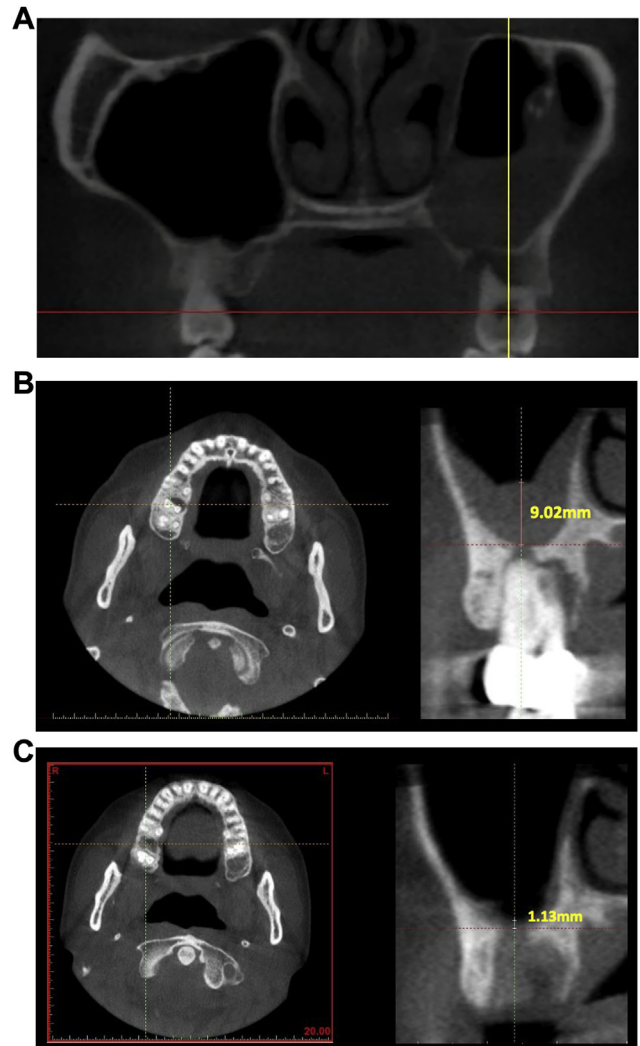


Fig. 2 Representative images of cross-sectional cone-beam computed tomography (CBCT) scans from patients with thickened SMT for a single-tooth implant reconstruction in the posterior maxilla pre- and post-extraction. (A) Pre-extraction maxillary sinus with odontogenic infection, showing thickened SMT; (B) Pre-extraction of maxillary second molar for root fracture. Left: Maxillary second molar. Right: Sinus floor perforation and thickened sinus membrane (SMT = 9.02 mm); (C) 4 months post-extraction of maxillary second molar for root fracture. Left: Maxillary second molar area. Right: Subsided sinus membrane (SMT = 1.13 mm).

crest [Fig. 1]. These represent the highest and lowest levels of the osseous window when a lateral approach is used for sinus augmentation. Mucosal thickness perpendicular to the underlying bone was measured at SMT3 (membrane thickness at lowest point of the lateral window, 3 mm) and SMT15 (membrane thickness at highest point of the lateral window, 15 mm).

Statistical analysis

Spearman correlation coefficients were calculated to examine the relationships between SMT and RBH, SMT and

LWT. For images from patients with thickened SMT sinuses calculations were determined between SMT pre-extraction and the average time for recovery of the SMT. The Mann–Whitney *U* test was used to compare SMT between the normal SMT group and the first visit post-extraction of the thickened SMT group, as well as the longitudinal change in SMT in the thickened SMT post-extraction. The significance level for all statistical tests was set at $p \leq .05$. Analyses were performed using the SPSS software package (IBM SPSS Statistics 17.0.1, Armonk, NY, USA) and Excel (Microsoft Excel 2008, Seattle, WA, USA).

Results

Normal SMT group

Demographic and clinical characteristics of the normal SMT group ($n = 83$) are shown in [Table 1]. The mean age was 56.39 ± 11.01 years (range 28–81) and there were 39 males and 44 females. All had received CBCT evaluations for single-tooth implant reconstruction in the posterior maxilla. The tooth extraction for these patients had been performed in other clinics, therefore we had no clinical information regarding the reason for extraction.

Radiographic analysis was available from 94 maxillary sinuses for measurements of SMT and surrounding hard tissues [Table 2]. Studying CBCT images resulted in mean measurements of 1.13 ± 0.43 mm for the SMT; measures for SMT3 and SMT15 were 0.93 ± 0.64 mm and 0.75 ± 0.45 mm, respectively. The mean RBH was 6.26 ± 2.38 . Lower and upper LWT varied with maxillary tooth region; at LWT3, the second premolar area had the greatest thickness (2.42 ± 1.42 mm), for LWT15 the first molar region was greatest (4.19 ± 2.51 mm).

Spearman correlation analysis of SMT and surrounding hard tissue demonstrated a significant, but weak, positive correlation between the SMT and RBH ($p = .04$, $r_s = 0.213$). There were also significant, but weak, positive correlations for

Table 2 Mean measurements (mm) from CBCT images of maxillary sinuses ($n = 94$) of normal SMT group ($n = 83$) pre-implantation.

Area (mm)	Mean (SD)	Range (Max/Min)
SMT	1.13 ± 0.43	1.91/0.47
P2	1.02 ± 0.23	
M1	1.11 ± 0.43	
M2	1.19 ± 0.45	
RBH	6.26 ± 2.38	9.45/0.86
P2	6.31 ± 2.17	
M1	6.28 ± 2.49	
M2	6.22 ± 2.24	
LWT3	1.85 ± 0.95	5.65/0.60
P2	2.42 ± 1.42	
M1	1.96 ± 0.96	
M2	1.96 ± 0.96	
LWT15	3.07 ± 2.26	11.03/0.05
P2	2.47 ± 1.18	
M1	4.19 ± 2.51	
M2	2.08 ± 1.54	
SMT3	0.93 ± 0.64	4.97/0.29
P2	0.82 ± 0.25	
M1	0.88 ± 0.52	
M2	1.01 ± 0.79	
SMT15	0.75 ± 0.45	3.18/0.30
P2	0.97 ± 0.29	
M1	0.74 ± 0.28	
M2	0.72 ± 0.59	

Abbreviations: CBCT: cone beam computed tomography; RBH: residual bone height; SMT: Schneiderian membrane thickness; SMT3 and SMT15: Schneiderian membrane thickness at 3 mm and 15 mm, respectively; LWT3 and LWT15: lateral wall thickness at 3 mm and 15 mm, respectively; P2: second premolar; M1: first molar; M2: second molar.

the SMT3 and LWT3 ($p = .019$, $r_s = 0.242$) and the SMT15 and LWT15 ($p = .007$, $r_s = 0.277$).

Thickened SMT group

Demographic and clinical characteristics of the thickened SMT group ($n = 14$) are shown in [Table 1]. The mean age was 54.29 ± 9.26 years (range, 39–70) and there were 8 males and 6 females. The maxillary sinuses ($n = 14$) and infected teeth of the 14 patients had been radiographically analyzed. The reasons for extraction were advanced periodontitis ($n = 6$), root fracture ($n = 7$), and a retained root with apical lesion ($n = 1$).

[Table 3] shows mean measures for the SMT and surrounding hard tissue pre-extraction of bilateral sinuses, and measures of the SMT post-extraction of the SMT thickened sinus. The Mann–Whitney *U* test indicated the measurement of SMT3 between thickened and normal SMT groups showed significant difference (*Z* score = -4.19362 , $p < .00001$), and there was no significant difference between thickened and normal SMT groups regarding SMT15 (*Z* score = 0.494 , $p = .624$). Accordingly, SMT thickening induced by dental infection may extend to the lower border of lateral window.

The time between extraction and the first recall evaluation was 3–6 months; at least 2.80 ± 1.37 months were required for the thickened pre-extraction SMT to subside. Spearman correlation showed no significant relationship between pre-

Table 1 Demographics and clinical characteristics of patients requiring tooth implants ($N = 93$).

Characteristic	Patients	
	Normal SMT ($n = 83$)	Thickened SMT ($n = 14$)
Age (year); mean \pm SD (range)	56.39 ± 11.01 (28–81)	54.29 ± 9.26 (39–70)
Gender (n)		
Male	39	8
Female	44	6
Reason for extraction		
Advanced periodontitis	NA	6
Root fracture	NA	7
Retained tooth with apical lesion	NA	1
Number of sinuses measured (n)	94	14

Abbreviation: SD: standard deviation.

Table 3 Mean measurements (mm) from CBCT images of SMT and surrounding hard tissue of maxillary sinuses (n = 14) of thickened SMT group (n = 14) pre-extraction and for SMT at first recall post-extraction, and mean time of first recall.

Area	Pre-extraction				Post-extraction	
	SMT thickened side		Collateral arch		Mean (SD)	Range (Max/Min)
	Mean (SD)	Range (Max/Min)	Mean (SD)	Range (Max/Min)		
SMT	4.53 ± 2.46	9.23/2.14	1.24 ± 0.36	1.64/0.56	1.25 ± 0.29	1.77/0.81
RBH	1.97 ± 1.43 ^a	4.64/0				
LWT3	3.07 ± 0.09	4.50/1.03	2.51 ± 1.22	4.37/0.90		
LWT15	3.02 ± 0.96	11.54/0.79	3.93 ± 1.93	7.08/1.27		
SMT3	3.07 ± 0.96	4.50/1.03	0.86 ± 0.24	1.35/0.56		
SMT15	0.64 ± 1.64	6.62/0.25	0.70 ± 0.40	1.60/0.25		

Abbreviations: SD: standard deviation; CBCT: cone beam computed tomography; RBH: residual bone height; SMT: Schneiderian membrane thickness; SMT3 and SMT15: Schneiderian membrane thickness at 3 mm and 15 mm, respectively; LWT3 and LWT15: lateral wall thickness at 3 mm and 15 mm, respectively.

^a Measured at site of infection.

extraction measures of SMT or the RBH at the infected site and time required for the sinus membrane to recover (SMT, $p = .735$, $r_s = 0.099$; RBH, $p = .471$, $r_s = -0.210$). However, there was a significant and moderately negative correlation between the pre-extraction SMT and the RBH at the infection site ($p = .023$, $r_s = -0.601$). The Mann–Whitney U test indicated measurements for SMT post-extraction of thickened SMT group were not significantly different from the pre-implantation SMT of normal SMT group (Z score = -1.319 , $p = .187$). The results of Mann–Whitney U tests for comparing SMT and LWT between the normal SMT group and the collateral arch of thickened SMT group are shown in [Table 4], demonstrating the SMT thickening induced by odontogenic infection was unilateral.

Measures for the LWT3, LWT15, SMT3 and SMT15 showed a wide variation [Table 3], and a broad range of measurements; no significance between measures of the SMT could be determined. Regular follow-up was maintained by 12 of the 14 patients in the thickened SMT group, allowing for longitudinal assessment of radiological changes in the SMT. [Table 5] shows the SMT values post-extraction at the first and last recall. Although the Mann–Whitney U test showed a significant difference in values for the SMT between groups [Table 5], it has no clinical significance. SMT values remained lower than 2 mm for up to 62 months post-extraction.

Discussion

Normal SMT group without odontogenic infection and Thickened SMT group with odontogenic infection were correlated in present study. To reduce the case selection bias,

Table 4 Comparison of CBCT SMT and LWT between the normal SMT group and the contralateral Sinus of the thickened SMT Group.

	SMT	LWT3	SMT3	LWT15	SMT15
Mann–Whitney U test (z-score)	0.379	0.870	0.530	0.110	0.640
There was no significant difference between groups ($p < .05$).					

thickened SMT cases without odontogenic infection, which need intervention of other specialists such as ENT doctors before sinus lifting implant surgery, and normal SMT cases with odontogenic infection, which were not influential to SMT changes, were excluded at the beginning of the research.

Few studies have examined the relevance of the relationship between the SMT and the surrounding hard tissues. In the present study, correlations between SMT and RBH and between SMT from the lateral wall direction and LWT were not statistically significant in the normal SMT group. A histological analysis of Schneiderian membranes by Insua et al. (2017) found thin lateral wall thickness caused by long-term bone resorption could be associated with thin SMT [21]. However, our findings are based on CBCT measurements and are similar to those of Lin et al. (2016) who demonstrated the SMT remains stable radiographically, regardless of surrounding bone changes [22]. The heterogeneity of findings in these studies may be a result of different measurements. Indeed, Insua et al. found differences in measurements depending on whether the analysis was based on histological or radiographic measures. Clinical characteristics of a study group, such as smoking habits, diagnoses of periodontitis, and types of edentulism, are also potential factors that can influence the results. Therefore, we limited inclusion criteria for our normal SMT sample to people seeking single-tooth implant rehabilitation in the posterior maxilla. Middle-aged people are the largest group to receive dental implants [23], therefore the participants in our study are representative of typical dental implant patients. Smokers were excluded due to

Table 5 Longitudinal change in SMT at first and last recall (the first visit and the last visit post-extraction) in thickened SMT group (n = 12).

Group	Follow-up time (months)		SMT (mm)
	Mean	Range (Max/Min)	Mean ± SD
First recall	2.62	5.60/1.5	1.30 ± 0.27
Last recall	23.58	62/7	1.06 ± 0.26
			Mann–Whitney U test $p = .04^a$

^a Significant difference between groups.

the negative effect on sinus augmentation and an increased implant failure rate [24].

Anatomic measurements of the LWT are important when considering sinus lifting procedures using the lateral wall approach. Variation in thickness at different lateral wall sites may lead to increased risk of membrane perforation [25]. Additionally, Kang et al. [26] discovered that the greater the LWT, the wider the vessel diameter, the risk of iatrogenic trauma and excessive bleeding may increase during the procedure. LWT differed according to the maxillary region of the extracted tooth for the normal SMT group in our study. LWT was greater in the second premolar region, and the upper region of the lateral window at different heights, demonstrating penetration of a thicker bony wall would be required in the lateral wall technique. Yang et al. (2012) and Monje et al. (2014), however, showed different trends in increases in LWT from the second premolar to the second molar [27,28]. Other studies [26,29] demonstrated that LWT was greater at higher levels from the sinus floor than at lower levels, in agreement with our findings. Furthermore, it is worth mentioning that in the present study, the upper border in the first molar area was greatest (4.19 ± 2.51 mm). According to Yang, structures neighboring the maxillary sinus, such as the zygomatic buttress, may influence the shape and thickness of the lateral wall [29].

Measurements for maxillary regions of the RBH for the normal SMT group were similar for all three regions. These findings are in contrast to two studies reporting the lowest measurement for the RBH was the first molar region and a higher proportion of sites with an RBH ≤ 4 mm than second premolar or second molar regions [30,31]. However, Shanbhag et al. reported the lowest RBH in the second molar region (4.79 ± 2.69 mm) comparing RBH in the first molar region (5.14 ± 3.36 mm), after measuring 199 sinuses with at least one missing tooth [32]. Among these studies, the sequence of tooth extraction and the time elapsed since tooth loss varied, which resulted in different amounts of ridge resorption and sinus pneumatization, and different measurements for the RBH. In addition, reasons for tooth extraction affect the RBH; extraction due to previous advanced periodontitis results in a lower RBH than for caries or root fractures [7]. The lack of data regarding the reasons for tooth extraction in these normal SMT group prevents us from determining why our data varies from these other studies.

We measured membrane thickness at the time of recall after tooth extraction for the thickened SMT group in our study. The mean time for the first recall was 2.80 months, at which time the pre-extraction thickened Schneiderian membrane had subsided to levels similar to SMT of the normal SMT group. There was no indication of mucosal thickening or infection in any of the following visits. Yoo et al. also monitored the SMT over time after extraction, from 4 to >12 months in three different groups of patients [33]. The thickened Schneiderian membrane needed more than 12 months to recover to a thickness of < 2 mm for patients requiring extraction as a result of periodontal disease. The major variations between two studies may be due to differences in the degrees of dental inflammation for patients in the two studies; most thickened SMT group in our study were in the acute stage of infection, furthermore,

smokers and ENT-related SMT thickening were excluded in the present study, which were not mentioned in Yoo's study. Removing the source of infection is the most important treatment for odontogenic sinus membrane thickening. Infections can be treated by tooth extraction, periodontal therapy, root canal treatment, oral antibiotics, or anti-inflammatory drugs [34]. Our patients' symptoms were relieved after tooth extraction, allowing a more rapid reduction in membrane thickness.

Limitations

Our study had several limitations. First, this was a retrospective study. The thickened SMT in the thickened SMT group might have subsided before the first recall post-extraction, however we have no available data. Second, the sample size of the thickened SMT group was small because obtaining CBCT images prior to extraction is not routine. Third, the data was obtained radiographically, therefore there is heterogeneity of the measurement procedures, and histological specimens were not available for comparison [11]. Although our findings are suggestive of the benefits of obtaining CBCT measures over time, additional prospective studies with sufficient sample size, as well as comprehensive radiographic and histologic findings will be required to more accurately assess changes over time in SMT following tooth extraction.

Conclusions

This study examined the normal and thickened SMT of non-smokers with a single missing tooth. Within the limitations of the present study, it can be concluded that in normal SMT group, RBH and LWT does not have a statistically significant correlation with SMT. In the thickened SMT group, thickened Schneiderian membrane resolution can be observed in 2.80 ± 1.37 months after the extraction of a single tooth with odontogenic infection. A shorter distance between the infection site and sinus floor causes greater SMT but does not prolong the time for the Schneiderian membrane to recover, the Schneiderian membrane maintained a thickness of less than 2 mm at all recall timepoints. Our study findings suggest the risk of sinus lifting surgery associated with SMT can be reduced by radiographic assessments with CBCT of odontogenic infected teeth, before and after extraction and sinus lifting implant surgery maybe considered in about 3 months after extraction.

Funding

The research did not receive any specific grant from funding agencies in the public, commercial, or not-for-profit sectors.

Conflicts of interest

All authors declare no conflicts of interest either financial or nonfinancial.

Acknowledgement

The authors would like to thank Ms. Yi-Ping Pan for editorial and technical assistance, and this study followed the Declaration of Helsinki and was approved by the Medical Ethics Committee of Chang Gung Memorial Hospital (IRB 201800078B0).

REFERENCES

- [1] Beretta M, Poli P, Grossi G, Pieroni S, Maiorana C. Long-term survival rate of implants placed in conjunction with 246 sinus floor elevation procedures: results of a 15-year retrospective study. *J Dent* 2015;43:78–86.
- [2] Boyne PJ, James RA. Grafting of the maxillary sinus floor with autogenous marrow and bone. *J Oral Surg* 1980;38:613–6.
- [3] Tatum Jr H. Maxillary and sinus implant reconstructions. *Dent Clin N Am* 1986;30:207–29.
- [4] Summers RB. A new concept in maxillary implant surgery: the osteotome technique. *Compendium* 1994;15:154–6. 158 passim; quiz 162.
- [5] Schwartz Arad D, Herzberg R, Dolev E. The prevalence of surgical complications of the sinus graft procedure and their impact on implant survival. *J Periodontol* 2004;75:511–6.
- [6] Pjetursson BE, Tan WC, Zwahlen M, Lang NP. A systematic review of the success of sinus floor elevation and survival of implants inserted in combination with sinus floor elevation. *J Clin Periodontol* 2008;35:216–40.
- [7] Lang NP, Lindhe J. *Clinical periodontology and implant dentistry*. 6th ed., vol. 2. John Wiley & Sons; 2015.
- [8] Srouji S, Kizhner T, David DB, Riminucci M, Bianco P, Livne E. The Schneiderian membrane contains osteoprogenitor cells: in vivo and in vitro study. *Calcif Tissue Int* 2009;84:138–45.
- [9] Pommer B, Ulm C, Lorenzoni M, Palmer R, Watzek G, Zechner W. Prevalence, location and morphology of maxillary sinus septa: systematic review and meta-analysis. *J Clin Periodontol* 2012;39:769–73.
- [10] Avila Ortiz G, Neiva R, Galindo Moreno P, Rudek I, Benavides E, Wang HL. Analysis of the influence of residual alveolar bone height on sinus augmentation outcomes. *Clin Oral Implant Res* 2012;23:1082–8.
- [11] Monje A, Diaz KT, Aranda L, Insua A, Garcia Nogaes A, Wang HL. Schneiderian membrane thickness and clinical implications for sinus augmentation: a systematic review and meta-regression analyses. *J Periodontol* 2016;87:888–99.
- [12] Rak KM, Newell 2nd JD, Yakes W, Damiano MA, Luethke JM. Paranasal sinuses on MR images of the brain: significance of mucosal thickening. *AJR Am J Roentgenol* 1991;156:381–4.
- [13] Vallo J, Suominen Taipale L, Huuonen S, Soikkonen K, Norblad A. Prevalence of mucosal abnormalities of the maxillary sinus and their relationship to dental disease in panoramic radiography: results from the Health 2000 Health Examination Survey. *Oral Surg Oral Med Oral Pathol Oral Radiol* 2010;109:e80–7.
- [14] Engström H, Chamberlain D, Kiger R, Egelberg J. Radiographic evaluation of the effect of initial periodontal therapy on thickness of the maxillary sinus mucosa. *J Periodontol* 1988;59:604–8.
- [15] Fatterpekar GM, Delman BN, Som PM. Imaging the paranasal sinuses: where we are and where we are going. *Anat Rec (Hoboken)* 2008;291:1564–72.
- [16] Bremke M, Sesterhenn AM, Murthum T, Al Hail A, Bien S, Werner JA. Digital volume tomography (DVT) as a diagnostic modality of the anterior skull base. *Acta Otolaryngol* 2009;129:1106–14.
- [17] Shahbazian M, Jacobs R. Diagnostic value of 2D and 3D imaging in odontogenic maxillary sinusitis: a review of literature. *J Oral Rehabil* 2012;39:294–300.
- [18] McGuire MK. Prognosis versus actual outcome: a long-term survey of 100 treated periodontal patients under maintenance care. *J Periodontol* 1991;62:51–8.
- [19] Chan HL, Suarez F, Monje A, Benavides E, Wang HL. Evaluation of maxillary sinus width on cone-beam computed tomography for sinus augmentation and new sinus classification based on sinus width. *Clin Oral Implant Res* 2014;25:647–52.
- [20] Buser D, Chen ST, Weber HP, Belser UC. Early implant placement following single-tooth extraction in the esthetic zone: biologic rationale and surgical procedures. *Int J Periodontics Restor Dent* 2008;28:441–51.
- [21] Insua A, Monje A, Chan HL, Zimmo N, Shaikh L, Wang HL. Accuracy of Schneiderian membrane thickness: a cone-beam computed tomography analysis with histological validation. *Clin Oral Implant Res* 2017;28:654–61.
- [22] Lin YH, Yang YC, Wen SC, Wang HL. The influence of sinus membrane thickness upon membrane perforation during lateral window sinus augmentation. *Clin Oral Implant Res* 2016;27:612–7.
- [23] Brennan N, Houston F, O'Sullivan M, O'Connell B. Demographics of implant placement and complications of a patient subgroup in a dental hospital population. *J Ir Dent Assoc* 2010;56:85–92.
- [24] Barone A, Santini S, Sbordone L, Crespi R, Covani U. A clinical study of the outcomes and complications associated with maxillary sinus augmentation. *Int J Oral Maxillofac Implant* 2006;21:81–5.
- [25] Neiva RF, Gapski R, Wang HL. Morphometric analysis of implant-related anatomy in Caucasian skulls. *J Periodontol* 2004;75:1061–7.
- [26] Kang SJ, Shin SI, Herr Y, Kwon YH, Kim GT, Chung JH. Anatomical structures in the maxillary sinus related to lateral sinus elevation: a cone beam computed tomographic analysis. *Clin Oral Implant Res* 2013;24:75–81.
- [27] Yang SM, Park SI, Kye SB, Shin SY. Computed tomographic assessment of maxillary sinus wall thickness in edentulous patients. *J Oral Rehabil* 2012;39:421–8.
- [28] Monje A, Catena A, Monje F, Gonzalez García R, Galindo Moreno P, Suarez F, et al. Maxillary sinus lateral wall thickness and morphologic patterns in the atrophic posterior maxilla. *J Periodontol* 2014;85:676–82.
- [29] Yang HM, Bae K, Eun H, Won SY, Hu KS, Song WC, et al. The buccofacial wall of maxillary sinus: an anatomical consideration for sinus augmentation. *Clin Implant Dent Relat Res* 2009;11:e2–6.
- [30] Pramstraller M, Farina R, Franceschetti G, Pramstraller C, Trombelli L. Ridge dimensions of the edentulous posterior maxilla: a retrospective analysis of a cohort of 127 patients using computerized tomography data. *Clin Oral Implant Res* 2011;22:54–61.
- [31] Kopecka D, Simunek A, Brazda T, Rota M, Slezak R, Capek L. Relationship between subsinus bone height and bone volume requirements for dental implants: a human radiographic study. *Int J Oral Maxillofac Implant* 2012;27:48–54.
- [32] Shanbhag S, Karnik P, Shirke P, Shanbhag V. Cone-beam computed tomographic analysis of sinus membrane thickness, ostium patency, and residual ridge heights in the posterior maxilla: implications for sinus floor elevation. *Clin Oral Implant Res* 2014;25:755–60.
- [33] Yoo JY, Pi SH, Kim YS, Jeong SN, You HK. Healing pattern of the mucous membrane after tooth extraction in the maxillary sinus. *J Periodontal Implant Sci* 2011;41:23–9.
- [34] Mehra P, Murad H. Maxillary sinus disease of odontogenic origin. *Otolaryngol Clin* 2004;37:347–64.