


Reactivation of IgA vasculitis following COVID-19 vaccination

James A Maye ¹, Hsu Pheen Chong,^{1,2} Vivek Rajagopal,^{1,3} William Petchey^{1,2}

¹Department of General Medicine, West Suffolk Hospital NHS Foundation Trust, Bury St Edmunds, UK

²Department of Nephrology, West Suffolk Hospital NHS Foundation Trust, Bury St Edmunds, UK

³Department of Rheumatology, West Suffolk Hospital, Bury St Edmunds, UK

Correspondence to

Dr James A Maye;
j.anthonymaye@gmail.com

Accepted 16 November 2021

SUMMARY

A 23-year-old man presented to the acute assessment unit with acute-onset haematuria within 24 hours of receiving his second dose of the Pfizer-BioNTech COVID-19 vaccine. He had been diagnosed with IgA vasculitis 8 months previously. IgA vasculitis is an autoimmune condition characterised by palpable purpura affecting the lower limbs, abdominal pain, arthralgia and renal disease. He was diagnosed with an acute exacerbation of IgA vasculitis and was discharged with oral prednisolone. Reactivation or first presentation of IgA vasculitis is a rare but increasingly recognised complication of COVID-19 vaccination. This is an important new differential in the assessment of patients with haematuria following COVID-19 vaccination.

BACKGROUND

Debate continues regarding the effect of COVID-19 vaccination on the incidence of exacerbations of autoimmune disease.^{1,2} With continued efforts for vaccination against COVID-19 globally and the introduction of additional ‘booster’ doses required to combat future variants of SARS-CoV-2, any impact that vaccination may have on pre-existing autoimmune conditions will continue to be relevant for the foreseeable future.

IgA nephropathy and IgA vasculitis together constitute the most common cause of primary glomerulonephritis in adults and the most common cause of haematuria in children. Reports of exacerbations in patients with IgA nephropathy and IgA vasculitis following COVID-19 vaccination have begun to appear in specialty-focused journals. As postvaccination complications are most likely to present acutely to primary or secondary care, awareness of the possibility of exacerbation of autoimmune diseases following COVID-19 vaccination is important to aid in the diagnosis and management of these conditions.

This report describes the assessment and management of a man presenting with reactivation of IgA vasculitis less than 24 hours after his second dose of COVID-19 vaccine. The case provides further evidence of the potential for exacerbations of IgA vasculitis to occur following COVID-19 vaccination and is an illustrative example for acute physicians assessing patients who present after receiving the COVID-19 vaccine.

CASE PRESENTATION

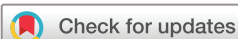An otherwise fit and well 23-year-old student presented to the acute assessment unit with macroscopic haematuria, left-sided flank and back pain,

and a palpable purpuric rash. He reported that he was no longer passing any urine, only frank blood. He had received his second dose of the BNT162b2 (Pfizer-BioNTech) COVID-19 vaccine within the preceding 24 hours. On examination he was haemodynamically stable with a blood pressure of 110/68 and pulse of 72 beats per minute. Dermatological examination showed a symmetrical tender, non-blanching petechial rash with excoriation affecting the lower limbs, buttocks, waist and medial aspects of the arms ([figure 1](#)). Abdominal examination was normal with no abdominal or renal angle tenderness. General examination was otherwise unremarkable.

The patient had presented 8 months earlier with a spreading petechial rash predominantly affecting the lower limbs and a range of non-specific symptoms including chest pain, nose-bleeds, night sweats, arthralgia and abdominal pain. He was noted to have 4+ microscopic haematuria on urinalysis. Following assessment by the cardiology, rheumatology, nephrology and otolaryngology teams, he was diagnosed with presumed IgA vasculitis. On subsequent outpatient nephrology review prior to his acute admission, the patient was noted to have occasional light macroscopic haematuria but with stable renal function and minimal proteinuria.

INVESTIGATIONS

By the time of presentation following COVID-19 vaccination, the patient had already undergone several investigations both at the time of his initial presentation and following outpatient nephrology review. On his initial presentation, urine analysis showed a red cell count of 165 cells/mm³, with a urinary albumin to creatinine ratio of 4.9 mg/mmol. His serum creatinine was raised at 112 µmol/L (estimated Glomerular Filtration Rate 79 mL/min); however, serum urea and all tested electrolytes were within normal range. His inflammatory markers and liver function tests were similarly not deranged. Serum immunoglobulins demonstrated raised IgA titres at 3.10 g/L; other immunoglobulins and complement levels were within normal range. Serum antinuclear antibody (ANA), antineutrophil cytoplasmic antibody (ANCA) and rheumatoid factor titres were all negative. Viral antibody titres were negative for evidence of acute or chronic infections including HIV. At the time of acute presentation following COVID-19 vaccination, the patient had not undergone a renal biopsy for histology. As there was sufficient clinical evidence to support a diagnosis of IgA vasculitis, invasive investigations



© BMJ Publishing Group Limited 2021. No commercial re-use. See rights and permissions. Published by BMJ.

To cite: Maye JA, Chong HP, Rajagopal V, *et al.* *BMJ Case Rep* 2021;**14**:e247188. doi:10.1136/bcr-2021-247188

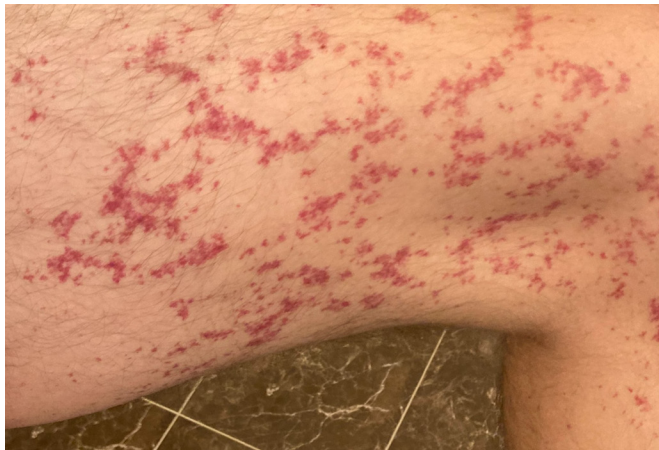

Figure 1 Petechial rash on the lateral aspect of the right lower limb.

such as skin biopsy of the rash and renal biopsy were not carried out.

An ultrasound scan of the renal tract organised prior to the patient's acute admission showed a possible mild right hydronephrosis with no other pathological features noted. Both kidneys were of normal size. A subsequent unenhanced CT scan of the renal tract showed no evidence of right-sided hydronephrosis. It demonstrated a non-obstructing calculus within the upper pole of the left kidney measuring 6 mm in diameter. Both kidneys and the bladder appeared otherwise unremarkable, as did the unenhanced appearances of the imaged portion of the upper abdominal organs.

Further investigations were performed at the time of his acute presentation. Serum creatinine showed a mild rise to 126 $\mu\text{mol/L}$ (estimated glomerular filtration rate 69 mL/min) compared with a creatinine of 111 $\mu\text{mol/L}$ 1 month prior. Urine dipstick analysis showed significant haematuria. Urinary albumin to creatinine ratio was acutely raised at 21.9 mg/mmol. C reactive protein titres were mildly elevated at 12 mg/L. Clotting studies were normal: prothombin time (PT) 13.0 s (reference range: 10–15 s) and activated partial thromboplastin time (APTT) 18.5 s (reference range: 25–36). Platelet count was $143 \times 10^9/\text{L}$. Urine culture demonstrated no growth.

A CT scan of the renal tract was repeated in an attempt to exclude any renal tract calculi causing obstructive nephropathy and frank haematuria. This showed no change compared with the previous CT, with the single 6 mm calculus within the upper pole of the left kidney unaltered in location or appearance.

DIFFERENTIAL DIAGNOSIS

At the time of presentation with flank pain and haematuria following COVID-19 vaccination, there was little in the literature relating to exacerbation of IgA vasculitis or autoimmune renal disease following COVID-19 vaccination. The key differentials considered were reactivation of IgA vasculitis or a renal calculus causing traumatic haematuria with or without obstruction. The renal calculus seen on previous renal tract imaging made differentiation between these potential diagnoses difficult.

Other causes of haematuria which were discounted included urinary tract infection, which is unlikely in a male patient in the third decade of life without reported dysuria. Renal tract tumours were unlikely given the recent negative ultrasound and CT imaging. A bleeding diathesis was unlikely with a normal platelet count and clotting studies and no history of previous bleeding other than the haematuria diagnosed as IgA vasculitis.

As the patient was otherwise clinically well, a repeat CT renal tract was performed as an outpatient in an attempt to differentiate exacerbation of IgA vasculitis and renal calculi as the cause of the patient's symptoms. This showed no features suggestive of obstructive nephropathy or symptomatic renal calculi, leaving an acute exacerbation of IgA vasculitis as the most likely diagnosis.

TREATMENT

The patient had previously been trialled on an acute course of oral prednisolone, which had alleviated his arthralgia and mild haematuria but had little effect on his vasculitic rash. The patient was discharged on a weaning course of prednisolone with an initial dose of 20 mg once daily, with 20 mg famotidine for gastro-protection and 1500 mg calcium carbonate with 400 IU vitamin D₃ for prevention of steroid-induced deficiency. Following the report of deterioration in his vasculitic rash on reduction of the prednisolone dose to 15 mg, his dose was maintained at 20 mg for a further 2 weeks before resuming a weaning regimen of 5 mg reduction per week.

OUTCOME AND FOLLOW-UP

The patient was reviewed in nephrology clinic 2 weeks after presentation postvaccine. He had received 2 weeks of oral prednisolone 20 mg daily, having reported a deterioration in his vasculitic rash after reducing the prednisolone dose to 15 mg after 7 days. By the time of review, his rash had completely resolved as had his macroscopic haematuria. Urine dipstick analysis was negative for blood, while urine albumin to creatinine ratio had fallen from 21.9 to 2.7 mg/mmol. He reported no new symptoms. He was offered a renal biopsy and at the time of writing is contemplating the procedure and the risk and benefit of this. The renal biopsy would aid the diagnosis of IgA nephropathy and is of educational benefit. The procedure however would not necessarily change management from the current conservative approach given that the patient had minimal proteinuria and relatively preserved renal function.

DISCUSSION

IgA nephropathy is the most common cause of primary glomerulonephritis. It has a variable presentation with microscopic or macroscopic haematuria and proteinuria. It has a male preponderance and the peak incidence is in the second and third decades of life. Histopathological findings on renal biopsy are of mesangial hypercellularity, segmental glomerulosclerosis and mesangial deposition of polymeric IgA. IgA vasculitis, previously Henoch-Schönlein purpura, is the most common vasculitis in children. It presents with a purpuric rash classically affecting the lower extremities and buttocks, abdominal pain, arthralgia and glomerulonephritis, which may be histologically indistinguishable from IgA nephropathy, leading some to suggest that there may be some overlap or shared pathophysiology between the two conditions.^{3 4}

Diagnosis of IgA vasculitis in adult patients, such as in the case discussed in this article, is complicated by the fact that this is classically a condition with onset in childhood. The 1990 American College of Rheumatology classification⁵ requires the presence of at least two of the following four criteria: age ≤ 20 years at onset, palpable purpura, acute abdominal pain/bowel angina and biopsy histology showing granulocytes on the vessel walls. The 2010 EULAR/PRINTO/PRES (European League Against Rheumatism/Paediatric Rheumatology International Trials Organisation/Paediatric Rheumatology European Society) criteria⁶ for classifying IgA vasculitis (box 1) was designed and

Box 1 EULAR/PRINTO/PRES criteria for IgA vasculitis⁶

Purpura or petechiae with lower limb predominance and at least one of the following:

- ▶ Abdominal pain.
- ▶ Histopathology: leucocytoclastic vasculitis or proliferative glomerulonephritis with IgA-predominant deposits.
- ▶ Arthritis or arthralgia.
- ▶ Renal involvement: proteinuria >0.3 g/24 hours or haematuria or red cell casts.

validated using a sample of paediatric patients only, making it of uncertain utility in the classification of adult patients. With this caveat, the patient discussed in this case had clinical features corresponding well to the EULAR/PRINTO/PRES criteria for IgA vasculitis.

With the ongoing international drive for COVID-19 vaccination coverage, there has inevitably been a rise in rare postvaccination complications. The remarkable speed at which vaccines have been developed and deployed means that there is limited information on postvaccination effects in particular patient groups, for example those with autoimmune conditions. It is well recognised that challenges to the immune system, predominantly in the form of mucosal infections affecting the upper respiratory tract, cause acute flares in IgA disease with synpharyngitic macroscopic haematuria episodes.⁷ It is thought that immune challenges from vaccination may similarly cause flares of IgA vasculitis.

There have been a number of recent cases reporting similar exacerbations of IgA vasculitis or nephropathy following COVID-19 vaccination. As in this case, gross haematuria within 24 hours of receiving the COVID-19 vaccine has been reported in a 52-year-old with previous histology-proven IgA nephropathy.⁸ The patient's symptoms resolved spontaneously within 1 week of onset. Several cases of new diagnoses with IgA nephropathy after receiving the second dose of the Moderna COVID-19 vaccine have also been reported.⁹ Biopsy findings of focal glomerular and tubular scarring and a history of microscopic haematuria in these cases suggest that these represent exacerbation of previously subclinical IgA nephropathy. Both cases resolved without intervention within 5 days. Similar to the case presented here, these reports demonstrate short-lasting symptoms resolving either spontaneously or following an acute course of steroids. Further studies are required to assess whether this holds for all cases of IgA vasculitis induced by COVID-19 vaccination. Adult-onset IgA vasculitis in general has a highly variable clinical course with little correlation between severity of acute presentation and progression to end-stage renal failure.¹⁰ One report suggests that a cohort of patients with subclinical glomerulonephritis may have their condition unmasked following COVID-19 vaccination and present acutely with haematuria of unknown aetiology.¹¹ It remains to be seen whether the cohort of patients with IgA vasculitis exacerbated by COVID-19 vaccination represents a new group with a homogeneous clinical course or the same variable course seen in IgA vasculitis previously.

A recent report has suggested that autoreactivity of serum anti-SARS-CoV-2 spike IgA may play a pathophysiological role in postvaccine exacerbations.¹² Prevacination and postvaccination serum samples from a patient with reactivation of IgA vasculitis following COVID-19 vaccination demonstrated autoreactivity of the patient's IgA following vaccination, whereas serum taken prior to vaccination and from two healthy donors

postvaccination did not demonstrate autoreactivity. Further work is required to firmly establish a causal link between COVID-19 vaccination and exacerbation of IgA vasculitis. However, taken together the current literature suggests that exacerbation of IgA vasculitis is a possible differential in patients presenting with frank haematuria following recent COVID-19 vaccination.

Learning points

- ▶ This is one of the first reported cases of acute exacerbation of IgA vasculitis following COVID-19 vaccination in the UK.
- ▶ IgA vasculitis and IgA nephropathy are two overlapping conditions which together represent the most common cause of haematuria in children and primary glomerulonephritis in adults.
- ▶ IgA vasculitis classically also presents with a purpuric rash predominantly affecting the lower limbs, abdominal pain and arthralgia.
- ▶ Exacerbation or first presentation of IgA vasculitis is a rare but increasingly recognised complication following COVID-19 vaccination.
- ▶ IgA vasculitis may present in previously undiagnosed cases and represents an important new differential in patients presenting with acute-onset haematuria following COVID-19 vaccination.

Contributors The patient was under the care of HPC and VR. The manuscript was authored by JAM. WP and HPC contributed to editing the manuscript. The report was conceptualised and overseen by WP.

Funding The authors have not declared a specific grant for this research from any funding agency in the public, commercial or not-for-profit sectors.

Competing interests None declared.

Patient consent for publication Obtained.

Provenance and peer review Not commissioned; externally peer reviewed.

This article is made freely available for use in accordance with BMJ's website terms and conditions for the duration of the covid-19 pandemic or until otherwise determined by BMJ. You may use, download and print the article for any lawful, non-commercial purpose (including text and data mining) provided that all copyright notices and trade marks are retained.

Case reports provide a valuable learning resource for the scientific community and can indicate areas of interest for future research. They should not be used in isolation to guide treatment choices or public health policy.

ORCID iD

James A Maye <http://orcid.org/0000-0001-8116-1444>

REFERENCES

- 1 Boekel L, Kummer LY, van Dam KPJ, *et al*. Adverse events after first COVID-19 vaccination in patients with autoimmune diseases. *Lancet Rheumatol* 2021;3:e542–5.
- 2 Barbhuiya M, Levine JM, Bykerk VP, *et al*. Systemic rheumatic disease flares after SARS-CoV-2 vaccination among rheumatology outpatients in New York City. *Ann Rheum Dis* 2021;80:1352–4.
- 3 Pillebout E. IgA vasculitis and IgA nephropathy: same disease? *J Clin Med* 2021;10:2310.
- 4 Davin JC, Ten Berge IJ, Weening JJ. What is the difference between IgA nephropathy and Henoch-Schönlein purpura nephritis? *Kidney Int* 2001;59:823–34.
- 5 Mills JA, Michel BA, Bloch DA. The American college of rheumatology 1990 criteria for the classification of Henoch-Schönlein purpura. *Arthritis Rheum* 1990;33:1113–21.
- 6 Ruperto N, Ozen S, Pistorio A, *et al*. EULAR/PRINTO/PRES criteria for Henoch-Schönlein purpura, childhood polyarteritis nodosa, childhood Wegener granulomatosis and childhood Takayasu arteritis: Ankara 2008. Part I: overall methodology and clinical characterisation. *Ann Rheum Dis* 2010;69:790–7.
- 7 Rollino C, Vischini G, Coppo R. IgA nephropathy and infections. *J Nephrol* 2016;29:463–8.
- 8 Rahim SEG, Lin JT, Wang JC. A case of gross hematuria and IgA nephropathy flare-up following SARS-CoV-2 vaccination. *Kidney Int* 2021;100:238.

- 9 Kudose S, Friedmann P, Albajrami O, *et al.* Histologic correlates of gross hematuria following Moderna COVID-19 vaccine in patients with IgA nephropathy. *Kidney Int* 2021;100:468–9.
- 10 Audemard-Verger A, Pillebout E, Guillevin L, *et al.* IgA vasculitis (Henoch-Shönlein purpura) in adults: diagnostic and therapeutic aspects. *Autoimmun Rev* 2015;14:579–85.
- 11 Tan HZ, Tan RY, Choo JC, *et al.* Is COVID-19 vaccination unmasking glomerulonephritis? *Kidney Int* 2021;100:469–71.
- 12 Obeid M, Fenwick C, Pantaleo G. Reactivation of IgA vasculitis after COVID-19 vaccination. *Lancet Rheumatol* 2021;3:e617.

Copyright 2021 BMJ Publishing Group. All rights reserved. For permission to reuse any of this content visit <https://www.bmj.com/company/products-services/rights-and-licensing/permissions/>
BMJ Case Report Fellows may re-use this article for personal use and teaching without any further permission.

Become a Fellow of BMJ Case Reports today and you can:

- ▶ Submit as many cases as you like
- ▶ Enjoy fast sympathetic peer review and rapid publication of accepted articles
- ▶ Access all the published articles
- ▶ Re-use any of the published material for personal use and teaching without further permission

Customer Service

If you have any further queries about your subscription, please contact our customer services team on +44 (0) 207111 1105 or via email at support@bmj.com.

Visit casereports.bmj.com for more articles like this and to become a Fellow