

Emergency management of near-complete paediatric airway obstruction by vocal cord papillomas

Sir,

Managing a child with severe respiratory distress due to near-complete airway obstruction without the option of bag-mask ventilation, supraglottic device placement, or intubation poses serious challenges even when attempting an emergency front of neck access. High flow nasal oxygen in the presence of airway obstruction is not effective. However, apnoeic oxygenation could still save lives if airway obstruction could be bypassed. A 6-year-old, 15-kg male child presented to our emergency department in an agitated state with obvious features of airway obstruction including severe intercostal and subcostal chest retractions. He was rushed inside the operating room for an urgent tracheostomy. Oxygen saturation was 65%–68% and not improving even with 100% oxygen. Bag-mask ventilation produced no chest rise. Immediately direct laryngoscopy was performed and vocal cords were found completely obscured by papillomatous growths. Only with vigorous inspiratory efforts, a small aperture appeared as a small dark hole at around the 6 o'clock position with an overhanging warty outgrowth [Figure 1a]. It was obvious that no

available endotracheal tube could be negotiated through it. The smallest available suction catheter (size 6) was immediately taken and threaded with difficulty through this opening by a senior consultant anaesthesiologist. Oxygen was cautiously started at flows of 2–3 L/min. Simultaneous attempts at the bag and mask ventilation continued using the closed circuit of a Draeger Primus anaesthesia workstation [Figure 1b]. No end-tidal carbon dioxide (ETCO₂) tracing could be seen; however, saturation slowly started improving. Once it crossed 90%, fentanyl 1 µg/kg was given and sevoflurane started at 1%. Surgeons were able to safely perform tracheostomy of the child without panic.

For a child with complete obstruction at the vocal cord, an emergency front of neck access is probably the only option available to prevent arrest. When intubation fails and mask ventilation is also not possible, Difficult Airway Society United Kingdom as well as the Indian guidelines suggest ensuring muscle paralysis before embarking upon a surgical airway.^[1,2] We believe, in our case, paralysing the child would have been counter-productive. The respiratory efforts of this child and vocal cord abduction were what allowed initial visualisation of the glottic aperture. Washout of carbon dioxide was also important in this case which was only possible with the child breathing. Paralysing a difficult airway patient has its benefits in other scenarios; however, in cases like ours, where respiratory efforts could be harvested in airway management, all choices should be carefully considered.

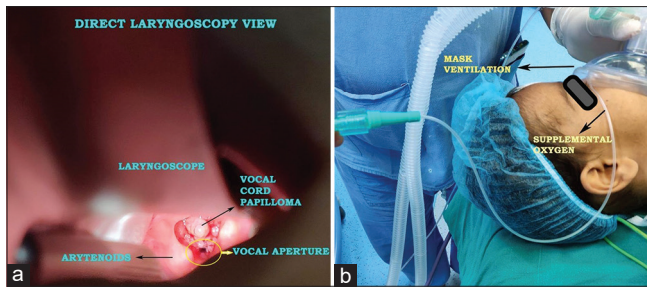


Figure 1: (a) Narrowed glottic aperture initially obscured by the papillomas but visible only after vigorous respiratory efforts. Suction catheter was threaded through this aperture. Picture was taken after stabilisation of patient, post-tracheostomy. (b) Oxygenation provided through a suction catheter and mask ventilation attempted with face mask keeping catheter *in situ*

The only other option available to us was emergency cricothyrotomy. It would buy us time; however, definitive management in such children is still a tracheostomy.^[2] With competent surgeons available for tracheostomy, it was important to give them time to perform tracheostomy without disturbing the surgical anatomy. An important aspect of oxygen flows through the suction catheter is possible barotrauma.^[3] Though suction catheter for oxygenation has been used earlier, in our case, the catheter was placed inside trachea rather than outside.^[4] One must start with low flows for fear of insufficient exit of the delivered gases. Vigorous respiratory efforts created the small aperture. Splinting of this passage by a suction catheter may allow trapped oxygen/air to egress with each opportunity available to it, thus preventing barotrauma.

Mortality and morbidity in such cases are due to failure of oxygen delivery to the lungs. Almost all guidelines advise practitioners to actively pursue opportunities to deliver supplemental oxygen during emergency airway management.^[5] This report highlights one such situation where even in the face of almost complete airway obstruction, oxygen could be delivered to the lung through a suction catheter threaded through the small glottic aperture available.

Declaration of patient consent

The authors certify that they have obtained all appropriate patient consent forms. In the form the patient(s) has/have given his/her/their consent for his/her/their images and other clinical information to be reported in the journal. The patients understand that their names and initials will not be published and due efforts will be made to conceal their identity, but anonymity cannot be guaranteed.

Financial support and sponsorship

Nil.

Conflicts of interest

There are no conflicts of interest.

**Nishant Sahay, Rajnish Kumar,
Bhartendu Bharti¹, Raman Jha**

Departments of Anaesthesiology, and ¹ENT, AIIMS, Patna, Bihar, India

Address for correspondence:

Dr. Nishant Sahay,
Room 503, B5A, New OT Complex (5th Floor), IPD Building, AIIMS,
Phulwarisharif, Patna - 801 505, Bihar, India.
E-mail: nishantsahay@gmail.com

Submitted: 11-Dec-2020

Revised: 26-Dec-2020

Accepted: 21-Jan-2021

Published: 20-May-2021

REFERENCES

1. Frerk C, Mitchell VS, McNarry AF, Mendonca C, Bhagrath R, Patel A, *et al.* Difficult Airway Society intubation guidelines working group, Difficult Airway Society 2015 guide lines for management of unanticipated difficult intubation in adults. *Br J Anaesth* 2015;115:827-48.
2. Pawar DK, Doctor JR, Raveendra US, Ramesh S, Shetty SR, Divatia JV, *et al.* All India Difficult Airway Association 2016 guidelines for the management of unanticipated difficult tracheal intubation in Paediatrics. *Indian J Anaesth* 2016;60:906-14.
3. YanHong R, Ihra GC, Gore C. Determination of gas flow through airway exchange catheters: Measured and calculated values and dependence on pressure and entrainment. *Anaesthesia* 2015;70:1073-8.
4. Sahay N, Bhadani UK, Singh R. Device for centralisation during fibrescope-guided orotracheal intubation. An i-gel® innovation. *Indian J Anaesth* 2019;63:945-6.
5. Myatra SN, Shah A, Kundra P, Patwa A, Ramkumar V, Divatia JV, *et al.* All India Difficult Airway Association 2016 guidelines for the management of unanticipated difficult tracheal intubation in adults. *Indian J Anaesth* 2016;60:885-98.

This is an open access journal, and articles are distributed under the terms of the Creative Commons Attribution-NonCommercial-ShareAlike 4.0 License, which allows others to remix, tweak, and build upon the work non-commercially, as long as appropriate credit is given and the new creations are licensed under the identical terms.

Access this article online	
Quick response code	Website: www.ijaweb.org
	DOI: 10.4103/ija.IJA_1443_20

How to cite this article: Sahay N, Kumar R, Bharti B, Jha R. Emergency management of near complete paediatric airway obstruction by vocal cord papillomas. *Indian J Anaesth* 2021;65:420-1.

© 2021 Indian Journal of Anaesthesia | Published by Wolters Kluwer - Medknow