



The added value of ultrasound imaging biomarkers to clinicopathological factors for the prediction of high-risk Oncotype DX recurrence scores in patients with breast cancer

Yanwen Luo^{1^}, Yuanjing Gao¹, Zihan Niu¹, Jing Zhang¹, Zhenzhen Liu¹, Yanna Zhang², Songjie Shen², Yuxin Jiang¹, Mengsu Xiao^{1#^}, Qingli Zhu^{1#^}

¹Department of Ultrasound, Peking Union Medical College Hospital, Chinese Academy of Medical Science and Peking Union Medical College, Beijing, China; ²Department of Breast Surgery, Peking Union Medical College Hospital, Chinese Academy of Medical Science and Peking Union Medical College, Beijing, China

Contributions: (I) Conception and design: Q Zhu, M Xiao; (II) Administrative support: Y Jiang, S Shen; (III) Provision of study materials or patients: Y Zhang, J Zhang, Z Liu; (IV) Collection and assembly of data: Z Niu, Y Luo; (V) Data analysis and interpretation: Y Luo, Y Gao; (VI) Manuscript writing: All authors; (VII) Final approval of manuscript: All authors.

#These authors contributed equally to this work as co-corresponding authors.

Correspondence to: Qingli Zhu, MD; Mengsu Xiao, MD. Department of Ultrasound, Peking Union Medical College Hospital, Chinese Academy of Medical Science and Peking Union Medical College, No. 1 Shuaifuyuan, Dongcheng District, Beijing 100730, China. Email: zqlpumch@126.com; xiaomengsu_2000@sina.com.

Background: The Oncotype DX (ODX) recurrence score (RS), a 21-gene assay, has been proven to recognize patients at high risk of recurrence (RS ≥ 26) who would benefit from chemotherapy. However, it has limited availability and high costs. Our study thus aimed to identify ultrasound (US) imaging biomarkers and develop a prediction model for identifying patients with a high ODX RS.

Methods: In this retrospective study, consecutive patients with T1–3N0–1M0 breast cancer who were hormone receptor positive and human epidermal growth factor receptor 2 (HER2) negative who had an available ODX RS were reviewed. Patients treated from May 2012 and December 2015 were placed into a training cohort, and those treated from January 2016 to January 2017 were placed in a validation cohort. Clinicopathologic data were collected, and preoperative US scans were analyzed. Univariable and multivariable regression analyses were performed to evaluate the independent predictors for a high-risk of breast cancer in the training cohort, and a nomogram was developed and evaluated with the area under the receiver operating characteristic curve (AUC), calibration curve, and decision curve analysis (DCA).

Results: A total of 363 patients were in the training cohort and 160 in the validation cohort, with the proportion with a high RS (RS 26–100) being 14% and 13.1%, respectively. Echogenic halo, enhanced posterior echo, low level of progesterone receptor (PR), and high Ki-67 index were identified as independent risk factors for high RS (all P values < 0.05). The nomogram was constructed based on the combined model, which showed a better discrimination ability than did the clinicopathological model [combined model: AUC = 0.95, 95% confidence interval (CI): 0.93–0.97; clinicopathological model: AUC = 0.89, 95% CI: 0.86–0.92; P = 0.001] and greater clinical benefit according to DCA. Furthermore, the nomogram was found to be effective in the validation cohort (AUC = 0.90, 95% CI: 0.84–0.94), especially in patients with stage T1N0M0 disease (AUC = 0.91, 95% CI: 0.84–0.95).

Conclusions: US features may serve as valuable imaging biomarkers for the prediction of high recurrence

[^] ORCID: Yanwen Luo, 0000-0003-1473-7268; Qingli Zhu, 0000-0002-0618-2381; Mengsu Xiao, 0000-0003-1631-3696.

risk in patients with T1–3N0–1M0 breast cancer and hormone receptor (HR)-positive and HER2-negative status. A nomogram incorporating PR status, Ki-67 index, and US imaging biomarkers showed a good discrimination ability in the early selection of patients at high risk of recurrence, especially in those with stage T1N0M0 disease.

Keywords: Breast cancer; Oncotype DX (ODX); high risk; ultrasound (US)

Submitted Nov 15, 2023. Accepted for publication Mar 22, 2024. Published online Apr 26, 2024.

doi: 10.21037/qims-23-1620

View this article at: <https://dx.doi.org/10.21037/qims-23-1620>

Introduction

Breast cancer is the most prevalent cancer and the leading cause of mortality among women globally (1,2). Selection of patients at high-risk of recurrence who would benefit from the adjuvant chemotherapy is essential to improving overall survival. With the advancements made in precision medicine and the deepening understanding of breast cancer's biological underpinnings, multigene assays have emerged to provide greater insights into the risk of breast cancer beyond those of conventional histological characteristics.

Oncotype DX (ODX) recurrence score (RS) assay (Genomic Health, Redwood City, CA, USA) is a 21-gene real-time polymerase chain reaction (PCR)-based assay which was created to determine the risk of a recurrence in women with hormone receptor (HR)-positive, human epidermal growth factor receptor 2 (HER2)-negative, T1–3N0–1M0 breast cancer (3). The National Surgical Adjuvant Breast and Bowel Project (NSABP) B-20 trial was the first study to retrospectively confirm that ODX can be used as both a prognostic tool and a predictive tool for the magnitude of chemotherapy benefit. It was found that patients with high-RS tumors could receive substantial benefit from chemotherapy, with an absolute decrease in 10-year distant recurrence rate of 27.6% (freedom from distant recurrence was improved from 60% to 88%). Whereas, for patients with low-RS tumor (≤ 10), the benefit of chemotherapy was minimal benefit (4). TAILORx clinical trial showed that all patients in the low-RS group received endocrine therapy alone without chemotherapy, and the recurrence-free survival of breast cancer at the local/regional or distant site was 96.8% (5). Thus, it is crucial to select the individuals with a high-RS ($RS \geq 26$) who would benefit from the chemotherapy for improving outcomes. Currently, the ODX RS assay is the most prominent genomic assessment for HR-positive cancers and is favored by the National Comprehensive Cancer Network (NCCN) (6)

and the American Society of Clinical Oncology (ASCO) (7). However, the high cost and time-consuming nature of the ODX have prompted the search for a more widely applicable and easy-to-use tool.

Several attempts have been made to determine the correlation between RS and various predictive clinicopathological indicators, including the expression of estrogen receptor (ER) and progesterone receptor (PR), high histologic grade, and Ki-67 proliferation index, which have yielded a variety of models (8–12). However, the predictive performance has varied widely across studies, with the accuracy ranging from 52.5–86.8%. The predictive accuracy has been further improved via the use of clinicopathologic and magnetic resonance imaging (MRI) parameters, with the resulting area under the receiver operating characteristic curve (AUC) for predicting the probability of $RS \geq 26$ ranging from 0.75 to 0.90 (9–11). Ultrasound (US), given its high soft-tissue contrast and sensitivity, is one of the most common modalities used in the diagnosis of breast cancer (12). In recent years, studies have shown a correlation between US features and RS (13,14). One recent study built a model based on shear-wave elastography (SWE), yielding a high AUC of 0.86 and demonstrating the feasibility using US imaging factors for risk prediction (15). However, its predictive ability still needs to be improved for MRI results, and the value of conventional US imaging features for the assessment of RS remains unclear. Furthermore, stage I, HR-positive, HER2-negative cancers are considered “favorable-risk” cancers and are treated with tamoxifen or aromatase inhibitors only, expect for in a few high risk of recurrence groups. The ability to distinguish populations at high risk from those with a better prognosis would be highly valuable.

Therefore, the aim of this study was to investigate the US features associated with the ODX RS and to construct a nomogram combining US imaging biomarkers with clinicopathological factors to predict a high RS. The

proposed nomogram can potentially be used in clinical practice to predict patients at high risk. We present this article in accordance with the TRIPOD reporting checklist (available at <https://qims.amegroups.com/article/view/10.21037/qims-23-1620/rc>).

Methods

This study was conducted in accordance with the Declaration of Helsinki (as revised in 2013) and was approved by the Ethics Committee of the Peking Union Medical College Hospital (No. K3032). The requirement of individual consent for this retrospective analysis was waived.

Patients

All patients had ER-positive, HER2-negative, T1–3N0–1M0 breast cancer and an available ODX test result admitted to Peking Union Medical College Hospital from May 2012 to January 2017 were consecutively enrolled in our study. The exclusion criteria were as follows: (I) incomplete US images, (II) incomplete clinicopathologic information, and (III) administration of biopsy or neoadjuvant treatment (NAT) before preoperative US.

Ultimately, 523 patients were included in the study, 488 of whom were reported in a previous study (16). This prior study focused on clinicopathologic correlations with ODX RS, whereas the current study expanded on the past study by having a larger patient sampled, focusing on the identification of US imaging biomarkers for ODX RS, and developing and validating of a nomogram based on the US and clinicopathologic characteristics.

Patients who received treatment between May 2012 and December 2015 formed the training cohort, while those treated from January 2016 to January 2017 formed the independent validation cohort.

Clinicopathologic information collection

Clinicopathologic data were reviewed, including patients' age, pathologic information (histologic type, histologic grade), and immunohistochemical information (ER, PR, HER2, and Ki-67 index).

US scanning and image analysis

All patients underwent US scanning applied by multiple experienced radiologists (with more than 5 years of

experience and more than 500 breast US per year) following a standardized protocol before surgery in our department. The US machines used for the examinations were the RS85A (Samsung, Korea), IU22 (Philips, USA), EPIQ 7 (Philips, USA), and Logiq 9 (GE Healthcare, USA) with linear probes (3–12 MHz, centered at 10 MHz). High-resolution images of both the longitudinal and cross-sections were obtained in both grayscale and color Doppler US for feature analysis.

Eight US features taken from the Breast Imaging Reporting and Data System (BI-RADS) lexicon were evaluated. Including lesion type at US, shape, margin, orientation, lesion boundary, posterior echo pattern, vascularity, and calcification (Table S1). Independent image analysis was retrospectively performed by two board-certified radiologists (Y.L. and Y.G.) who were unaware of the clinicopathologic information and the ODX RS. In the case of disagreements between the two doctors, a third experienced radiologist's (Q.Z.) opinion was sought as the final outcome. Prior to taking part in the research, the radiologists underwent a comprehensive tutorial on the BI-RADS lexicon.

ODX 21-gene RS and study endpoints

Patients were subjected to the domestic Surexam 21-gene RS assay (SurExam Biotech; patent number: CN201010261745). The ODX assay uses a reverse transcriptase PCR on RNA isolated from paraffin-embedded breast cancer tissue to measure the activity of 21 genes (16 cancer-related, 5 references) and to determine the RS ranging from 0 to 100 (3). ODX RSs were obtained from ODX test reports. According to ODX RSs, the cases were classified as non-high risk (RS 0–25) or high risk (RS 26–100) in accordance with the TAILORx clinical trial results (5). High risk (RS \geq 26) was regarded as the endpoint.

Statistical analysis

Baseline characteristics were compared between training and validation cohorts with the Student's *t*-test (continuous data) and the Pearson chi-square test (categorical data). Univariate and multivariate logistic regression analyses were performed for all variables in the training cohort, P value was calculated using the likelihood ratio test, and variables with $P < 0.05$ were recognized as independent risk factors. The stepwise multivariable regression with backward elimination based on the Akaike information criterion (AIC)

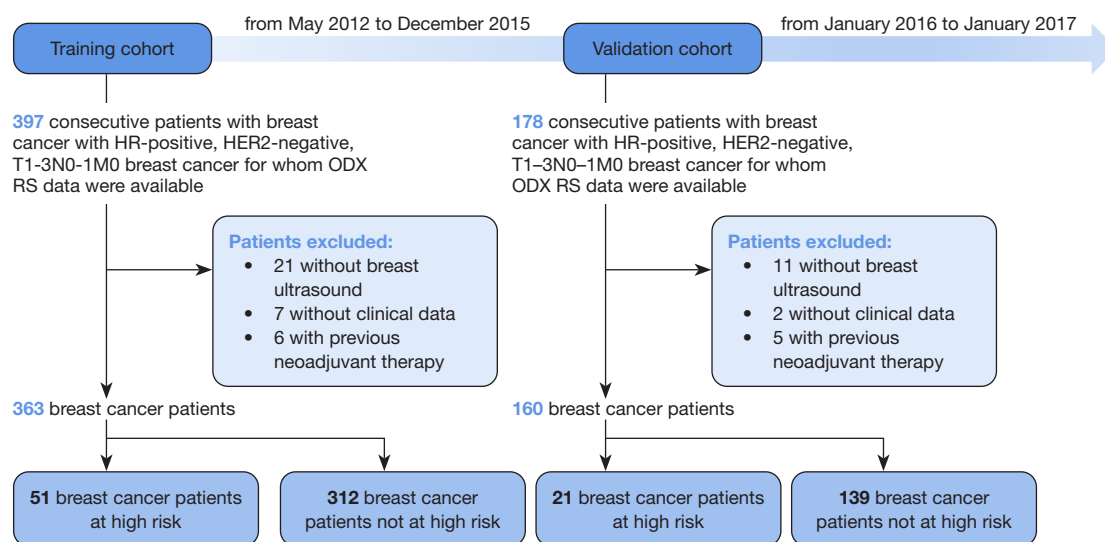


Figure 1 Flowchart of the study. HR, hormone receptor; HER2, human epidermal growth factor receptor 2; ODX, Oncotype DX; RS, recurrence score.

minimum was used to select variables for inclusion in the nomogram. Meanwhile, the variance inflation factor (VIF) was assessed among the covariates in the nomogram, and $VIF > 4.0$ was interpreted as indicating multicollinearity. Variables with $VIF > 4.0$ were not included in the final model analysis. A nomogram was built for predicting breast cancer with a high RS. The performance of the nomogram was assessed in terms of discrimination ability (AUC) and calibration (calibration plot). Decision curve analysis (DCA) is a method for evaluating the clinical benefit of alternative models and was applied to the nomogram by quantifying the net benefits at different threshold probabilities. The discrimination and calibration of the nomogram were then confirmed in the validation cohort. Interobserver agreement was assessed using the κ value, which was interpreted as follows: $\kappa < 0$, poor agreement; $0 < \kappa < 0.20$, slight agreement; $0.20 < \kappa < 0.40$, fair agreement; $0.40 < \kappa < 0.60$, moderate agreement; $0.60 < \kappa < 0.80$, substantial agreement; and $0.80 < \kappa < 1$, perfect agreement. All analyses were performed with R version 4.2.2 (The R Foundation for Statistical Computing) and SPSS version 20.0 (IBM Corp., USA) software packages.

Results

Baseline information of patients

A total of 523 patients with breast cancer were enrolled for inclusion and divided into a training cohort and a validation

cohort according to the time point of treatment (Figure 1). Accordingly, 363 patients (mean age 49 years; range, 17–78 years) treated between May 2012 and December 2015 formed the training cohort, and 160 patients (mean age 50 years; range, 28–69 years) treated between January 2016 and January 2017 formed the validation cohort. The rate of high RS for the training and validation cohort were 14% and 13.1%, respectively. The demographic and clinical characteristics of patients are summarized in Table 1.

Interobserver agreement for US imaging variables

The reproducibility of US image analysis demonstrated good interobserver agreement, with the specific κ values being the following: lesion type at US, 0.95; shape, 0.87; orientation, 0.92; margin, 0.91; lesion boundary, 0.80; posterior acoustic features, 0.90; calcification, 0.85; and vascularity:0.89.

Univariate analysis for the prediction of high RS

In the univariate regression analysis (Table 2), median histology grade [odds ratio (OR) =4.73; 95% confidence interval (95% CI): 1.42–15.82; $P=0.01$], high histology grade (OR =20.07; 95% CI: 5.26–76.52; $P<0.001$), lower level of ER (OR =0.98; 95% CI: 0.96–0.99; $P<0.001$), lower level of PR (OR =0.97; 95% CI: 0.97–0.98; $P<0.001$), and high Ki-67 index (OR =1.09; 95% CI: 1.07–1.12; $P<0.001$)

Table 1 Baseline information of patients in the training and validation cohorts

Characteristic	Training cohort (n=363)	Validation cohort (n=160)	P value
Age (years)*	48.91±9.45	49.52±8.79	0.48
Histologic type			0.17
IDC	315 (86.78)	148 (92.50)	
ILC	25 (6.89)	8 (5.00)	
Mixed (IDC + ILC)	6 (1.65)	0 (0.00)	
Others	17 (4.68)	4 (2.50)	
Grade			0.22
I	89 (24.52)	30 (18.75)	
II	240 (66.12)	118 (73.75)	
III	34 (9.37)	12 (7.50)	
Estrogen receptor [#]	90.0 (0.0–100.0)	90.0 (0.0–100.0)	<0.001
Progesterone receptor [#]	80.0 (0.0–100.0)	82.5 (0.0–99.0)	0.10
Ki-67 index [#]	15.0 (1.0–80.0)	20.0 (1.0–90.0)	0.02
US size (cm) *	1.92±0.90	1.83±0.88	0.32
Lesion type at US			0.91
Solid	336 (92.56)	149 (93.12)	
Cystic-solid	9 (2.48)	3 (1.88)	
Heterogeneous area	18 (4.96)	8 (5.00)	
Shape			0.91
Irregular	339 (93.39)	149 (93.12)	
Regular	24 (6.61)	11 (6.88)	
Margin			0.45
Vague	306 (84.30)	139 (86.88)	
Circumscribed	57 (15.70)	21 (13.12)	
Orientation			0.32
Parallel	297 (81.82)	125 (78.12)	
Not parallel	66 (18.18)	35 (21.88)	
Lesion boundary			0.048
Abrupt interface	250 (68.87)	96 (60.00)	
Echogenic halo	113 (31.13)	64 (40.00)	
Posterior echo pattern			0.95
No change	261 (71.90)	117 (73.13)	
Shadowing	49 (13.50)	20 (12.50)	
Enhanced	53 (14.60)	23 (14.37)	

Table 1 (continued)

Table 1 (continued)

Characteristic	Training cohort (n=363)	Validation cohort (n=160)	P value
Vascularity			0.002
No	18 (4.96)	10 (6.25)	
Abundant	217 (59.78)	69 (43.12)	
Few	128 (35.26)	81 (50.63)	
Calcification			0.99
No	188 (51.79)	83 (51.88)	
Microcalcification	175 (48.21)	77 (48.12)	
Number of the lesions at US			0.04
Single	307 (84.57)	146 (91.25)	
Multiple	56 (15.43)	14 (8.75)	

*, data are expressed as the mean \pm standard deviation; #, data are expressed as medians, with ranges in parentheses. Unless otherwise specified, data are numbers of patients, with percentages in parentheses. IDC, invasive ductal carcinoma; ILC, invasive lobular carcinoma; US, ultrasound.

Table 2 Univariable analysis of patients with high-risk breast cancer in the training cohort

Characteristic	Nonhigh risk (n=312)	High risk (n=51)	OR (95% CI)	P value
Age (years)*	49.03 \pm 9.33	48.20 \pm 10.19	0.99 (0.96–1.02)	0.56
US size (cm)*	1.87 \pm 0.91	2.21 \pm 0.81	1.41 (1.06–1.87)	0.02
Lesion type on US				
Solid	289 (92.63)	47 (92.16)	1	
Cystic-solid	7 (2.24)	2 (3.92)	1.76 (0.35–8.71)	0.49
Heterogeneous area	16 (5.13)	2 (3.92)	0.77 (0.17–3.45)	0.73
Shape				
Irregular	294 (94.23)	45 (88.24)	1	
Regular	18 (5.77)	6 (11.76)	2.18 (0.82–5.78)	0.12
Margin				
Vague	268 (85.90)	38 (74.51)	1	
Circumscribed	44 (14.10)	13 (25.49)	2.08 (1.03–4.22)	0.042
Orientation				
Parallel	250 (80.13)	47 (92.16)	1	
Not parallel	62 (19.87)	4 (7.84)	0.34 (0.12–0.99)	0.048
Lesion boundary				
Abrupt interface	226 (72.44)	24 (47.06)	1	
Echogenic halo	86 (27.56)	27 (52.94)	2.96 (1.62–5.40)	0.0004

Table 2 (continued)

Table 2 (continued)

Characteristic	Nonhigh risk (n=312)	High risk (n=51)	OR (95% CI)	P value
Posterior echo pattern				
No change	247 (79.17)	14 (27.45)	1	
Shadowing	43 (13.78)	6 (11.76)	2.46 (0.90–6.76)	0.08
Enhanced	22 (7.05)	31 (60.78)	24.86 (11.54–53.54)	<0.0001
Vascularity				
No	14 (4.49)	4 (7.84)	1	
Abundant	183 (58.65)	34 (66.67)	0.65 (0.20–2.10)	0.47
Few	115 (36.86)	13 (25.49)	0.40 (0.11–1.38)	0.15
Calcification				
No	166 (53.21)	22 (43.14)	1	
Yes	146 (46.79)	29 (56.86)	1.50 (0.82–2.72)	0.18
Number of lesions on US				
Single	266 (85.26)	41 (80.39)	1	
Multiple	46 (14.74)	10 (19.61)	1.41 (0.66–3.01)	0.37
Histologic type				
IDC	267 (85.58)	48 (94.12)	1	
ILC	24 (7.69)	1 (1.96)	0.23 (0.03–1.75)	0.16
Mixed (IDC + ILC)	5 (1.60)	1 (1.96)	1.11 (0.13–9.73)	0.92
Other	16 (5.13)	1 (1.96)	0.35 (0.05–2.68)	0.31
Grade				
I	86 (27.56)	3 (5.88)	1	
II	206 (66.03)	34 (66.67)	4.73 (1.42–15.82)	0.01
III	20 (6.41)	14 (27.45)	20.07 (5.26–76.52)	<0.001
Estrogen receptor [#]	90 (5–100)	80 (0–100)	0.98 (0.96–0.99)	<0.001
Progesterone receptor [#]	80 (0–100)	25 (0–95)	0.97 (0.97–0.98)	<0.001
Ki-67 index [#]	15 (1–80)	40 (5–80)	1.09 (1.07–1.12)	<0.001

*, data are expressed as the mean \pm standard deviation; #, data are expressed medians, with ranges in parentheses. Unless otherwise specified, data are expressed as numbers of patients, with percentages in parentheses. OR, odds ratio; CI, confidence interval; US, ultrasound; IDC, invasive ductal carcinoma; ILC, invasive lobular carcinoma.

were significantly associated with high RS. For US, US size (OR =1.41; 95% CI: 1.06–1.87; P=0.02), circumscribed margin (OR =2.08; 95% CI: 1.03–4.22; P=0.042), echogenic halo (OR =2.96; 95% CI: 1.62–5.40; P=0.0004), shadowing posterior echo (OR =2.46; 95% CI: 0.90–6.76; P=0.08), and enhanced posterior echo (OR =24.86; 95% CI: 11.54–53.54; P<0.0001) were associated with a high RS.

Comparison of multivariate models and nomogram development

In the multivariate analysis based on US imaging and clinicopathological factors, echogenic halo (OR =5.37; 95% CI: 1.88–15.30; P=0.002), enhanced posterior echo (OR =21.46; 95% CI: 7.03–65.48; P<0.001), low level of PR (OR

Table 3 Comparison of the multivariable models for high-risk breast cancer in the training cohort

Characteristic	Beta coefficient	OR (95% CI)	P value
Combined model			
US size	0.4514	1.57 (1.00–2.47)	0.051
Lesion boundary			
Abrupt interface	–	1	–
Echogenic halo	1.6804	5.37 (1.88–15.30)	0.002
Posterior echo pattern			
No change	–	1	–
Shadowing	1.3259	3.77 (0.97–14.60)	0.055
Enhanced	3.0663	21.46 (7.03–65.48)	<0.001
Histologic type			
IDC	–	1	–
ILC	–0.2617	0.77 (0.07–7.98)	0.83
Mixed (IDC + ILC)	1.5920	4.91 (0.40–60.03)	0.21
Other	–3.1085	0.04 (0.00–0.56)	0.02
Progesterone receptor	–0.0241	0.98 (0.96–0.99)	<0.001
Ki-67 index	0.1010	1.11 (1.07–1.15)	<0.001
Clinicopathological model			
Progesterone receptor	–0.0279	0.97 (0.96–0.98)	<0.001
Ki-67 index	0.0929	1.09 (1.07–1.12)	<0.001

OR, odds ratio; CI, confidence interval; US, ultrasound; IDC, invasive ductal carcinoma; ILC, invasive lobular carcinoma.

=0.98; 95% CI: 0.96–0.99; $P < 0.001$), and high Ki-67 index (OR =1.11; 95% CI: 1.07–1.15; $P < 0.001$) were identified as independent risk factors for a high RS. In the multivariate analysis based on clinicopathological variables, a low level of PR (OR =0.97; 95% CI: 0.96–0.98; $P < 0.001$) and a high Ki-67 index (OR =1.09; 95% CI: 1.07–1.12; $P < 0.001$) were independently associated with a high RS.

According to the stepwise multivariate regression (backward) results, US size, lesion boundary, posterior echo pattern, histologic type, PR, and Ki-67 index were selected for the combined model (Table 3), which had a minimal AIC value in the training cohort. The VIF values were all < 4 , indicating that no collinearity was present between screened variables. Similarly, PR status and Ki-67 index were included in the clinicopathological model (Table 3).

The combined model showed a better discrimination ability for predicting a high RS with a higher AUC of 0.95 (95% CI: 0.93–0.97) compared with the clinicopathological

model (AUC =0.89; 95% CI: 0.86–0.92) (Figure 2A). Consistently, the DCA curves revealed more clinical benefit for predicting a high RS of the combined model (Figure 2B). Both of the models were calibrated well (Figure 2C,2D).

According to the above results, we constructed a nomogram based on the combined model due to its better predictive ability (Figure 3). The 128 points were defined as the threshold, with a specificity of 93.6% (95% CI: 90.27–96.04%) and a sensitivity of 86.27% (95% CI: 73.74–94.30%).

Validation of the nomogram and performance in patients with T1N0M0 breast cancer

The good discrimination ability of the nomogram was observed in the validation cohort, with an AUC of 0.90 (95% CI: 0.84–0.94), and it was well calibrated (Figure 4). The clinical applicability of the nomogram for a low RS and high RS was observed in the representative examples, as

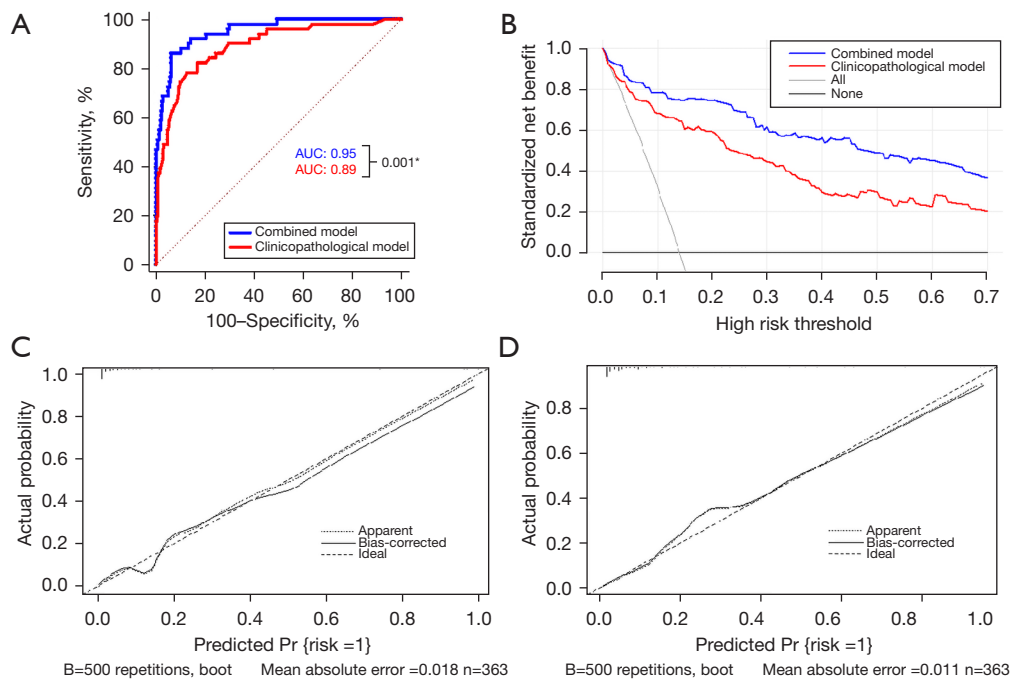


Figure 2 Performance of the combined model and clinicopathological model. (A) Receiver operating characteristic curves of the two models. (B) DCA for the two models. (C,D) Calibration curves of the combined model and clinicopathological model. *, there is a statistically significant difference between the AUCs of two models. AUC, area under the receiver operating characteristic curve; DCA, decision curve analysis.

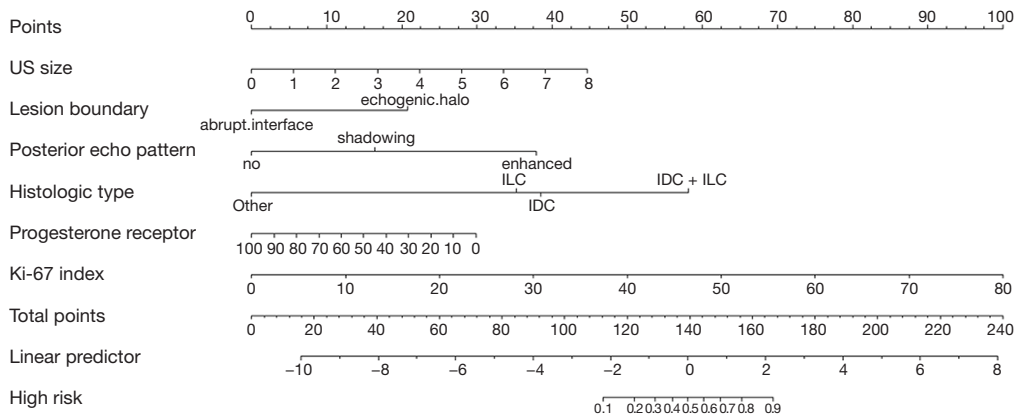


Figure 3 Nomogram for prediction of a high RS. US, ultrasound; ILC, invasive lobular carcinoma; IDC, invasive ductal carcinoma; RS, recurrence score.

shown in *Figures 5,6*.

We further explored the predictive ability of the nomogram in the patients with stage T1N0M0 breast cancer selected from the validation cohort (with a criterion of tumor size ≤ 2 cm being applied). Of the 107 patients, 15 (14.0%) were at high risk (mean RS 33). The nomogram

demonstrated good predictive power in patients with stage T1N0M0 disease, with an AUC of 0.91 (95% CI: 0.84–0.95) (*Figure 4*). This suggests that our model is helpful in identifying high-risk (RS ≥ 26) patients in a lower-risk population who would benefit from adjuvant chemotherapy after surgery.

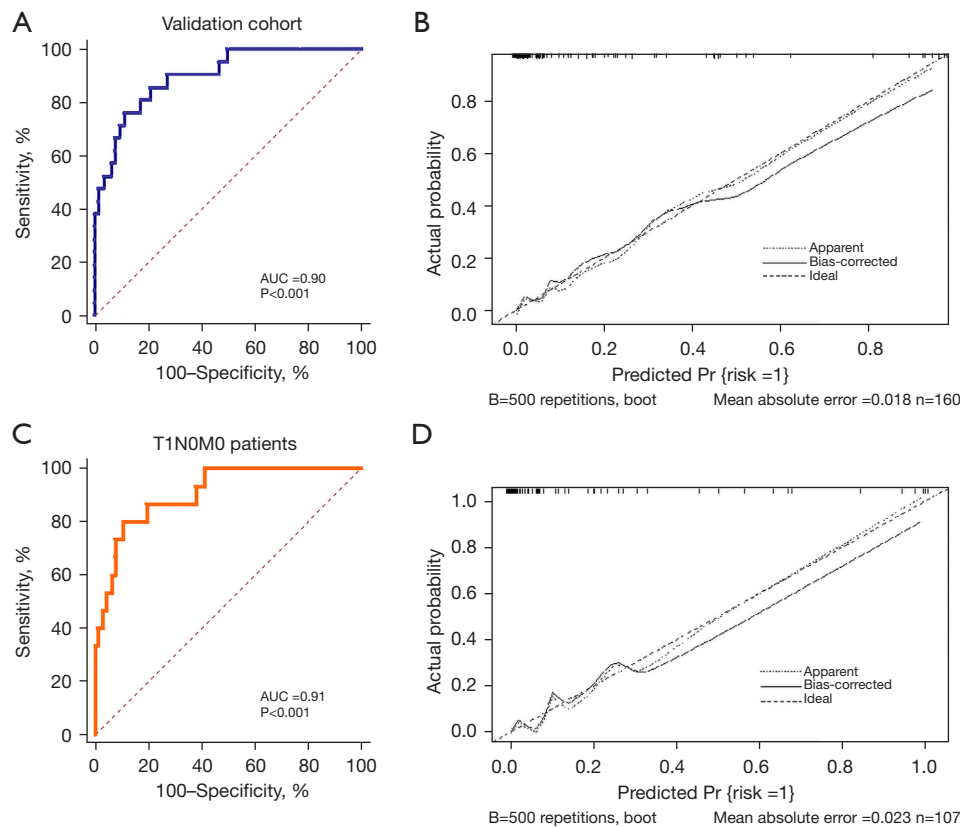


Figure 4 Validation of the nomogram in the (A,B) whole validation cohort and (C,D) patients with stage T1N0M0 breast cancer. AUC, area under the receiver operating characteristic curve.

Discussion

The identification of patients with HR-positive, HER2-negative, T1–3N0–1M0 stage breast cancer at high risk of recurrence (RS ≥ 26) is pivotal for devising adjuvant chemotherapy plans and improving outcomes for individuals. By incorporating clinicopathologic and US characteristics, we established and validated a reliable predictive nomogram for a high RS. The combined model, including US size, lesion boundary, posterior echo pattern, histologic type, PR, and Ki-67 index, achieved a better performance than did the clinicopathological model, yielding an AUC of 0.95 (95% CI: 0.93–0.97) in the training cohort and 0.90 (95% CI: 0.84–0.94) in the validation cohort. Additionally, calibration and DCA curves indicated that our nomogram predicted RS with good agreement and high potential clinical benefit. With 128 points as the risk stratification criterion, the evaluation effect could reach a sensitivity of 0.86, a specificity of 0.94, and an accuracy of 0.93. Previous studies have revealed the correlation

between ODX RS and clinical prognostic factors and have further developed several recurrence risk prediction models, with varying ranges in AUC (ranging from 0.81–0.92) and limited sensitivity (ranging from 14–62%) (16–20). Our study examined the added value of US imaging biomarkers and constructed a combined nomogram that possessed superior predictive effectiveness for identifying a high-risk population.

Furthermore, we validated our nomogram in patients with stage T1N0M0 breast cancer, achieving a good performance and an AUC of 0.91, indicating that the nomogram can be used to help identify a high-risk subgroup from a group of patients with very early-stage breast cancers—a subgroup that had not been previously evaluated separately. Adjuvant chemotherapy for stage I breast cancer has been discussed since the beginning of 1980s (21). In achieving a good prognosis for this group of patients, it is crucial to strike a balance between the benefits and side effects of chemotherapy. Investigators have aimed to fine-tune the treatment criteria and attempted to divided

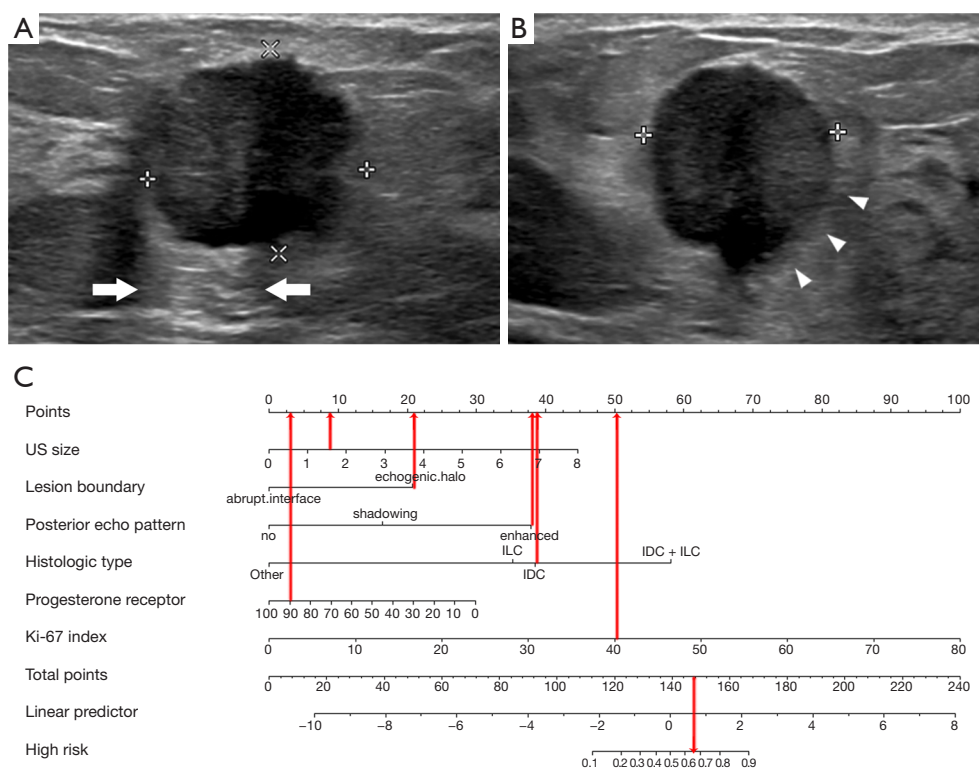


Figure 5 An example of the clinical use the nomogram for a high RS. Invasive ductal carcinoma (median grade, ER of 90%, PR of 90%, Ki-67 index of 40%) with a high ODX RS (35) in a 42-year-old woman. (A) Gray-scale ultrasound on longitudinal section showed a 1.6-cm (calipers) irregular nonparallel solid mass in the right lower outer breast, with an enhanced posterior echo (white arrow). (B) Gray-scale ultrasound on a cross-section of the 1.6-cm (calipers) mass with an echogenic halo (white triangle). (C) The nomogram indicated that after all points were summed ($8+21+38+39+3+38=147$), this case had a 62% probability of a high RS. According to our defined thresholds (128 points), the nomogram result was high risk. US, ultrasound; ILC, invasive lobular carcinoma; IDC, invasive ductal carcinoma; RS, recurrence score; ER, estrogen receptor; PR, progesterone receptor; ODX, Oncotype DX.

patients into high- and low-risk groups for accurately identifying target populations who would truly benefit from chemotherapy (22,23). It is widely acknowledged that adjuvant chemotherapy should not be administered for HR-positive, HER2-negative tumors except for those in very young women (aged <40 years). Molecular analysis in this patient category has been recommended for influencing the treatment recommendation (24). As ODX is the most widespread tool for genetic analysis, our study established a model for assessing ODX RS and achieved good results in this population. The model can help identify those patients at high risk and requiring adjuvant chemotherapy in a timely manner and facilitate precision treatment for patients.

Interestingly, our study provides the US imaging biomarkers for the prediction of high risk. Among the

various imaging features, enhanced posterior echo (OR =21.46; 95% CI: 7.03–65.48; $P<0.001$) and echogenic halo (OR =5.37; 95% CI: 1.88–15.30; $P=0.002$) showed the strongest association with a high RS. Previous studies have demonstrated that enhanced posterior echo is often observed in high-grade tumors, which is thought to be related to the increased mitotic rate and cell density, suggesting a more uniform internal structure and/or necrotic changes inside the tumor (25,26). Another study proposed posterior acoustic enhancements were associated with high-risk indicators of breast cancer, such as histological grade and negative ER (27). The findings of our study are in line with those of previous research, indicating a strong correlation between enhanced posterior echo and a high risk of recurrence and poor prognosis. With regard to echogenic halo, it is an US sign of infiltration, which

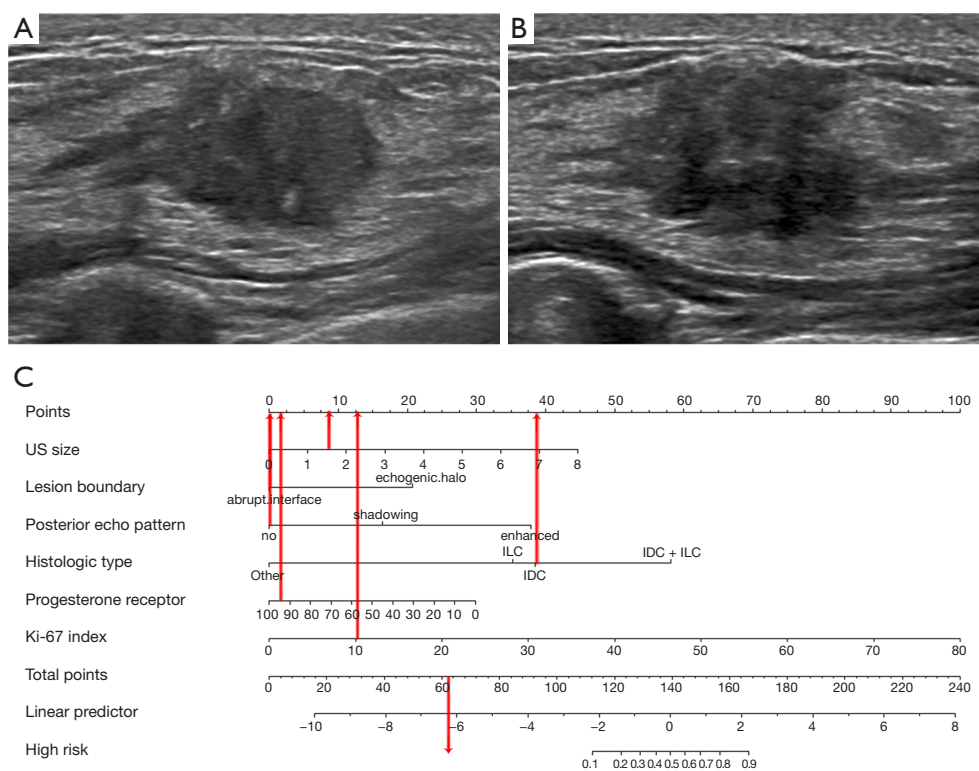


Figure 6 An example of the clinical use the nomogram for a low RS. Invasive ductal carcinoma (median grade, ER of 95%, PR of 95%, Ki-67 index of 10%) with a low ODX RS (18) in a 47-year-old woman. (A) Gray-scale ultrasound on longitudinal section showed a 1.6-cm irregular parallel solid mass in the right lower inner breast, without an echogenic halo and no change in posterior echo. (B) Gray-scale ultrasound on the cross-section of the mass. (C) The nomogram indicated that after all points were summed ($8+0+0+39+2+13=62$), the case had a less than 10% probability of a high RS. According to our defined thresholds (128 points), the result of nomogram was low risk. US, ultrasound; ILC, invasive lobular carcinoma; IDC, invasive ductal carcinoma; RS, recurrence score; ER, estrogen receptor; PR, progesterone receptor; ODX, Oncotype DX.

is considered to constitute histopathological evidence of tumor cell infiltration of fatty tissue, adipocytes, and elastic fibers (28). With the stretching by tumor cells extending out from a mass, early change manifest as increased collagen content and stiffness caused by tumor-cell infiltration into the stroma, which is known as *desmoplasia* (29,30). Our results suggest that echogenic halos maybe an indicator of a high RS. However, the value of the US biomarker for assessment of the survival status remains unclear, and the biological basis for the prognostic ability of imaging features warrant further research, to which our results can contribute.

There are some limitations to our study that should be mentioned. First, it was conducted at a single-center institution. Although we performed validation of the cases included at different times, further multicenter validation

needs to be carried out to establish generalizability and reproducibility. Second, the sample size of high-risk patients was limited, especially those with stage T1N0M0 disease, and thus our findings should be corroborated with a larger sample size. Finally, we employed a retrospective design, and the US images acquired from different US devices might have introduced variability in the image presentation. Although we could not compare the results among different devices due to the limited number of images, we used high-end US devices to acquire the high-quality images for the evaluation. Furthermore, imaging acquisition was performed by experienced radiologists following standardized protocol. As for the image analysis, two radiologists independently evaluated images and achieved a good consistency of assessment. The above measures helped to minimize the difference between the

various machines.

Conclusions

We demonstrated that certain US imaging biomarkers are associated with a high RS and can be combined with clinicopathological characteristics to develop a predictive tool for patients with breast cancer and a high RS. The combined nomogram can help to identify patients with at high risk of recurrence and those who would benefit most from chemotherapy, especially among patients with T1N0M0 disease.

Acknowledgments

Funding: This study was funded by the National Natural Science Foundation of China (No. 82171967) and National High Level Hospital Clinical Research Funding (No. 2022-PUMCH-B-066).

Footnote

Reporting Checklist: The authors have completed the TRIPOD reporting checklist. Available at <https://qims.amegroups.com/article/view/10.21037/qims-23-1620/rc>

Conflicts of Interest: All authors have completed the ICMJE uniform disclosure form (available at <https://qims.amegroups.com/article/view/10.21037/qims-23-1620/coif>). The authors have no conflicts of interest to declare.

Ethical Statement: The authors are accountable for all aspects of the work in ensuring that questions related to the accuracy or integrity of any part of the work are appropriately investigated and resolved. This study was conducted in accordance with the Declaration of Helsinki (as revised in 2013) and approved by the Ethics Committee of the Peking Union Medical College Hospital (No. K3032). The requirement of individual consent for this retrospective analysis was waived.

Open Access Statement: This is an Open Access article distributed in accordance with the Creative Commons Attribution-NonCommercial-NoDerivs 4.0 International License (CC BY-NC-ND 4.0), which permits the non-commercial replication and distribution of the article with the strict proviso that no changes or edits are made and the original work is properly cited (including links

to both the formal publication through the relevant DOI and the license). See: <https://creativecommons.org/licenses/by-nc-nd/4.0/>.

References

- Loibl S, Poortmans P, Morrow M, Denkert C, Curigliano G. Breast cancer. *Lancet* 2021;397:1750-69.
- Siegel RL, Miller KD, Wagle NS, Jemal A. Cancer statistics, 2023. *CA Cancer J Clin* 2023;73:17-48.
- Paik S, Shak S, Tang G, Kim C, Baker J, Cronin M, Baehner FL, Walker MG, Watson D, Park T, Hiller W, Fisher ER, Wickerham DL, Bryant J, Wolmark N. A multigene assay to predict recurrence of tamoxifen-treated, node-negative breast cancer. *N Engl J Med* 2004;351:2817-26.
- Paik S, Tang G, Shak S, Kim C, Baker J, Kim W, Cronin M, Baehner FL, Watson D, Bryant J, Costantino JP, Geyer CE Jr, Wickerham DL, Wolmark N. Gene expression and benefit of chemotherapy in women with node-negative, estrogen receptor-positive breast cancer. *J Clin Oncol* 2006;24:3726-34.
- Sparano JA, Gray RJ, Makower DF, Pritchard KI, Albain KS, Hayes DF, et al. Adjuvant Chemotherapy Guided by a 21-Gene Expression Assay in Breast Cancer. *N Engl J Med* 2018;379:111-21.
- Gradishar WJ, Moran MS, Abraham J, Aft R, Agnese D, Allison KH, et al. NCCN Guidelines® Insights: Breast Cancer, Version 4.2021. *J Natl Compr Canc Netw* 2021;19:484-93.
- Andre F, Ismaila N, Henry NL, Somerfield MR, Bast RC, Barlow W, Collyar DE, Hammond ME, Kuderer NM, Liu MC, Van Poznak C, Wolff AC, Stearns V. Use of Biomarkers to Guide Decisions on Adjuvant Systemic Therapy for Women With Early-Stage Invasive Breast Cancer: ASCO Clinical Practice Guideline Update-Integration of Results From TAILORx. *J Clin Oncol* 2019;37:1956-64.
- Lashen A, Toss MS, Fadhil W, Oni G, Madhusudan S, Rakha E. Evaluation oncotype DX(®) 21-gene recurrence score and clinicopathological parameters: a single institutional experience. *Histopathology* 2023;82:755-66.
- Chen Y, Tang W, Liu W, Li R, Wang Q, Shen X, Gong J, Gu Y, Peng W. Multiparametric MR Imaging Radiomics Signatures for Assessing the Recurrence Risk of ER+/HER2- Breast Cancer Quantified With 21-Gene Recurrence Score. *J Magn Reson Imaging*

- 2023;58:444-53.
10. Galati F, Magri V, Moffa G, Rizzo V, Botticelli A, Cortesi E, Pediconi F. Precision Medicine in Breast Cancer: Do MRI Biomarkers Identify Patients Who Truly Benefit from the Oncotype DX Recurrence Score(®) Test? *Diagnostics* (Basel) 2022.
 11. Yin XX, Hadjiloucas S, Zhang Y, Tian Z. MRI radiogenomics for intelligent diagnosis of breast tumors and accurate prediction of neoadjuvant chemotherapy responses—a review. *Comput Methods Programs Biomed* 2022;214:106510.
 12. Park YH, Senkus-Konefka E, Im SA, Pentheroudakis G, Saji S, Gupta S, et al. Pan-Asian adapted ESMO Clinical Practice Guidelines for the management of patients with early breast cancer: a KSMO-ESMO initiative endorsed by CSCO, ISMPO, JSMO, MOS, SSO and TOS. *Ann Oncol* 2020;31:451-69.
 13. Yepes MM, Romilly AP, Collado-Mesa F, Net JM, Kiszonas R, Arheart KL, Young D, Glück S. Can mammographic and sonographic imaging features predict the Oncotype DX™ recurrence score in T1 and T2, hormone receptor positive, HER2 negative and axillary lymph node negative breast cancers? *Breast Cancer Res Treat* 2014;148:117-23.
 14. Chae EY, Moon WK, Kim HH, Kim WH, Cha JH, Shin HJ, Choi WJ, Han W, Noh DY, Lee SB, Ahn SH. Association between Ultrasound Features and the 21-Gene Recurrence Score Assays in Patients with Oestrogen Receptor-Positive, HER2-Negative, Invasive Breast Cancer. *PLoS One* 2016;11:e0158461.
 15. Youk JH, Son EJ, Jeong J, Gweon HM, Eun NL, Kim JA. Shear-wave elastography-based nomograms predicting 21-gene recurrence score for adjuvant chemotherapy decisions in patients with breast cancer. *Eur J Radiol* 2023;158:110638.
 16. Zhang Y, Zhou Y, Mao F, Yao R, Sun Q. Ki-67 index, progesterone receptor expression, histologic grade and tumor size in predicting breast cancer recurrence risk: A consecutive cohort study. *Cancer Commun (Lond)* 2020;40:181-93.
 17. Kim MC, Kwon SY, Choi JE, Kang SH, Bae YK. Prediction of Oncotype DX Recurrence Score Using Clinicopathological Variables in Estrogen Receptor-Positive/Human Epidermal Growth Factor Receptor 2-Negative Breast Cancer. *J Breast Cancer* 2023;26:105-16.
 18. Orucevic A, Bell JL, McNabb AP, Heidel RE. Oncotype DX breast cancer recurrence score can be predicted with a novel nomogram using clinicopathologic data. *Breast Cancer Res Treat* 2017;163:51-61.
 19. Orucevic A, Bell JL, King M, McNabb AP, Heidel RE. Nomogram update based on TAILORx clinical trial results - Oncotype DX breast cancer recurrence score can be predicted using clinicopathologic data. *Breast* 2019;46:116-25.
 20. Yoo SH, Kim TY, Kim M, Lee KH, Lee E, Lee HB, Moon HG, Han W, Noh DY, Han SW, Kim TY, Im SA. Development of a Nomogram to Predict the Recurrence Score of 21-Gene Prediction Assay in Hormone Receptor-Positive Early Breast Cancer. *Clin Breast Cancer* 2020;20:98-107.e1.
 21. National Cancer Institute. Clinical alert. Bethesda, Md.: National Cancer Institute, May 16–18, 1988.
 22. Boyages J, Taylor R, Chua B, Ung O, Bilous M, Salisbury E, Wilcken N. A risk index for early node-negative breast cancer. *Br J Surg* 2006;93:564-71.
 23. Dignam JJ, Dukic V, Anderson SJ, Mamounas EP, Wickerham DL, Wolmark N. Hazard of recurrence and adjuvant treatment effects over time in lymph node-negative breast cancer. *Breast Cancer Res Treat* 2009;116:595-602.
 24. Schwartz GF, Reis-Fihlo J, Pusztai L, Fentiman IS, Holland R, Bartelink H, Rutgers EJ, Solin LJ, Palazzo J; . Adjuvant therapy in stage I carcinoma of the breast: the influence of multigene analyses and molecular phenotyping. *Cancer* 2012;118:2031-8.
 25. Irshad A, Leddy R, Pisano E, Baker N, Lewis M, Ackerman S, Campbell A. Assessing the role of ultrasound in predicting the biological behavior of breast cancer. *AJR Am J Roentgenol* 2013;200:284-90.
 26. Tong YY, Sun PX, Zhou J, Shi ZT, Chang C, Li JW. The Association Between Ultrasound Features and Biological Properties of Invasive Breast Carcinoma Is Modified by Age, Tumor Size, and the Preoperative Axilla Status. *J Ultrasound Med* 2020;39:1125-34.
 27. Shin HJ, Kim HH, Huh MO, Kim MJ, Yi A, Kim H, Son BH, Ahn SH. Correlation between mammographic and sonographic findings and prognostic factors in patients with node-negative invasive breast cancer. *Br J Radiol* 2011;84:19-30.
 28. Zhang L, Li J, Xiao Y, Cui H, Du G, Wang Y, Li Z, Wu T, Li X, Tian J. Identifying ultrasound and clinical features of breast cancer molecular subtypes by ensemble decision. *Sci Rep* 2015;5:11085.
 29. Itoh A, Ueno E, Tohno E, Kamma H, Takahashi H, Shiina T, Yamakawa M, Matsumura T. Breast disease: clinical

- application of US elastography for diagnosis. *Radiology* 2006;239:341-50.
30. Conklin MW, Eickhoff JC, Riching KM, Pehlke CA,

Eliceiri KW, Provenzano PP, Friedl A, Keely PJ. Aligned collagen is a prognostic signature for survival in human breast carcinoma. *Am J Pathol* 2011;178:1221-32.

Cite this article as: Luo Y, Gao Y, Niu Z, Zhang J, Liu Z, Zhang Y, Shen S, Jiang Y, Xiao M, Zhu Q. The added value of ultrasound imaging biomarkers to clinicopathological factors for the prediction of high-risk Oncotype DX recurrence scores in patients with breast cancer. *Quant Imaging Med Surg* 2024;14(5):3519-3533. doi: 10.21037/qims-23-1620