

# Saradhi's single stage, anterior sequential reduction utilizing C3 for type III hangman's fracture: A novel technique

## ABSTRACT

**Background:** Levine Edward's Type III Hangman's fractures are highly unstable and in absence of level 1 evidence, the treatment is individualized. A longer cantilever beam can achieve not just reduction of highly displaced fragments but can also provide a stable construct without the need of global instrumentation.

**Objective:** We extrapolated the surgical techniques of the long cantilever beam to this rare group of cohorts for anterior alone, sequential reduction utilizing C3 rather than sacrificing in a single sitting and single approach.

**Materials and Methods:** This is a prospective observational study from 2015 to 2019, of all consecutive 10 patients diagnosed and treated as Type III Hangman's fracture in the Department of Neurosurgery. Clinical evaluation and pain scores were recorded in the preoperative assessment. Radiological investigations included plain roentgenograms in anterior-posterior and lateral views, magnetic resonance imaging, and computed tomography scan of the cervical spine. Preoperative cervical traction was placed in all cases for the achievement of facet reduction. The high cervical extra-pharyngeal approach was utilized for discectomy, bone grafting, reduction, and sequential plating.

**Results:** Complete reduction was achieved in all the cases and none required additional posterior surgery. There was a significant decrease in axial neck pain with complete fusion of the graft, and healing of fracture site.

**Conclusion:** The anterior alone approach with a longer cantilever for primary internal stabilization is a technically safe and suitable option for unstable Type III Hangman's fracture.

**Keywords:** Fixation, fusion, Hangman's fracture, longer cantilever, Sequential reduction

## INTRODUCTION

Traumatic spondylolisthesis of axis (TAS) was first described in 1866 for bilateral pars fracture of C2 and was termed "Hangman's fracture" nearly a century later in 1965.<sup>[1,2]</sup> The fracture which was originally described in cases following judicial hangings by Woods Jones (1913) was designed and described to be fatal, is currently observed following vehicular accidents nonetheless without a neurological deficit except neck pain and restricted mobility.<sup>[3,4]</sup> The controversy starts with its nomenclature (Hangman's vs. Hanged man's fracture vs. Hangee's fractures), proceeds through the mechanism of injury, management options such as conservative versus operative, anterior versus posterior

versus global, and additional permutations and combinations of C3 corpectomy.<sup>[5]</sup> However, amid these controversies, there is consensus that unstable fractures are better treated

**VIJAYA SARADHI MUDUMBA, S. PAVAN, RAJESH ALUGOLU**

Department of Neurosurgery, Nizam's Institute of Medical Sciences, Hyderabad, Telangana, India

**Address for correspondence:** Dr. Rajesh Alugolu, Department of Neurosurgery, Nizam's Institute of Medical Sciences, Punjagutta, Hyderabad - 500 082, Telangana, India. E-mail: drarajesh1306@gmail.com

**Submitted:** 14-Jun-21


**Accepted:** 29-Nov-21

**Published:** 09-Mar-22

This is an open access journal, and articles are distributed under the terms of the Creative Commons Attribution-NonCommercial-ShareAlike 4.0 License, which allows others to remix, tweak, and build upon the work non-commercially, as long as appropriate credit is given and the new creations are licensed under the identical terms.

**For reprints contact:** WKHLRPMedknow\_reprints@wolterskluwer.com

**How to cite this article:** Mudumba VS, Pavan S, Alugolu R. Saradhi's single stage, anterior sequential reduction utilizing C3 for type III hangman's fracture: A novel technique. J Craniovert Jun Spine 2022;13:80-4.

Access this article online	
<b>Website:</b> www.jcvjs.com	<b>Quick Response Code</b> 
<b>DOI:</b> 10.4103/jcvjs.jcvjs_83_21	

by surgical fixation. There has been a constant evolution in techniques, each one learning from previous experiences and building on to give simple and safe surgical options/results for these nonfatal fractures.

### Aim of the study

This study aims to determine the operative feasibility and outcomes of single-stage anterior approaches in cases of highly unstable (Levine-Edward's Type III) Hangman's fractures.

## MATERIALS AND METHODS

This is a technical note and analysis of all cases of unstable (Levine-Edward's Type III) Hangman's fractures treated from March 2015 to November 2019 with surgical intervention at the Department of Neurosurgery, Nizam's Institute of Medical Sciences, Hyderabad. All cases were evaluated clinically and radiologically. Translation and angulation of C2 over C3 were measured on plain roentgenograms taken before the placement of traction. While the patient was on traction, X-rays were performed to confirm the degree of reduction. These imaging studies were however done in the supine position. Computed tomography of the cervical spine was also performed to identify the direction of the fracture line, the pedicle dimensions, and any possible rotational component of the axis. Magnetic resonance imaging (MRI) cervical spine was performed to assess disco-ligamentous complex injury at C2-C3.

### Exclusion criteria

Combined fractures of C1-C2, Hangman's fractures Type I, II, and other high cervical fractures were excluded from the study.

### Surgical technique

The definition of the Type III Hangman's fracture in our study is based on Levine-Edward's classification [Figure 1].

- Step 1: Patients were placed on cervical traction in mild extension, starting at 2 kg with sequential increase till adequate reduction was achieved. Although the facets got realigned in all these patients, the subluxation, angulation of C2, and retro luxation of C3 persisted
- Step 2: Nasal intubation was done in all cases as it allowed an extra exposure of 5 mm in the region without additional pressure on the airways
- Step 3: A standard high cervical extra-pharyngeal approach was used, with an oblique incision made midway between the angle of the jaw and the thyroid cartilage
- Step 4: Anterior cervical discectomy at the C2-3 level was followed by placement of an autologous, tricorticate iliac bone graft used for bony fusion

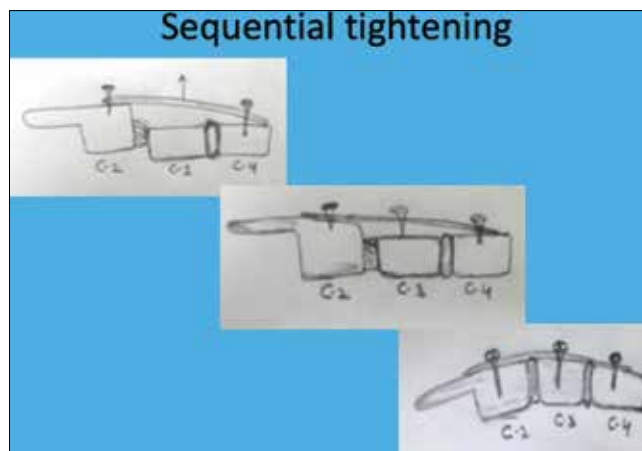


Figure 1: Pictorial diagram of the Sequential reduction technique showing steps 6, 7 and 8

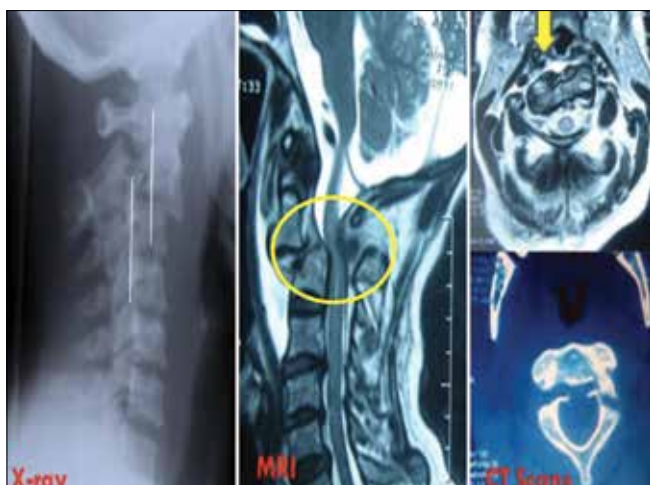- Step 5: Long cervical plate (Zephyre system, Medtronic India Inc.) covering from C2 to C4 was selected
- Step 6: A screw, threaded half into the body at C2 and C4 were placed in diagonally opposite slots to stabilize and keep in the plate at the required site [Figures 2 and 3]
- Step 7: Screws were placed in both the slots available over C3 to the full depth with a gentle but firm traction with an intent to pull the body up against the posterior border of the plate. The reduction was confirmed on lateral roentgenogram intra-operatively
- Step 8: Partially threaded screws of C2 and C4 were deepened to the full extent. Other slots for C2 and C4 were also threaded [Figures 2 and 3]

The C4 which is in continuation with the rest of the caudal spine and also with retroflexed C3, helps C3 (Saradhi-Sanskrit-a charioteer helping the archer, incidentally is the name of the senior author) to achieve acceptable re-alignment thus avoiding corpectomy of C3.

## RESULTS

The total number of patients with Type III Hangman's fracture treated in the department from 2015 to 2018 was 10. Among them, 9 had sustained the injury in a road traffic accident while one was due to fall from height. The gender distribution was (male: female: 9:1), and age ranged from 18 to 60 years. All patients presented with neck pain and restricted movements of the neck. None of the patients had any focal neurological deficits.

All these cases were operated by the senior author (MVS). The mean operating time was 3 h. Patients recovered well after surgery with no neurological deficits in the postoperative period. All cases were followed for an average period of




**Figure 2:** The typical Hangman's fracture Type III. X ray showing Fracture with anterior subluxation C2 over C3 with locked facets. Magnetic resonance imaging and computed tomography showing gross translation, angulation and axial rotation. Note the posterior and superior part of C3 impinging on theca sac; (arrow yellow- showing the disrupted anterior longitudinal ligament with collection)

1 year. Neck pain subsided in all the patients and solid bony fusion was achieved in all cases with index case showing the same after 6 months [Figure 4]. No complications were observed in any of the cases during the follow-up period.

## DISCUSSION

Levine-Edward's type III Hangman's Fractures are highly unstable fractures characterized by a high degree of translation, angulation, rotation, discal injury with disruption of supportive ligaments. The hyperextension causes fracture of the pars and whilst associated flexion-distraction causes angulation, rotation, and ligamentous injury. The surgical strategies for the Hangman's fractures are varied and range from halo traction to the anterior alone, posterior alone, and global (anterior-posterior) approaches depending upon the extent of injury and degree of instability.<sup>[4-7]</sup>

All classification schemes (Effendi, Levine, Francis, Goel) claim to provide a statement about stability.<sup>[3-5,8,9]</sup> They however, are all based on static radiographs and hence do not assess the disco-ligamentous complex at C2-3 disc, ALL, and PLL.<sup>[8,10]</sup> The MRI features of the instability of these fractures include significant angulation between C2-3  $\geq 11^\circ$ , significant translation of C2-3  $\geq 3.5$  mm, teardrop fragment endplate C2 or C3 (bony avulsion of ALL), disc rupture/edema (MRI), hyper lordotic angulation C2-3 (Dynamic X-ray in extension).<sup>[8]</sup> The main morphological feature of the Type III Hangman fracture is the retro pulsed C3 body impinging on the cord. The C3 body however, remains structurally intact in these fractures except the fact that it is retropulsed.



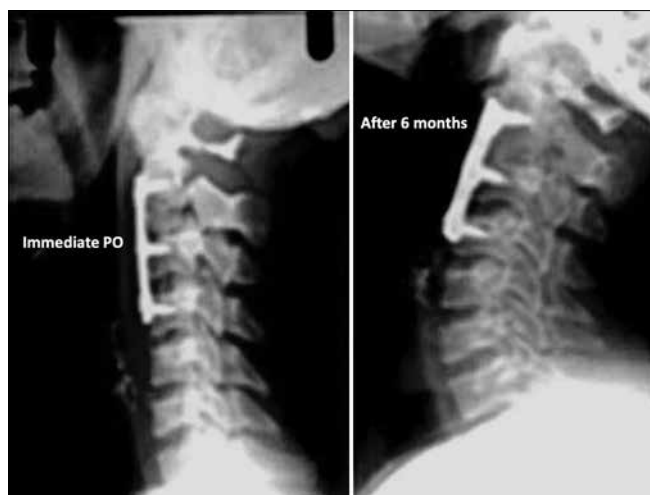**Figure 3:** Sequential tightening of screws on the plate. Upper holes A and B middle holes C and D lower holes E and F The sequence of inserting screws is as follows A F C B E and D. This final D will pull up the fragment totally to the plate with resulting fixation

## Role of halo fixation

The traditional halo application has a satisfactory outcome in type I and type II type of fractures wherein the displacement and angulation are minimal with preserved facet alignment.<sup>[1-4]</sup> Usually, type I heal with collar immobilization as they are usually stable fractures. Type II and IIa need prior cervical traction for re-alignment and can be followed by halo immobilization. Until quite recently, non-surgical treatments were advocated as the primary management of a Hangman's fracture, even in the presence of instability.<sup>[3]</sup> However, type III fractures are highly unstable, involving all three columns, and not quite maintainable in reduced position with halo immobilization alone and require internal fixation.<sup>[5-7]</sup> Hangman's fractures which were managed conservatively with halo immobilization had fusion rates of nearly 100% in type I, 60% in type II, 45% in type IIa, and 35% in type III.<sup>[4,7,11,12]</sup> The incidence of pseudoarthrosis reported with halo in highly unstable fractures is about 35%.<sup>[12,13]</sup> Li *et al.* pointed out in their systematic review that conservative treatment decreased sequentially from Levine-Edward's type I to III fractures.<sup>[4]</sup>

## Posterior approaches

The posterior approaches though offer good fixation have inherent limitations and requisitions. Posterior surgery for Hangman's fractures includes C2 pars or C2-C3 lateral mass or C1-C3 fixations. The desired prerequisites for pars screw fixation include a complete reduction and approximation of fracture gap to  $< 3$  mm, and intact anterior longitudinal ligament before the insertion of C2 screw. This fixation of C1-C2/C3 restricts the rotatory movement of the neck at C1-C2.<sup>[14-16]</sup> Duggal *et al.* in their biomechanical study concluded that the pars screw does not offer enough



**Figure 4: X-Ray cervical spine a patient immediately after surgery (postoperative) (left) and after 6 months (right) in the same patient showing solid fusion**

stability in type II fractures and it must be supplemented with C3 lateral mass.<sup>[10]</sup> Posterior procedures have their inherent disadvantage of persistent dorsal pain and limited rotation of C1-2 and inability to tackle the disrupted disc.<sup>[10,17]</sup> Catastrophic results have been reported while passing C2 pars screws with gap of 4 mm.<sup>[16,17]</sup> Verheggen *et al.* published their cases where they used pars screws in Hangman's type II with good outcomes.<sup>[18]</sup> Besides, this approach does not address the anterior disc pathology which is the usual accompaniment in these fractures. ElMiligui *et al.* achieved an excellent clinical outcome in 15 consecutive patients of the trans-pedicular screw with motion preservation in Type II Hangman's fractures.<sup>[19]</sup> Goel *et al.* in their analysis of 15 cases of Hangman's elucidated the complex nature of the problem at hand numerous options through posterior approach in stabilizing the spine.<sup>[9]</sup> Shah *et al.* described successful posterior approach even in a 7-year-old with osteopetrosis.<sup>[20]</sup>

### Posterior plus approaches

Usually, the posterior approaches are part of combined two-staged anteroposterior (AP) or three staged anterior-posterior-anterior (APA) surgeries.<sup>[8,11,18]</sup> Srivatsava *et al.* in their case of neglected type III fractures performed anterior C2-3 fusion followed by posterior fixation with excellent results.<sup>[21]</sup> In the literature, most of the reports of type III fractures are managed by global fusion to achieve good reduction and stabilization. There were sporadic case reports of surgical treatment of type III fractures which usually require long segment fusion like posterior C1-C3.<sup>[22]</sup> Mudumba *et al.* treated a case of double Hangman fracture with global fixation after their initial failed attempt with short cantilever, anterior alone approach with an excellent outcome.<sup>[23]</sup>

### Anterior approaches

The two main anterior procedures that are described for Hangman's III fractures are the (a) conventional C2-3 fusion and (b) C3 corpectomy with anterior C2-4 plating. The former procedure is usually enough for type II fractures. Anterior procedures comprising only of C2-3 plating for Type III are associated with significant nonreduction and persistence of deformity which necessitated global fusion (A-P procedure).<sup>[6,7]</sup> APA surgeries have been reported to achieve adequate reduction in these highly unstable fractures.<sup>[6,7,11]</sup> Zhonghai *et al.* described C3 corpectomy for type III Hangman's fractures.<sup>[5]</sup> Li *et al.* in their systematic review of unstable Hangman's fractures stated that when there is compression from the posterosuperior part of the body of C3, a motion-preserving procedure may not be a viable option.<sup>[4]</sup> Arand *et al.*, strongly recommended anterior surgery following disruption of C2-3 disc.<sup>[24]</sup> Jain *et al.* in their series of 44 patients utilized the anterior C2-3 fixation alone, majority being type II with only 3 cases of type III Hangman's fracture.<sup>[25]</sup> The unequivocal supremacy of anterior approaches has been well recorded with regards to postoperative pain, neck mobility, and overall satisfaction with neck status in patients treated with the anterior approach. If decompression of the cord and nerve roots is required for neurological recovery, anterior C-3 corpectomy should be performed.<sup>[26]</sup>

The persistence of angulations and incomplete reduction following surgery is associated with significant neck pain in the long-term follow-up.<sup>[7,15,27]</sup> We on the contrary are of the belief that the innocent C3 can not only be spared but can be used for a stable construct. Chittaboina *et al.*, in their biomechanical evaluation of various constructs of Hangman's fractures opined that anterior fixation is strong enough for these lesions.<sup>[17]</sup>

### Why C2-C3-C4 and not just C2-C3?

Apart from the fracture of pars, in type III Hangman's fracture, there is disruption of strong anterior longitudinal ligament, disc, posterior longitudinal ligament along with retropulsion of near-normal C3 body. The posterior cervical muscles and ligaments though contused are relatively preserved with intact attachments to the bony surfaces and posterior elements.

Mere C2-3 fixation may address the disc fragment impinging on the cord, but it fails to achieve a complete reduction of neural compression of C3 resulting in abnormal curvature and biomechanical load with high chances of persistent neck pain, pseudoarthrosis, implant failure, and thus poor functional outcome.

To address the issue of incomplete reduction with C2-3 fixation, we included the C4, the lower additional segment, and thus, a longer cantilever to achieve perfect reduction. By engaging and tightening screws, sequentially the C3 is pulled back along with the continuous caudal spine column. C4 helps C3 attain its near-normal position.

In nutshell - (1) single-stage, (2) anterior approach, (3) useful in disrupted ALL, PLL and disc, (4) potential to correct the kyphotic angle, (5) conserves C3, (6) stable construct.

### Limitations

The pain assessment was subjective and no scoring system was utilized. The range of motion across the segments was not assessed and may be studied in a prospective manner.

### CONCLUSION

A single-stage, anterior approach with a long construct from C2 to C4, and utilizing the C3, in achieving the sequential reduction of the displaced spinal alignment, is a simple, safe, and stable biomechanical construct for Type III Hangman's fracture.

### Financial support and sponsorship

Nil.

### Conflicts of interest

There are no conflicts of interest.

### REFERENCES

- Vieweg U, Schultheiss R. A review of halo vest treatment of upper cervical spine injuries. *Arch Orthop Trauma Surg* 2001;121:50-5.
- Coric D, Wilson JA, Kelly DL Jr. Treatment of traumatic spondylolisthesis of the axis with nonrigid immobilization: A review of 64 cases. *J Neurosurg* 1996;85:550-4.
- Vaccaro AR, Madigan L, Bauerle WB, Blescia A, Cotler JM. Early halo immobilization of displaced traumatic spondylolisthesis of the axis. *Spine (Phila Pa 1976)* 2002;27:2229-33.
- Li XF, Dai LY, Lu H, Chen XD. A systematic review of the management of Hangman's fractures. *Eur Spine J* 2006;15:257-69.
- Li Z, Li F, Hou S, Zhao Y, Mao N, Hou T, *et al.* Anterior discectomy/corpectomy and fusion with internal fixation for the treatment of unstable Hangman's fractures: A retrospective study of 38 cases. *J Neurosurg Spine* 2015;22:387-93.
- Liu J, Li Y, Wu Y. One-stage posterior C2 and C3 pedicle screw fixation or combined anterior C2-C3 fusion for the treatment of unstable Hangman's fracture. *Exp Ther Med* 2013;5:667-72.
- Xie N, Khoo LT, Yuan W, Ye XJ, Chen DY, Xiao JR, *et al.* Combined anterior C2-C3 fusion and C2 pedicle screw fixation for the treatment of unstable Hangman's fracture: A contrast to anterior approach only. *Spine (Phila Pa 1976)* 2010;35:613-9.
- Schleicher P, Scholz M, Pingel A, Kandziora F. Traumatic spondylolisthesis of the axis vertebra in adults. *Global Spine J* 2015;5:346-58.
- Goel A, Hawaldar A, Shah A, Bhambere S, Lunawat A, Singh M, *et al.* Hangman's fracture: A clinical review based on surgical treatment of 15 cases. *Neurosurg Rev* 2021. [published online ahead of print, 2021 May 31].
- Duggal N, Chamberlain RH, Perez-Garza LE, Espinoza-Larios A, Sonntag VK, Crawford NR. Hangman's fracture: A biomechanical comparison of stabilization techniques. *Spine (Phila Pa 1976)* 2007;32:182-7.
- Scholz M, Kandziora F, Kobbe P, Matschke S, Schleicher P, Josten C, *et al.* Treatment of axis ring fractures: Recommendations of the spine section of the German Society for Orthopaedics and Trauma (DGOU). *Global Spine J* 2018;8:18S-24S.
- Shin JJ, Kim SH, Cho YE, Cheshier SH, Park J. Primary surgical management by reduction and fixation of unstable Hangman's fractures with discoligamentous instability or combined fractures: Clinical article. *J Neurosurg Spine* 2013;19:569-75.
- Montalbano M, Fisahn C, Loukas M, Oskouian RJ, Chapman JR, Tubbs RS. Pediatric Hangman's fracture: A comprehensive review. *Pediatr Neurosurg* 2017;52:145-50.
- Horn EM, Hott JS, Porter RW, Theodore N, Papadopoulos SM, Sonntag VK. Atlantoaxial stabilization with the use of C1-3 lateral mass screw fixation. Technical note. *J Neurosurg Spine* 2006;5:172-7.
- Muthukumar N. C1-C3 lateral mass fusion for type IIa and type III Hangman's fracture. *J Craniovertebr Junction Spine* 2012;3:62-6.
- Kovari VZ, Josvai A, Csokay A. Transpedicular direct osteosynthesis of Hangman's fracture from a mini-open exposure as a less invasive procedure: A technical note. *Trauma Case Rep* 2017;12:66-71.
- Chittiboina P, Wyles E, Ogden A, Mukherjee DP, Vannemreddy P, Nanda A. Traumatic spondylolisthesis of the axis: A biomechanical comparison of clinically relevant anterior and posterior fusion techniques. *J Neurosurg Spine* 2009;11:379-87.
- Verheggen R, Jansen J. Hangman's fracture: Arguments in favor of surgical therapy for type II and III according to Edwards and Levine. *Surg Neurol* 1998;49:253-61.
- ElMiligui Y, Koptan W, Emran I. Transpedicular screw fixation for type II Hangman's fracture: A motion preserving procedure. *Eur Spine J* 2010;19:1299-305.
- Shah A, Dandpat S, Goel A. Hangman's fracture in a child with osteopetrosis. *World Neurosurg* 2020;139:370-2.
- Srivastava SK, Aggarwal RA, Nemade PS, Bhoale SK. Neglected Hangman fracture. *J Craniovertebr Junction Spine* 2015;6:209-11.
- Choi WG, Vishteh AG, Baskin JJ, Marciano FF, Dickman CA. Completely dislocated Hangman's fracture with a locked C2-3 facet. Case report. *J Neurosurg* 1997;87:757-60.
- Patibandla MR, Mudumba V, Yerramneni VK. Double Hangman's fracture. *Spine (Phila Pa 1976)* 2013;38:E374-7.
- Arand M, Neller S, Kinzl L, Claes L, Wilke HJ. The traumatic spondylolisthesis of the axis. A biomechanical *in vitro* evaluation of an instability model and clinical relevant constructs for stabilization. *Clin Biomech (Bristol, Avon)* 2002;17:432-8.
- Jain V, Thakur MK, Thakur A, Sud S, Lal M, Madan A. Functional outcome in unstable Hangman's fracture managed with anterior approach: A prospective study. *J Craniovertebr Junction Spine* 2017;8:350-3.
- Wang C, Ma H, Yuan W, Wang X, Chen H, Wu X. Anterior C3 corpectomy and fusion for complex Hangman's fractures. *Int Orthop* 2013;37:89-93.
- Xue D, Chen Q, Chen G, Zhuo W, Li F. Posterior arthrodesis of C1-C3 for the stabilization of multiple unstable upper cervical fractures with spinal cord compromise: A case report and literature review. *Medicine (Baltimore)* 2017;96:e5841.