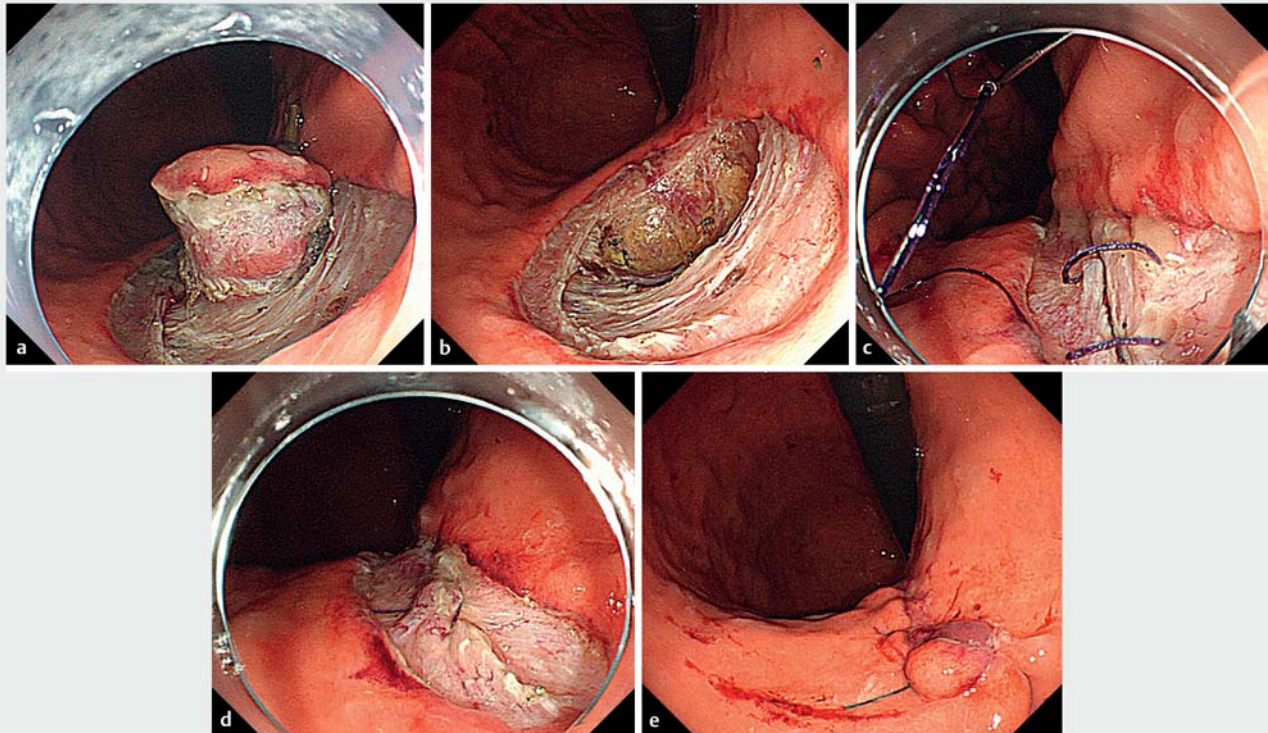


## Endoscopic full-thickness resection with double-layer closure by endoscopic hand suturing for a gastric subepithelial tumor



**Fig. 1** Endoscopic views of gastric endoscopic full-thickness resection followed by double-layer closure with endoscopic hand suturing showing: **a** a gastrointestinal stromal tumor located on the lesser curvature of the middle body of the stomach, for which a circumferential mucosal incision and submucosal dissection are performed; **b** the full-thickness defect that is created; **c** endoscopic hand suturing of the muscular layers initially; **d** subsequent continuous suturing of the mucosal layers; **e** complete closure of the full-thickness defect.

Gastric endoscopic full-thickness resection (EFTR) requires secure full-thickness defect closure [1]. Here, we report a successful case of EFTR with endoscopic hand suturing that provided a double-layer closure [2–4].

A 72-year-old woman was referred to our department with a 20-mm gastric subepithelial tumor on the lesser curvature of the middle gastric body, which was histologically diagnosed as a gastrointestinal stromal tumor (GIST). EFTR was considered preferable because the neural-vascular network in the lesser omentum was preserved. With the patient under general anesthesia, a single port was placed for a 5-mm laparoscope for security. After the overtube had been placed,

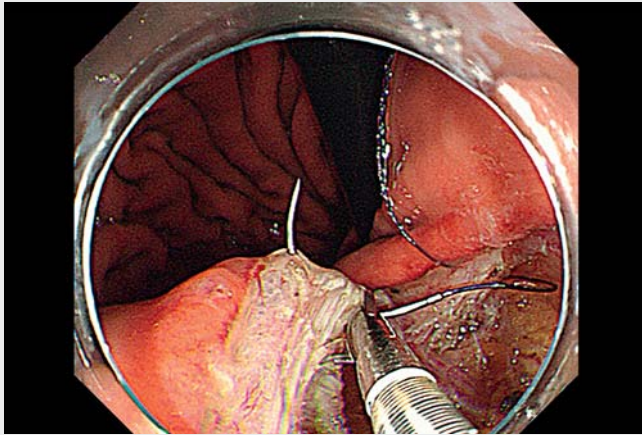
the lesion was removed en bloc in a full-thickness fashion and was transorally retrieved (► **Fig. 1 a, b**; ► **Video 1**).

Subsequently, double-layer suturing was performed by endoscopic hand suturing (► **Fig. 1 c–e**). In a retroflexed view, continuous suturing with a flexible needle holder (Olympus, Tokyo, Japan) was firstly initiated for the muscular layer with a V-loc absorbable barbed suture (Covidien, Mansfield, Massachusetts, USA). After the muscular layer had been tightly sutured, the remnant suture was cut with scissor forceps (Olympus) and transorally retrieved. Subsequently, the mucosal layer was sutured similarly to the muscular layer.

The procedure duration was 112 minutes, including the resection and suturing times of 34 and 66 minutes, respectively. The patient resumed her diet on postoperative day 3 and was discharged without experiencing any adverse events on postoperative day 10. Histology showed complete resection of a low risk GIST.

With well-maintained endoscopic visualization, layer-to-layer closure is possible for a full-thickness defect, providing safe and reliable EFTR for gastric subepithelial tumors. Further accumulation of clinical experience is desirable.

Endoscopy\_UCTN\_Code\_TTT\_1AO\_2AG



**Video 1** Full-thickness resection of a gastric gastrointestinal stromal tumor is performed, which is followed by double-layer suturing of the defect using the endoscopic hand suturing technique to continuously suture first the muscular layer and then the mucosa.

[4] Goto O, Oyama T, Ono H et al. Endoscopic hand-suturing is feasible, safe, and may reduce bleeding risk after gastric endoscopic submucosal dissection: a multicenter pilot study (with video). *Gastrointest Endosc* 2020; 91: 1195–1202

## Bibliography

Endoscopy 2022; 54: E964–E965

DOI 10.1055/a-1884-0065

ISSN 0013-726X

published online 29.7.2022

© 2022. The Author(s).

This is an open access article published by Thieme under the terms of the Creative Commons Attribution-NonDerivative-NonCommercial License, permitting copying and reproduction so long as the original work is given appropriate credit. Contents may not be used for commercial purposes, or adapted, remixed, transformed or built upon. (<https://creativecommons.org/licenses/by-nc-nd/4.0/>)

Georg Thieme Verlag KG, Rüdigerstraße 14, 70469 Stuttgart, Germany



## Competing interests

The flexible needle holder and the scissor forceps that were used for the endoscopic hand suturing were provided complimentary by Olympus Co., Ltd.

## The authors

Osamu Goto<sup>1,2</sup>, Eriko Koizumi<sup>2</sup>, Kazutoshi Higuchi<sup>2</sup>, Takeshi Onda<sup>2</sup>, Jun Omori<sup>2</sup>, Naohiko Akimoto<sup>2</sup>, Katsuhiko Iwakiri<sup>2</sup>

1 Endoscopy Center, Nippon Medical School Hospital, Tokyo, Japan

2 Department of Gastroenterology, Nippon Medical School, Graduate School of Medicine, Tokyo, Japan

## Corresponding author

Osamu Goto, MD, PhD

Endoscopy Center, Nippon Medical School Hospital, 1-1-5, Sendagi, Bunkyo-ku, Tokyo, 113–8603, Japan  
o-goto@nms.ac.jp

## References

- [1] Zhou PH, Yao LQ, Qin XY et al. Endoscopic full-thickness resection without laparoscopic assistance for gastric submucosal tumors originated from the muscularis propria. *Surg Endosc* 2011; 25: 2926–2931
- [2] Goto O, Sasaki M, Ishii H et al. A new endoscopic closure method for gastric mucosal defects: feasibility of endoscopic hand suturing in an ex vivo porcine model (with video). *Endosc Int Open* 2014; 2: E111–E116
- [3] Goto O, Sasaki M, Akimoto T et al. Endoscopic hand-suturing for defect closure after gastric endoscopic submucosal dissection: a pilot study in animals and in humans. *Endoscopy* 2017; 49: 792–797

## ENDOSCOPY E-VIDEOS

<https://eref.thieme.de/e-videos>



Endoscopy E-Videos is an open access online section, reporting on interesting cases

and new techniques in gastroenterological endoscopy. All papers include a high quality video and all contributions are freely accessible online. Processing charges apply (currently EUR 375), discounts and waivers acc. to HINARI are available.

This section has its own submission website at

<https://mc.manuscriptcentral.com/e-videos>