



## Pelvic inflammatory disease presenting 16 months after vaginal hysterectomy: A case report and literature review

Eloy Cabello-García<sup>a</sup>, Elena Ferriols-Pérez<sup>a,b,\*</sup>, Berta Urpí-Tosar<sup>a</sup>,  
Mireia González-Comadran<sup>a,b</sup>

<sup>a</sup> Obstetrics and Gynecology Department, Consorci Parc de Salut MAR, Universitat Autònoma de Barcelona, Barcelona, Passeig marítim 25-29 (08003), Spain

<sup>b</sup> GRI-BCN, Barcelona Infertility Research Group, IMIM, Institut Hospital del Mar d'Investigacions Mèdiques, Barcelona, Dr. Aiguader Street, 88 (08003), Spain

### ARTICLE INFO

#### Keywords:

Hysterectomy  
Pelvic inflammatory disease  
Tubo-ovarian abscess

### ABSTRACT

Pelvic inflammatory disease after hysterectomy is rare and the underlying route of infection is highly heterogeneous. We report the case of a 52-year-old woman with a history of vaginal hysterectomy for uterine prolapse admitted to the emergency department with acute abdominal pain and fever. Vaginal discharge and pelvic tenderness were evident in the clinical examination. Ultrasound and computed tomography scans showed a cystic pelvic mass in contact with the vaginal cuff, suggesting the diagnosis of pelvic inflammatory disease. Laparoscopic examination revealed a bilateral tubo-ovarian abscess firmly attached and fistulized to the vaginal cuff, and after tubal removal and antibiotic coverage the patient had an optimal recovery. We performed a review of the case reports published on this subject, and concluded that pelvic inflammatory disease should not be excluded in patients with a history of hysterectomy when symptoms and findings are compatible.

### 1. Introduction

Pelvic inflammatory disease (PID) is an infection of the female upper genital tract that affects 8–10% of sexually active women of reproductive age [1,2]. It is caused by the ascension of pathogenic bacteria to the uterus and the adnexa, although the mechanisms involved remain unclear [3]. PID has a wide range of clinical presentations, mostly depending on the pathogen involved [4,5]. More than 85% of cases of acute PID (<30 days of duration) are associated with bacterial vaginosis-related microbes and/or sexually transmitted pathogens, while less than 15% of the cases are due to respiratory or enteric pathogens that have colonized the vaginal canal [3]. Subclinical PID is twice as common and is caused by similar pathogens as acute PID [6].

The cause of chronic PID (> 30 days) is more commonly associated with actinomycetes species or even pathogens that arrive through the bloodstream (*Mycoplasma tuberculosis*) [7]. Nevertheless, it is frequent to find polymicrobial colonies in the bacterial cultures, commonly including anaerobic bacteria [1,2]. Apart from the ascending route, it has been reported that the microorganisms can reach the genital tract through the bloodstream (especially in tuberculosis) or by direct contact

(in cases of appendicitis or diverticulitis).

Rarely, PID can develop in patients who have previously undergone hysterectomy. Indeed, some authors have reported cases of tubo-ovarian abscess (TOA) from 8 months up to 16 years after the surgery [8–15]. This case report presents the development of PID in a patient who had had a vaginal hysterectomy 16 months earlier. The literature on this subject is reviewed in the Discussion.

### 2. Case Presentation

A 52-year-old postmenopausal, multiparous woman presented to the emergency room relating a 2-day history of lower abdominal pain refractory to oral analgesia, and fever up to 39 °C. The patient reported no nausea, vomiting, diarrhea or urinary symptoms, but described white vaginal discharge in the previous hours.

The most relevant medical history was a vaginal hysterectomy due to pelvic organ prolapse 16 months before this presentation. The patient was initially evaluated in the general surgery department and the abdominal examination revealed low abdominal pain, with voluntary guarding but no rebound tenderness.

\* Corresponding author at: Obstetrics and Gynecology Department, Consorci Parc de Salut Mar, Universitat Autònoma de Barcelona, Passeig marítim 25-29 (08003), Barcelona, Spain.

E-mail addresses: [ecabello@psmar.cat](mailto:ecabello@psmar.cat) (E. Cabello-García), [eferriols@psmar.cat](mailto:eferriols@psmar.cat) (E. Ferriols-Pérez), [burpi@psmar.cat](mailto:burpi@psmar.cat) (B. Urpí-Tosar), [mgonzalezcomadran@psmar.cat](mailto:mgonzalezcomadran@psmar.cat) (M. González-Comadran).

<https://doi.org/10.1016/j.crwh.2021.e00335>

Received 31 May 2021; Received in revised form 4 June 2021; Accepted 8 June 2021

Available online 10 June 2021

2214-9112/© 2021 Published by Elsevier B.V. This is an open access article under the CC BY-NC-ND license (<http://creativecommons.org/licenses/by-nc-nd/4.0/>).

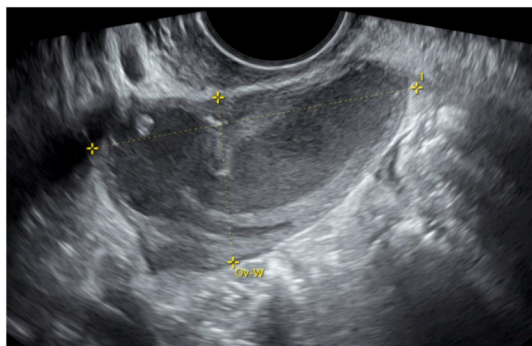


Fig. 2. Left tubo-ovarian abscess measuring 30 × 40 mm.

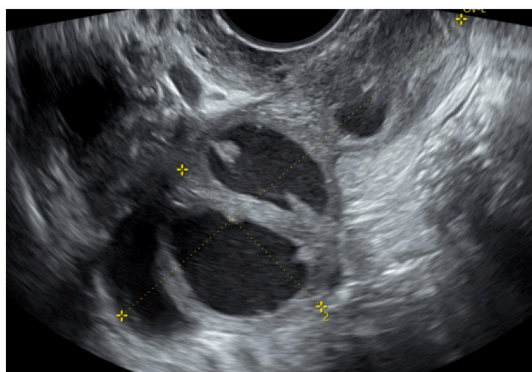


Fig. 1. Right tubo-ovarian abscess measuring 40 × 70 mm.

Laboratory test revealed white blood cell count within the normal range (leukocytes 8.380/mL with 70% neutrophils), although acute phase reactants were increased (reactive C protein 19.9 mg/dL and procalcitonin levels 0.065 ng/mL).

Appendicitis and diverticulitis were both excluded from the diagnosis after performing an abdominal ultrasound and a computed tomography (CT) scan. However, the CT scan revealed an elongated 76 × 33 mm predominantly cystic mass in the right iliac region, suggesting a right TOA.

The patient was then evaluated by the gynecology department. The pelvic examination revealed vaginal cuff tenderness and purulent discharge, but no sign of dehiscence. The transvaginal sonography findings were compatible with bilateral TOA, and there was no evidence of free fluid in the pouch of Douglas that would suggest ruptured TOA [Fig. 1, Fig. 2].

Intravenous antibiotic treatment was initiated for PID, with cefexime, doxycycline and metronidazole. There was a clear reduction in pain and the subsequent laboratory results showed a decrease in inflammatory markers. However, the patient's temperature persisted around 37–38 °C despite antibiotic treatment and, therefore, exploratory laparoscopic surgery was performed. During the surgical procedure a bilateral TOA was confirmed. The right tube measured approximately 6 × 8 cm, was firmly attached to the vaginal cuff and fistulized to the right margin, while the left tube measured 3 × 4 cm and was attached only to the pelvic peritoneum. Both fallopian tubes were successfully removed

by laparoscopy and the postoperative recovery was uneventful.

The patient was discharged from the hospital with oral antibiotics. At the follow-up visit, 6 weeks after discharge, the patient was full recovered. Pathologic examination showed chronic and acute salpingitis, and both blood and abscess cultures were negative.

### 3. Discussion

The development of a TOA in patients after hysterectomy is rare.

In order to gain a deeper understanding of the clinical case, a review of the published literature was performed. An exhaustive electronic search was performed in PUBMED and only 8 case reports were identified regarding the development of a PID in patients with a hysterectomy at least 4 weeks prior to attendance for PID [8–15][Table 1].

All patients from the articles reviewed were women of reproductive age (the age range was 28 to 49 years) at the time of the diagnosis of the PID. Five of them (62.5%) had a undergone abdominal hysterectomy [5,8,10,11,14], while the remaining three (37.5%) had undergone vaginal hysterectomy [9,12,13]. The average time between the hysterectomy and the onset of the symptoms was highly heterogeneous, with one case reported within the first year of the surgery [14], 4 cases between 2 and 6 years [8–10,12], and 2 cases after 12 and 16 years from the hysterectomy [11,15]. Abdominal pain and fever were the most consistent symptoms, as well as blood tests that repeatedly revealed leucocytosis in all the patients except for one [12]. Information regarding the antibiotic regimen and surgical treatment was provided in only 5 cases [10–12,14,15], which consisted on the removal of the fallopian tubes, and in half of these cases additionally the adnexa. Cultures were reported positive in 4 cases [9–12], although 2 authors did not provide this information.

The postoperative recovery was uneventful in 4 cases [10–12,15], and only one author reported a pelvic abscess diagnosed three weeks after bilateral salpingectomy, although the suspected mechanism for PID was bacterial translocation from the gastrointestinal tract [14]. In this regard, the mechanism of infection was unknown in most cases, although various mechanisms have been proposed, including an ascending route through a tubo-vaginal fistula, intestinal translocation and a haematogenous route [8,10,14,15].

The clinical case presented herein was comparable to the previous cases reviewed in the literature, in terms of both symptoms at onset and findings through imaging and laboratory tests. The mechanism of infection is still unknown, as all cultures came back negative. The use of antibiotics prior to the surgery may explain the negative results in the culture obtained from the TOA.

From the surgical findings, it can be hypothesised that the mechanism of infection might have been through a tubo-vaginal fistula, as the right fallopian tube adhered to the vaginal cuff. Nevertheless, the fistula might have also been secondary to the inflammatory process, instead of the initial cause. Hematogenous colonization, although unlikely, could not be excluded.

### 4. Conclusions

A hysterectomy represents the anatomic interruption of the communication between the upper and the lower female genital tract. This article emphasises the importance of considering the diagnosis of PID when symptoms suggest so, even if the patient has previously undergone hysterectomy, especially in women among reproductive age.

**Table 1**

Cases published in the literature of pelvic inflammatory disease after hysterectomy.

Author(s)	Canas et al.	Fletcher et al.	Lau et al.	Rivlin et al.	Tohya et al.	Mendez et al.	Mosholt et al.	Hueston
Age (years)	38	38	28	33	49	39	42	NR
Parity	Terciparous	Quintiparous	NR	Primiparous	Secundiparous	Primiparous	NR	NR
Medical history	Cholecystectomy	Type II diabetes Tubal ligation	NR	Previous STD (vaginal trichomona)	Cesarian section	Cesarian section, tubal ligation	NR	NR
Time between hysterectomy and the event	12 years	8 months	15 months	2 years	16 years	4 years	2 years	6 years
Type of hysterectomy	TAH	TAH	VH	VH	STAH	TAH	VH	TAH
Reason for hysterectomy	Cervical dysplasia	Leiomyoma	NR	Cervical carcinoma in situ	Uterine rupture	Leiomyoma	Uterine prolapse	NR
Symptoms	Abdominal pain, chills, nausea and vomiting	Abdominal pain, chills, nausea and vomiting	Abdominal pain and fever	Abdominal pain, nausea and vomiting	Abdominal pain and chills	Abdominal pain	Abdominal pain, fever and pelvic mass	NR
Number of Leukocytes in blood (/mm <sup>3</sup> )	12.200	22.500	22.700	9.200	12.200	17.400	NR	NR
Antibiotic regime	Gentamicin Metronidazole	Gentamicin Clindamycin	NR	Cefotetan Metronidazole Doxycycline	Clarythromycin Cefepime	Ampicilin, Gentamicin Clindamycin	NR	NR
Surgical Treatment	Bilateral salpingectomy	Bilateral salpingectomy	NR	Right adnexectomy	Bilateral adnexectomy	Bilateral adnexectomy	NR	NR
Cultures	Negative (abscess and vaginal cuff)	Negative	NR	<i>Neisseria gonorrhoeae</i> (vaginal discharge)	<i>Streptococcus milleri</i> and <i>Bacteroides oвалtus</i> (abscess)	<i>Streptococcus intermedius</i> (abscess)	<i>Chlamydia trachomatis</i> (peritoneal fluid)	NR
Route of infection	Unknown - possible tubo-vaginal fistula	Unknown-possible intestinal translocation	Unknown	Confirmed tubo-vaginal fistula	Ascending route	Unknown-intestinal translocation vs hematogenous.	Falopian tube prolapse	Unknown- post-operative complication vs hematogenous.
Recovery	Uneventful	Pelvic abscess at 3rd week	NR	Uneventful	Uneventful	Uneventful	NR	NR

NR, not reported; STAH, sub-total abdominal hysterectomy; TAH, total abdominal hysterectomy; VH, vaginal hysterectomy.

### Contributors

Eloy Cabello-Garcia, the primary author, was a physician involved in patient care, drafted the initial manuscript and revised and approved the final submission.

Elena Ferriols-Pérez, the corresponding author, was a senior physician involved in patient care, and revised the manuscript and approved the final submission.

Berta Urpí-Tosar was a physician involved in patient care, performed the literature review, revised the manuscript and approved the final submission.

Mireia González-Comadran was a senior physician involved in patient care, and the primary surgeon in this case, and revised the manuscript and approved the final submission.

### Conflict of Interest

The authors declare that they have no conflict of interest regarding the publication of this case report.

### Funding

No funding from an external source supported the publication of this case report.

### Patient Consent

The patient described in this case study provided written [informed consent](#).

### Provenance and Peer Review

This case report was peer reviewed.

### References

- [1] I. Simms, J.M. Stephenson, Pelvic inflammatory disease epidemiology: What do we know and what do we need to know? *Sex. Transm. Infect.* 76 (2000).
- [2] C.L. Haggerty, R.B. Ness, Epidemiology, pathogenesis and treatment of pelvic inflammatory disease, *Expert Rev. Anti-Infect. Ther.* 4 (2006) 235–247.
- [3] J. Ravel, I. Moreno, C. Simón, Bacterial vaginosis and its association with infertility, endometritis, and pelvic inflammatory disease, *Am. J. Obstet. Gynecol.* 224 (2021).
- [4] E. Cicinelli, D. De Ziegler, R. Nicoletti, G. Colafiglio, N. Saliari, L. Resta, et al., Chronic endometritis: correlation among hysteroscopic, histologic, and bacteriologic findings in a prospective trial with 2190 consecutive office hysteroscopies, *Fertil. Steril.* 89 (3) (2008).
- [5] R.C. Brunham, S.L. Gottlieb, J. Paavonen, Pelvic inflammatory disease, *N. Engl. J. Med.* 372 (21) (2015) 2039–2048.
- [6] K. Holmes, P. Sparling, W. Stamm, P. Piot, J. Wasserheit, L. Corey, et al., *Sexually Transmitted Diseases*, 4th ed., The McGraw-Hill Companies, New York, 2007, pp. 344–345.
- [7] D.G. Tsevat, H.C. Wiesenfeld, C. Parks, J.F. Peipert, Sexually transmitted diseases and infertility, *Am. J. Obstet. Gynecol.* 216 (1) (2017) 1–9. Available from, <https://doi.org/10.1016/j.ajog.2016.08.008>.
- [8] W.J. Hueston, A case of tubo-ovarian abscess 6 years after hysterectomy, *J. Ky Med. Assoc.* 90 (3) (1992) 114–116.

- [9] K.S.S. Mosholt, T.A. Filtenborg, Fallopian tube prolapse and Chlamydia peritonitis after vaginal hysterectomy, *Ugeskr. Laeger* 174 (3) (2012).
- [10] L.E. Mendez, S.M. Bhoola, I.R. Horowitz, Bilateral tubo-ovarian abscesses four years after total abdominal hysterectomy, *Infect. Dis. Obstet. Gynecol.* 6 (3) (1998) 138–140.
- [11] T. Tohya, T. Yoshimura, C. Onoda, Tubo-ovarian abscess occurring 16 years after supracervical hysterectomy, *Infect. Dis. Obstet. Gynecol.* 11 (3) (2003).
- [12] M.E. Rivlin, Tubovaginal fistula after vaginal hysterectomy complicated by a tubo-ovarian abscess and diffuse peritonitis, *Obstet. Gynecol.* 94 (5 SUPPL. 1) (1999 Nov) 858.
- [13] M. Lau, C.A. Cross, P. Berens, K. Cunningham, J. Mahnke, V. Ali, et al., Ovarian abscess 15 months after vaginal hysterectomy: A case report, *J Reprod Med Obstet Gynecol* 42 (10) (1997).
- [14] J.L. Fletcher, T.E. Nolan, M.J. Milam, Late tubo-ovarian abscess following abdominal hysterectomy, *J. Fam. Pract.* 33 (2) (1991).
- [15] A.M. Canas, B. Holloran-Schwartz, T. Myles, Tuboovarian abscess 12 years after total abdominal hysterectomy, *Obstet. Gynecol.* 104 (5) (2004) 1039–1041.