

Luteoma of Pregnancy Masquerading as Ectopic Pregnancy: Lessons Learnt

Sir,

Pregnancy luteomas are rare, benign, neoplasms of the ovary, caused by hormonal effects of pregnancy,^[1] and were first described in 1969 by Sternberg and Barclay.^[2] In most cases, these are incidentally found during imaging or surgery.^[3] However, in rare cases, large-sized pregnancy luteomas may cause complications because of their mass effect or may present as torsion.^[4] Few cases associated with virilization of the mother or infant have also been reported.^[5] The case described here is unusual because the tubo-ovarian mass was misdiagnosed as ectopic pregnancy in the emergency setting. To the best of our knowledge, to date, only one such case has previously been reported.^[6]

A 28-year-old woman, gravida 4, para 3, with three live issues, presented to the obstetric emergency with a history of 2-month amenorrhea, bleeding per vaginum and acute pain abdomen for 6 h, not relieved by medications. Urine pregnancy test was positive and serum beta human chorionic gonadotropin levels (hCG) were elevated at 6364 mIU/ml. Ultrasound was suggestive of a tubo-ovarian mass, and thus a diagnosis of ectopic pregnancy was suggested. As pain could not be controlled by medication, a possibility of ruptured ectopic pregnancy was considered. An emergency laparotomy was performed, followed by salpingo-oophorectomy.

On gross examination, the ovary was found to be enlarged, measuring 5.2 cm × 4.4 cm × 3 cm, with attached fallopian tube [Figure 1]. Cut surface revealed a well-circumscribed nodular lesion measuring 1.5 cm × 1 cm and grayish white in color, with focal areas of hemorrhage. The adjoining ovary also showed the presence of hemorrhagic and cystic areas. Paraffin-embedded sections showed a well-circumscribed nodule composed of polygonal cells lying in sheets, islands and cords, separated by fibrous septae. The cells were larger in size than theca lutein cells with moderate to abundant finely granular eosinophilic cytoplasm, round to oval nuclei, vesicular chromatin and inconspicuous to conspicuous nucleoli [Figure 2]. Focal areas of hemorrhage were noted. No atypia, mitosis, necrosis, Reinke's crystalloids and nuclear grooves were identified. The surrounding ovary showed normal ovarian stroma, with few cystic areas showing evidence

of corpus luteum hemorrhagicum. Further, these cells showed cytoplasmic positivity with inhibin [Figure 3]. Reticulin staining was observed in investing groups of cells than in individual cells [Figure 4].

Based on the clinical and histopathological findings, a possibility of missed abortion was suggested and diagnosis of pregnancy luteoma of ovary was made. Microscopic features similar to those described in literature were seen in our patient. While the presence of slight nuclear atypia and mitosis has been reported, our patient did not exhibit these features.^[5] One month after the surgery, her beta hCG levels had lowered.

Differential diagnosis for pregnancy luteoma ranges from benign to malignant lesions, which require aggressive treatment. Hyperreactio luteinalis is the most common benign differential diagnosis, and unlike pregnancy luteoma, it is characterized by bilateral ovarian enlargement and numerous follicular cysts. Moreover, this tumor is more cystic than pregnancy luteomas.^[1,3] Corpus luteoma of pregnancy can be considered as an important differential diagnosis, especially because it is also commonly observed during early pregnancy.^[1,3] Corpus luteoma of pregnancy demonstrates a characteristic architecture of convoluted folds around the central fibrovascular core, hyaline globules and calcifications. In our case, the adjoining ovary did demonstrate some features of corpus luteum of pregnancy such as convoluted folds. However, no hyaline globules or calcifications were observed.^[1-3]

Steroid cell tumors, especially the lipid-poor variant, are considered the closest differential diagnosis among malignant lesions. However, as the prognosis varies considerably, it is imperative to histologically distinguish between the two. Steroid cell tumors are usually unilateral, solitary and, microscopically, have a distinct vascular pattern that is not seen in pregnancy luteomas.^[1,3] The presence of characteristic nonluteinized cells in both luteinized granulosa cell tumors and thecomas helps histologically rule out the diagnosis of steroid cell tumors. In thecomas, reticulin staining is observed in investing single and small groups of cells rather than in larger nodules, as observed in pregnancy luteomas. Thus,

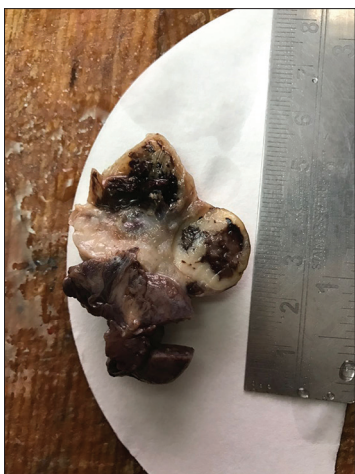

Figure 1: Enlarged ovary

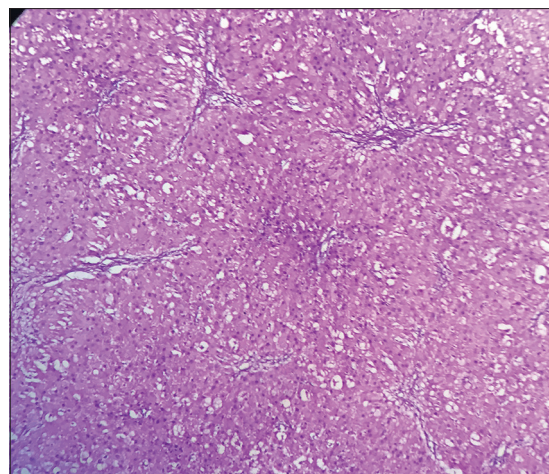


Figure 2: Polygonal cells lying in sheets, islands and cords

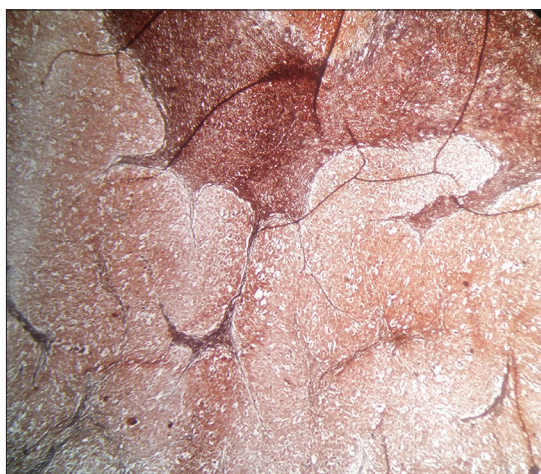


Figure 3: Reticulin staining observed in investing groups of cells

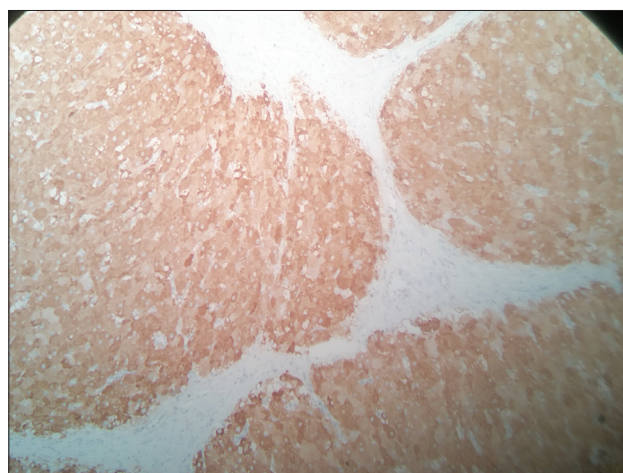


Figure 4: Cells showing cytoplasmic positivity with inhibin

reticulin stain plays an important role in differentiating between the two.

Because of the relative paucity of available literature, luteomas of pregnancy are often not suspected clinically and radiologically, potentially leading to more aggressive treatment. In addition, as these are mass-forming lesions of the ovary, the chances of being misdiagnosed as ovarian tumors are high. Notably, pregnancy luteomas rarely present during early pregnancy.

Awareness of pregnancy luteomas is of paramount importance for keeping a higher index of suspicion and considering them in the list of differential diagnosis for tubo-ovarian masses. As pregnancy luteomas regress spontaneously, a more vigilant clinical outlook may help avoid unnecessary surgery, preserve fertility wherever possible and reduce patient morbidity.

Financial support and sponsorship

Nil.

Conflicts of interest

There are no conflicts of interest.

Ruchi Rathore, Akshi Katyal, Shilpi, Namrata Nargotra

Department of Pathology, Hindu Rao Hospital, New Delhi, India

Correspondence: Dr. Ruchi Rathore, Assistant Professor, Department of Pathology, Hindu Rao Hospital, New Delhi - 110 007, India.
E-mail: ruchirathore13@gmail.com

REFERENCES

1. Burandt E, Young RH. Pregnancy luteoma: A study of 20 cases on the occasion of the 50th anniversary of its description by Dr. William H. Sternberg, with an emphasis on the common

presence of follicle-like spaces and their diagnostic implications. *Am J Surg Pathol* 2014;38:239-44.

2. Sternberg W, Barclay D. Luteoma of pregnancy. *Am J Obstet Gynecol* 1966;95:165-81.
3. Medeiros F, Bell DA. Pseudoneoplastic lesions of the female genital tract. *Arch Pathol Lab Med* 2010;134:393-403.
4. Tan ML, Lam SL, Nadarajah S. Pregnancy luteoma presenting as ovarian torsion with rupture and intra-abdominal bleeding. *Singapore Med J* 2008;49:e78-81.
5. Wang YC, Young Su H, Liu JY, Chang FW, Chen CH. Maternal and female fetal virilization caused by pregnancy luteomas. *Fertil Steril* 2005;84:509.
6. Honore LH, O'Hara KE. Incidental pregnancy luteoma associated with ectopic tubo-ovarian pregnancy: Evidence in favour of origin from theca interna of an atretic follicle. *Eur J Obstet Gynecol Reprod Biol* 1978;8:15-9.

This is an open access article distributed under the terms of the Creative Commons Attribution-NonCommercial-ShareAlike 3.0 License, which allows others to remix, tweak, and build upon the work non-commercially, as long as the author is credited and the new creations are licensed under the identical terms.

Access this article online	
Quick Response Code:	Website: www.sjmms.net
	DOI: 10.4103/sjmms.sjmms_50_17

How to cite this article: Rathore R, Katyal A, Shilpi, Nargotra N. Luteoma of pregnancy masquerading as ectopic pregnancy: Lessons learnt. *Saudi J Med Med Sci* 2017;5:281-3.