

Persistent or recurrent Castleman's disease – Look out for a lurking lymphoma!

Shalinee Rao, Anita Ramesh¹,

Aarathi Rajkumar,

Rekha Arcot², Sarah Kuruvilla

Departments of Pathology,
¹Medical Oncology, and ²Surgery,
Sri Ramachandra University, Porur,
Chennai, Tamil Nadu, India

Address for correspondence:

Dr. Shalinee Rao,
Department of Pathology,
Sri Ramachandra Medical College
& Research Institute,
Sri Ramachandra University,
Porur, Chennai - 600 116,
Tamil Nadu, India.
E-mail: shalineerao@rediffmail.com

ABSTRACT

Castleman's disease, a rare condition of uncertain etiology clinically presents in isolated form or as a multicentric disease. The multicentric form can develop malignancies such as Kaposi's sarcoma or lymphomas. We present a case of Castleman's disease with coexisting interfollicular Hodgkin's lymphoma that was confirmed by immunohistochemistry. This case report highlights the fact that an occult lymphoma has to be ruled out in persistent or recurrent Castleman's disease.

Key words: *Castleman's disease, immunohistochemistry, interfollicular Hodgkin's lymphoma*

INTRODUCTION

Castleman's disease is a rare, non-neoplastic lymphoproliferative disorder of uncertain aetiology, wherein the age of onset, clinical presentation and the histological subtype vary markedly. Clinically, Castleman's disease can be classified into unicentric/unifocal or systemic/multifocal forms. Patients with Castleman's disease are at a high risk for the development of malignant lymphomas and Kaposi sarcoma. Hence, a regular medical surveillance is necessary in these cases. A review of literature shows that non-Hodgkin's lymphoma is seen more commonly in association with Castleman's disease; however, rarely Hodgkin's lymphoma can also occur.^[1] We document here, a patient diagnosed as Castleman's disease, who later developed an interfollicular Hodgkin's lymphoma on lymph node biopsy. The Hodgkin's lymphoma component was subtle and focal, which could have been missed if a high degree of suspicion had not allowed us to confirm the diagnosis by immunomarkers.

CASE REPORT

A 68-year-old hypertensive and diabetic lady presented with multiple bilateral cervical and axillary lymphadenopathy. Six months before this visit, she presented with a solitary left cervical lymphadenopathy which on excision biopsy showed features of hyaline-vascular type of Castleman's disease. Physical examination on the second visit revealed multiple bilateral cervical and left-sided axillary lymph nodes that were non-tender, discrete, firm in consistency and ranged in size from 0.5 to 8 cm. No organomegaly or constitutional symptoms were noted. Routine investigations such as complete blood count and biochemical profile (including hepatic function tests) were found to be within normal range except for mildly raised globulins (3.9 g/dl). Bone marrow aspiration done showed normal reactive marrow. Chest X-ray and computerized tomography (CT) scan of abdomen was normal. CT of thorax revealed left axillary adenopathy but mediastinum and lung fields were normal. Patient was seronegative for human immunodeficiency virus (HIV) by Western blot method.

In spite of a course of antibiotics there was no reduction in lymphadenopathy in the 2nd visit. Hence clinically, a recurrent Castleman's disease was suspected and the largest axillary lymph node was excised and sent for histopathological confirmation. The biopsy showed partial effacement of lymph node architecture with expansion of paracortical and interfollicular regions.

Access this article online

Quick Response Code:



Website:
www.ijmpo.org

DOI:
10.4103/0971-5851.92820

Hyalinized follicles, interfollicular vascular proliferation and paracortical collection of plasma cells were also seen [Figure 1]. The interfollicular region showed polymorphous population of cells composed of eosinophils, neutrophils, plasma cells and binucleate/mononuclear atypical cells with abundant cytoplasm having inclusion like eosinophilic nucleoli with perinucleolar halo that resembled Reed-Sternberg (RS) cells [Figure 1, inset].

A panel of immunohistochemical (IHC) markers on tissue sections showed positivity for CD15 and CD30 with negative staining for CD 45 in RS-like cells and few background lymphocytes showed CD 20 positivity [Figure 2]. At this point, the previous lymph node biopsy sections were reviewed and no evidence of Hodgkin's disease was found. Correlating the clinical, histomorphology and immunohistochemistry, the final diagnosis of Castleman's disease (hyaline vascular type) with a coexistent interfollicular Hodgkin's lymphoma (Stage IIA) was arrived at.

The patient was given three cycles of chemotherapy with COPP (Cyclophosphamide, Oncovin, Procarbazine and Prednisolone). She developed hyperglycemia, hence the chemotherapeutic drugs were changed to ABVD (Adriamycin, Bleomycin, Vinblastine, Dicarbazine) regimen for the next three cycles. Patient is now in complete remission after 2 years of diagnosis and treatment.

DISCUSSION

Castleman's disease also termed as angiofollicular hyperplasia/giant lymph node hyperplasia is categorised

into plasma cell, hyaline-vascular and mixed type on histopathology. Castleman's disease can mimic lymphoma clinically as it varies from the latter histologically and therapeutically, it is necessary to distinguish these two conditions. Castleman's disease may occur in lymph nodes involved by Hodgkin's lymphoma, resulting in a diagnostic dilemma. Castleman's-like histological features may also be seen as a part of a non-specific immune response to a variety of immunological stimuli including, Hodgkin's disease. Hence, a possibility of Hodgkin's disease needs to be considered and excluded before a conclusive diagnosis of Castleman's disease is made.^[2]

The predominant pattern seen in this case was a hyaline vascular type of Castleman's disease which masked an underlying interfollicular Hodgkin's lymphoma. The suspicious RS-like cells in the lymph node showed positivity for CD15 and CD 30 but was negative for CD 45 thereby confirming a Hodgkin's lymphoma along with Castleman's disease.

Utilization of IHC stains proved to be a valuable tool in identifying the RS cells in our case. Zarate-Osorno documented similar cases exhibiting diagnostic problems in which IHC was useful in detecting the evidence of Hodgkin's lymphoma in Castleman's disease.^[2] Likewise Maheswaran *et al.* reviewed cases previously diagnosed as Castleman's disease presenting later as Hodgkin's disease and IHC studies on these cases showed positivity for CD 15 and CD 30 indicating that a coexisting Hodgkin's was overlooked on initial biopsy.^[3] In our case, previous lymph node biopsy showed only hyaline-vascular pattern of Castleman's disease with no evidence of Hodgkin's lymphoma.

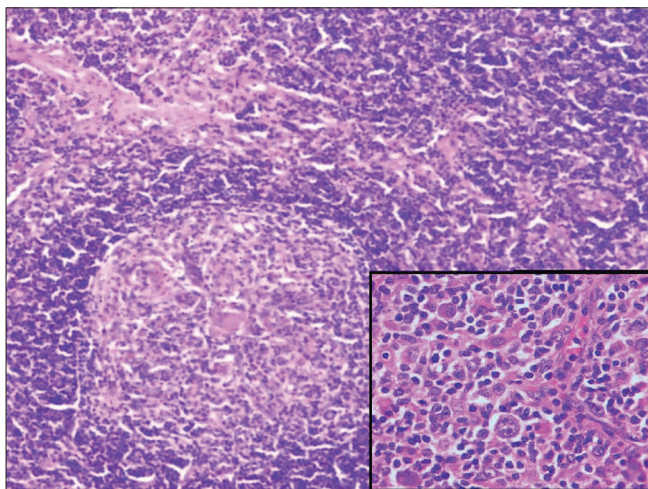


Figure 1: Lymph node with interfollicular expansion and a large lymphoid follicle showing prominent hyalinised blood vessel within germinal centre (Hematoxylin and eosin stain x40); Inset shows Reed-Sternberg cells (Hematoxylin and eosin stain x400)

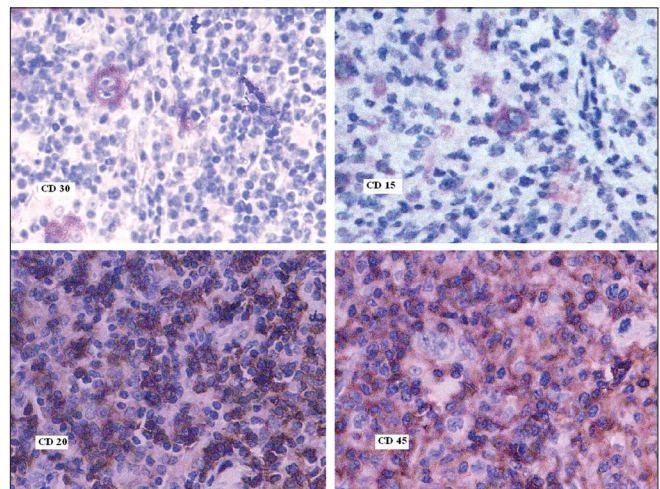


Figure 2: Reed-Sternberg cells highlighted by positive staining with CD 15 and 30 and negative staining with CD45 while background lymphocytes are positive for CD20 (Immunostains: CD 30, CD15, CD20 and CD45 x400)

The pathogenesis of Castleman's disease is complex. Recently Kaposi's sarcoma associated Herpes virus (also called Human Herpes virus – 8) was reported to be an etiological agent of Castleman's disease, especially in patients infected with HIV. The association of interleukin-6 (IL-6) in the evolution of Castleman's disease is suggested due to an increased IL-6 production by the germinal centres. Monoclonal antibody blocking the IL-6 receptor have shown clinical efficacy resulting in symptom resolution.^[4] Several treatment protocols have been designed for Castleman's disease. In case of a localized disease, the options include excision of the affected lymph nodes and radiation. Corticosteroid, chemotherapy drugs and radiation therapy are treatment modalities available for multicentric disease. Targeting and deleting CD20-positive B cells, a prominent component of Castleman's disease, is a new immunotherapeutic approach which is responsible for the deregulated productions of human IL-6, vascular endothelial growth factor (VEGF) and other cytokines as well.^[5]

Lymphoma occurring within the context of Castleman's disease should be treated with standard lymphoma chemotherapy regimen. Targeted therapy may be used against cytokines IL-2R and IL-6, the increased levels of which are responsible for characteristic B symptoms. Purging of CD20 positive cells using antiCD20 therapy might also be beneficial, since it deprives RS cells of a survival factor.^[6] In our case, the patient responded well to COPP and ABVD therapy and after six cycles of chemotherapy, the patient is in complete remission for 2 years.

Rare cases of Hodgkin's lymphoma may present initially

with a histological picture indistinguishable from Castleman's disease and the diagnosis may become evident only at a late stage. Therefore, before a final diagnosis of Castleman's disease is made, the lymph node must be scrutinised thoroughly for the subtle evidence of lymphoma using a panel of immunomarkers.

REFERENCES

1. Frank DK, Charney D, Kashani A. Plasma cell variant of Castleman's disease occurring concurrently with Hodgkin's disease in the neck. *Head Neck* 2001;23:166-9.
2. Zarate-Osorno A, Medeiros LJ, Danon AD, Neiman RS. Hodgkin's disease with coexistent Castleman-like histologic features: A report of three cases. *Arch Pathol Lab Med* 1994;118:270-4.
3. Maheswaran PR, Ramsay AD, Norton AJ, Roche WR. Hodgkin's disease presenting with the histological features of Castleman's disease. *Histopathology* 1991;18:249-53.
4. Nishimoto N, Sasai M, Shima Y, Nakagawa M, Matsumoto T, Shirai T, *et al.* Improvement in Castleman's disease by humanized anti-interleukin-6 receptor antibody therapy. *Blood* 2000;95:56-61.
5. Estephan FF, Elghetany MT, Berry M, Jones DV Jr. Complete remission with anti-CD20 therapy for unicentric, non-HIV-associated, hyaline-vascular type, Castleman's disease. *Cancer Invest* 2005;23:191.
6. Falchi L, Capello D, Palumbo B, Rauco A, Emili R, Cianciulli M, *et al.* A case of nodular sclerosis Hodgkin's lymphoma repeatedly relapsing in the context of composite plasma cell-hyaline vascular Castleman's disease: Successful response to rituximab and radiotherapy. *Eur J Haematol* 2007;79: 455-61.

How to cite this article: Rao S, Ramesh A, Rajkumar A, Arcot R, Kuruvilla S. Persistent or recurrent Castleman's disease - Look out for a lurking lymphoma!. *Indian J Med Paediatr Oncol* 2011;32:162-4.

Source of Support: Nil, **Conflict of Interest:** None declared.

Staying in touch with the journal

1) Table of Contents (TOC) email alert

Receive an email alert containing the TOC when a new complete issue of the journal is made available online. To register for TOC alerts go to www.ijmpo.org/signup.asp.

2) RSS feeds

Really Simple Syndication (RSS) helps you to get alerts on new publication right on your desktop without going to the journal's website. You need a software (e.g. RSSReader, Feed Demon, FeedReader, My Yahoo!, NewsGator and NewzCrawler) to get advantage of this tool. RSS feeds can also be read through FireFox or Microsoft Outlook 2007. Once any of these small (and mostly free) software is installed, add www.ijmpo.org/rssfeed.asp as one of the feeds.