

Surgical Technique: Anatomic Medial Patellofemoral Ligament Retensioning Repair



Ricardo Hideki Yanasse, M.D., Guilherme Aravechia, M.D., Tiago Rocha Ramos, M.D., Luiz Gustavo Lucena Augusto Lima, M.D., Danilo Zanutto de Oliveira Medeiros, M.D., Marcos Henrique Ferreira Laraya, M.D., and Roberto Ryuiti Mizobuchi, Ph.D.

Abstract: The medial patellofemoral ligament (MPFL) and the MPFL/vastus medialis obliquus complex are essential for patellar stability. Insufficiency of the MPFL can lead to altered biomechanics and patellofemoral joint contact pressure, high recurrence rate, osteochondral lesions, compromised knee function, and patellofemoral osteoarthritis. Most frequently surgical reconstruction of the MPFL is performed to address patellar instability; however, open physis and donor site morbidity can be a concern. This Technical Note presents a surgical technique to identify the insufficient MPFL and describes in detail an anatomical retensioning repair of the MPFL to restore patellar stability.

Biochemical studies have shown that the medial patellofemoral ligament (MPFL) is an essential and main patellar stabilizer at 0° to 30° of knee flexion.¹ MPFL insufficiency has shown to alter joint kinematics and contact mechanics increasing lateral patellofemoral contact pressure.² Long-term consequences of MPFL insufficiency are still debatable and may contribute to cartilage degeneration,² and may lead to abnormal trochlear and patellar dysplasia formation in children during growth.

The nonoperative treatment of an acute patellar dislocation reports a high recurrence rate, impaired knee function,³⁻⁶ that may be related to altered biomechanics and patellofemoral joint contact pressure, and patellofemoral osteoarthritis at long-term follow-up.²⁻⁴ Surgical treatment to address patellar instability is growing, and innumerable surgical techniques addressing the MPFL in an attempt to repair or reconstruct the

primary restraint against lateral patellar dislocation have been reported.⁷⁻²⁰ The operative treatment of acute patellar dislocations may result in a lower rate of recurrent dislocation,^{6,21} specially in children and adolescents and offer better quality of life and function.^{5,6}

This Technical Note presents a surgical technique to identify the insufficient MPFL and describes in detail an anatomical retensioning repair of the MPFL to restore patellar stability ([Video 1](#)).

Surgical Technique

Positioning

The patient is placed in a supine position on the operating table. Under anesthesia and before tourniquet insufflation, the knee is examined for patellar stability and kinematics and compared with the normal contralateral knee.

Surgical Approach and MPFL Identification

A tourniquet is inflated and a vertical medial parapatellar skin incision is made starting at the level of the proximal pole of the patella and ending at the level of the distal pole of the patella. The patella is exposed together with the medial portion of the quadriceps tendon, the vastus medialis, and the medial retinaculum. A vertical incision is made at the medial border of the patella starting at the distal border of the vastus medialis obliquus (VMO) and ending at the inferior pole of the patella. Care must be taken to incise only the medial retinaculum (layer II) and preserve the capsule underneath (layer III) ([Fig 1](#)). Blunt dissection is carried

From the Department of Orthopaedics, Faculdade de Medicina de Marília (Famema), Marília, São Paulo, Brazil.

The authors report that they have no conflicts of interest in the authorship and publication of this article. Full ICMJE author disclosure forms are available for this article online, as [supplementary material](#).

Received November 11, 2017; accepted February 1, 2018.

Address correspondence to Ricardo Hideki Yanasse, M.D., Departamento de Ortopedia-FAMEMA Rua Monte Carmelo, 800, Bairro Fragata, CEP 17519-030, Marília, São Paulo, Brazil. E-mail: ricardoyanasse@yahoo.com.br

© 2018 by the Arthroscopy Association of North America. Published by Elsevier. This is an open access article under the CC BY-NC-ND license (<http://creativecommons.org/licenses/by-nc-nd/4.0/>).

2212-6287/171395

<https://doi.org/10.1016/j.eats.2018.02.001>

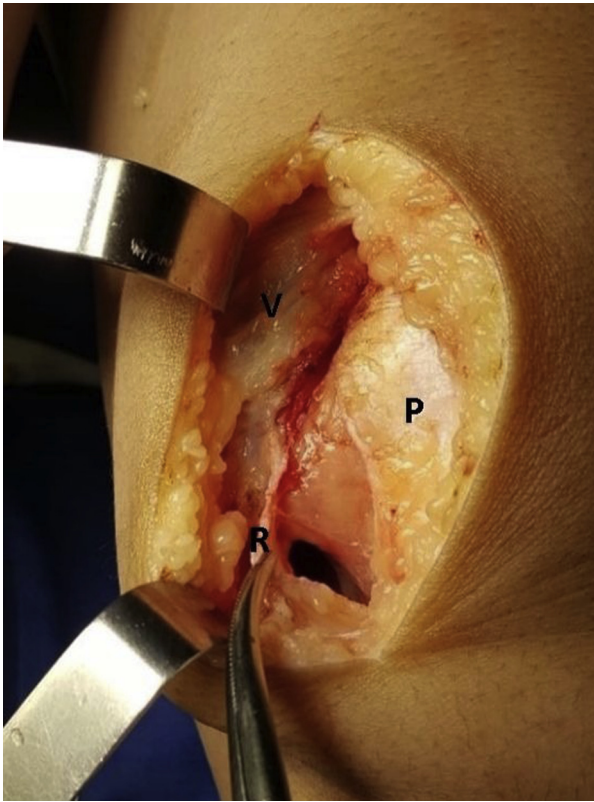


Fig 1. Retensioning repair of the medial patellofemoral ligament of a left side knee. Incision at the medial border of the patella (P) releasing the medial retinaculum (R) and the vastus medialis (V) with care to preserve the capsule underneath.

out to separate the medial retinaculum and the capsule. Note at this point that separation of the layers can be difficult proximally where the layers are composed of

the distal border of the VMO, the MPFL, and the capsule. These layers merge together to insert at the patella. The vertical incision starting at the distal border of the VMO is now carried out proximally to incise and release the tendinous portion of the VMO from the proximal medial border of the patella; again care must be taken not to incise the capsule underneath. Beneath the VMO, blunt dissection can easily separate the VMO (layer II) from the capsule (layer III). Note that when separating the medial retinaculum from the capsule a bridge may form at the distal border of the VMO at the location of the MPFL (Fig 2A) and sharp dissection may be necessary to separate these 2 layers (Fig 2B). Once the layers are separated, the medial retinaculum together with the VMO are elevated and the capsule below still attached to the patella is observed to be slack. Lateralization of the patella, simulating the apprehension test and forcing patellar dislocation, can tension the medial capsule allowing sometimes a cord to be palpated (Fig 3). This cord is adjacent to the distal border of the VMO, where sharp dissection was carried out, and is believed to be the deep portion of the MPFL. A key portion of the procedure is to identify this cord structure by vertically incising the capsule at the medial border of the patella and placing a Kocher clamp on the capsule to tighten this structure and allow better identification of this cord (Fig 4A).

MPFL Retensioning and Fixation

A Krackow stitch is placed on the deep portion of the MPFL using Ethibond No.5-0 (Ethicon, Somerville, NJ) (Fig 4B). The medial border of the patella is rasped at the junction of the proximal and medial thirds of the patella to prepare the patellar insertion of the MPFL.

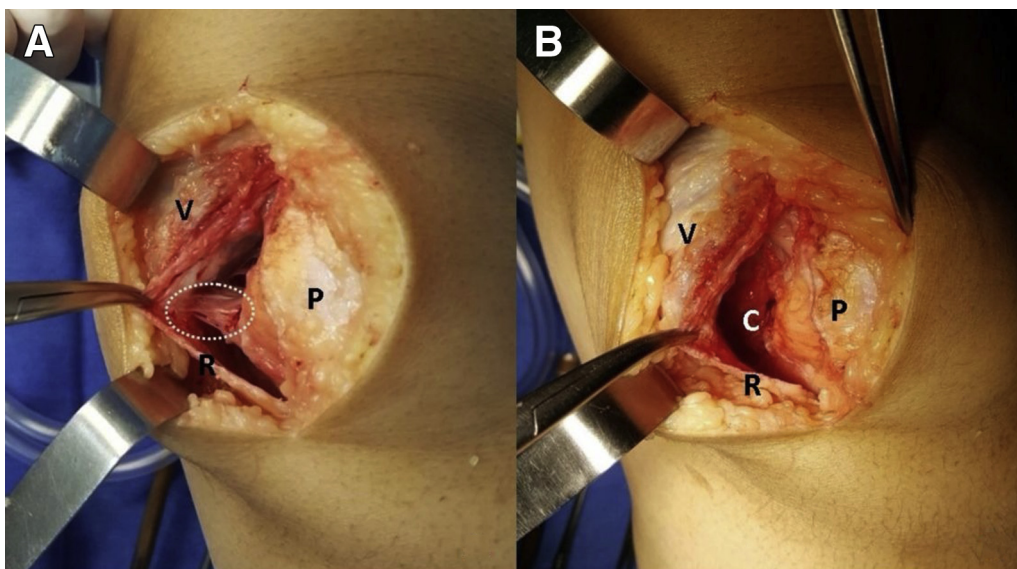


Fig 2. Left side knee. (A) Separating the medial retinaculum (layer II) from the capsule (layer III), a bridge may form at the distal border of the vastus medialis (V) at the location of the medial patellofemoral ligament, where “meshing” of these structures occur (white dotted circle) and (B) sharp dissection may be necessary to separate these 2 layers. (C, capsule; P, patella; R, medial retinaculum.)

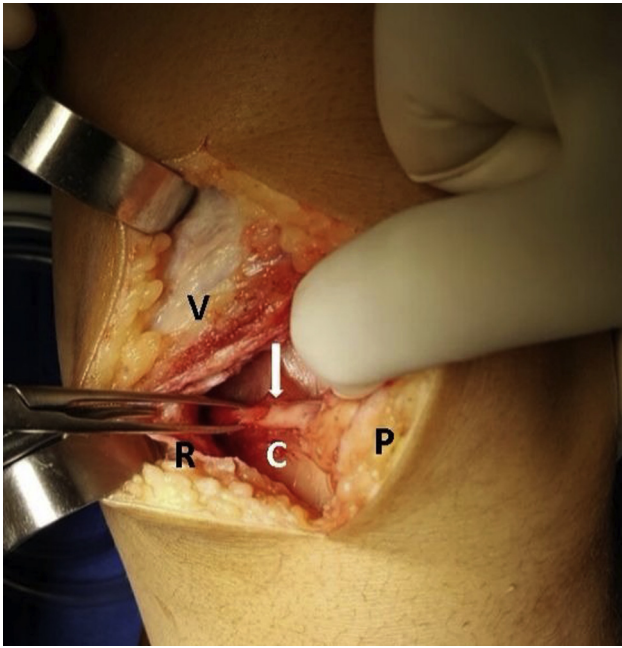


Fig 3. Left side knee. Lateralization of the patella can tension the medial capsule and a cord may possibly be palpated (white arrow). (C, capsule; P, patella; R, medial retinaculum; V, vastus medialis.)

Two transosseous sutures are placed from medial to lateral on the patella (Fig 5). The knee is placed in 60° to 70° of flexion (Fig 6A) and the transosseous sutures are tensioned and tied (Fig 6B). Patellar mobility is assessed and with the knee flexed at 30° the patella is forced laterally (apprehension test) to check for adequate MPFL tension and patellar stability. The VMO

is reattached and sutured to the patella in its previous anatomical position as well as the medial retinaculum. The pearls and pitfalls of this technique are described in Table 1.

Rehabilitation

Postoperatively the knee is braced for 3 to 4 weeks, and passive range of motion started after the first week together with quadriceps setting exercises. Progressive weight bearing with a brace and walking with crutches is initiated after the second week. Active flexion and extension and gluteus activation is emphasized at the third and fourth weeks. Full weight bearing is allowed after 4 weeks. Sports activities are initiated after 3 to 4 months of surgery and according to muscular and functional recovery.

Discussion

Classically, the 3-layer concept described by Warren and Marshall²² identifies the MPFL in layer II, deep to the deep fascia or crural fascia (layer I) and superficial to the capsule (layer III). Near the patellar insertion the fibers of the MPFL blend with the medial retinaculum making dissection difficult.²³ The strong “meshing” of the superficial layer with the VMO and the MPFL near the patella has been described anatomically and contributes to a dynamic function of the VMO in stabilizing the patella.^{24,25} Anatomical studies have described the MPFL to course from the medial patellar margin to the posteromedial capsule, and the deep fibers of the MPFL to be continuous with the posteromedial capsule and anchored to the bone just

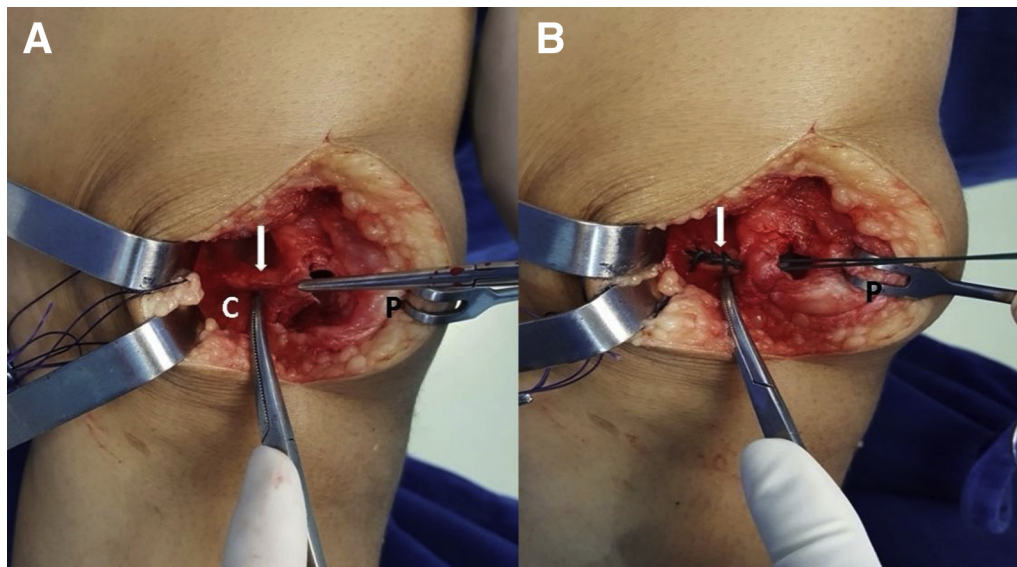


Fig 4. Left side knee. (A) The capsule is incised at the medial border of the patella and a Kocher clamp on the capsule to tighten this structure and allow better identification of this cord (white arrow and pointed by the Kelly clamp), which is believed to be the deep portion of the medial patellofemoral ligament. (B) A Krackow stitch is placed on the deep portion of the medial patellofemoral ligament using Ethibond No. 5. (C, capsule; P, patella.)

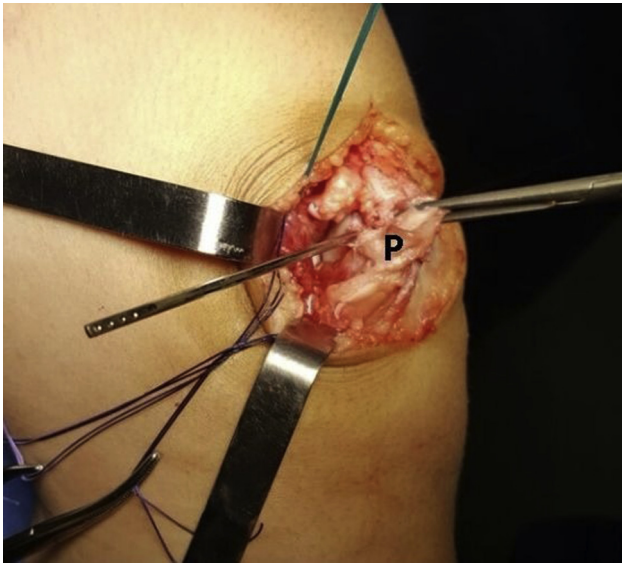


Fig 5. Left side knee. Two transosseous sutures are placed from medial to lateral on the patella (P).

distal to the adductor tubercle.^{23,26} In the present surgical technique, we believe to identify the deep portion of the MPFL as it courses to the femoral attachment and capsule. To reach and identify the deep portion of the MPFL sharp dissection near the patellar insertion, separating the VMO as it blends with the MPFL and capsule is necessary. Separating these structures may be difficult at the level of the distal border of the VMO, but at the level of the middle and distal third of the patella, the medial retinaculum and capsule are easily separated and can serve as parameter for dissection. Once the layers are separated, the medial capsule is incised at the patellar border and a Kocher clamp is placed on the capsule to

apply traction and allow better identification of a cord structure, which we believe to be the deep portion of the MPFL.

The patellomeniscal ligament (PML) is described to be a ligament situated in layer III extending from the inferior medial pole of the patella to a wide distal insertion on the anterior horn of the medial meniscus.²⁶ This ligament is the second most important restrictor to lateral dislocation of the patella,²⁷ and this explains a frequently observed tear at the inferior medial border of the patella at the insertion of the PML in acute patellar dislocations.²⁶ In some cases when the medial capsule is tensioned the PML can be found just distal to the MPFL and can also have sutures placed to reinforce an MPFL retensioning repair if the surgeon judges necessary.

In the present technique, the critical step is to separate the VMO from the capsule and deep portion of the MPFL to allow a proper identification of the deep portion of the MPFL, a cord structure which is commonly observed to be slack but present. Separation and identification of this cord structure maybe difficult when the approach is performed for the first time, in extremely acute cases with extensive disruption of the medial structures, and the MPFL may be significantly thinned in recurrent dislocation cases. In these situations, the authors recommend being prepared for a traditional MPFL reconstruction.

As with an MPFL reconstruction, in the present surgical technique, care must be taken not to over-medialize the patella. We recommend the repaired MPFL to be tightened and the transosseous sutures tied at 60° to 70° of knee flexion to optimize and restore the anatomical patellofemoral contact pressure.²⁸ After MPFL tightening and before the VMO is reinserted and

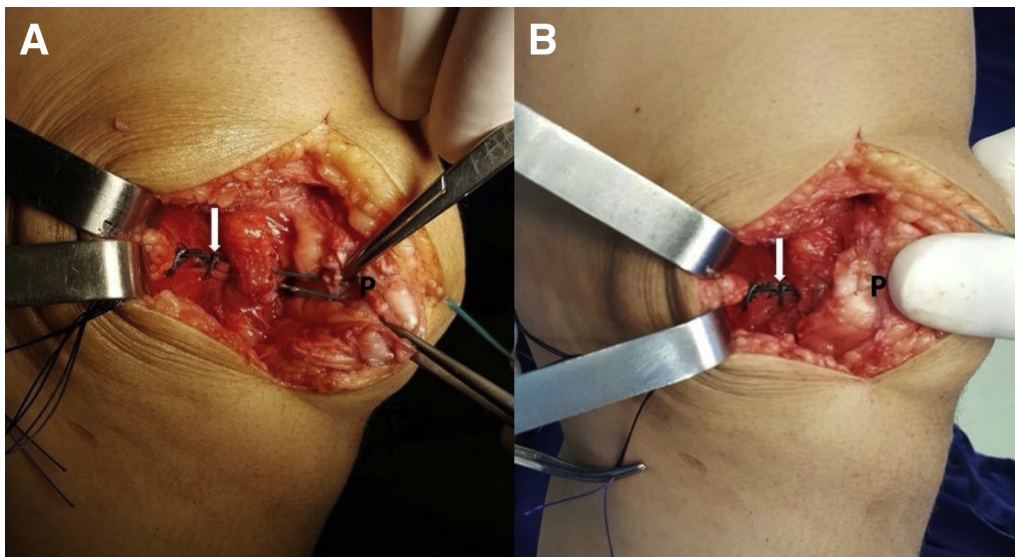


Fig 6. Left side knee. (A) The knee is placed in 70° of flexion, and (B) the transosseous sutures are tensioned and tied. (P, patella.)

Table 1. Pearls and Pitfalls When Performing an MPFL Retensioning Repair

Pearls
1. Preserve the capsule (layer III) when incising the medial retinaculum (layer II) at the medial border of the patella. The separation from the capsule is easier when begun below the distal border of the vastus medialis and MPFL level, or above this level by releasing the tendinous portion of the vastus medialis
2. To better identify the deep MPFL cord structure, incise the capsule at the medial border of the patella and place a Kocher clamp on the capsule at the MPFL level to tighten this structure and allow better identification of this cord
3. Adequate MPFL tension is better obtained by tying the transosseous sutures with 45° to 70° of knee flexion
4. Check for patellar stability and MPFL tension after fixation and before reinsertion of the vastus medialis and medial retinaculum
Pitfalls
1. The distal border of the vastus medialis, the MPFL, and the capsule fuse together to insert at the patella, and separation of these layers makes dissection difficult
2. Tensioning and tying the transosseous sutures with the knee in extension can overmedialize the patella

MPFL, medial patellofemoral ligament.

sutured to the patella, patellar mobility and lateral displacement of the patella with 30° of knee flexion, in the same position as the patellar apprehension test, is performed to check for adequate MPFL tension/sufficiency, knee flexion, and patellar tracking and stability.

The VMO is suggested to have not only a direct dynamic stabilization function by pulling the patella medially, but an indirect dynamic stabilizing function through its attachment to the MPFL near the patella.^{23,24} Tuxoe et al.²⁶ found the MPFL to be rich in nerve endings and postulated the MPFL to be an important structure involved in proprioception, neuromuscular balance, and coordination. In the present surgical technique, the slackened deep portion of the MPFL is tensioned and may restore a more adequate proprioceptive reflex chain to avoid recurrent patellar instability. Although the VMO is attached to the MPFL near the patellar insertion, we do not recommend placing several sutures attaching the distal border

Table 2. Advantages and Disadvantages When Performing an MPFL Retensioning Repair

Advantages
1. Simple technique with no hardware being used
2. Does not have a donor site morbidity of an MPFL reconstruction
3. Can be performed in children without growth plate concerns
Disadvantages
1. Separating layers II and III and identifying the MPFL cord structure may be difficult when the approach is performed for the first time or in extremely acute cases with extensive disruption of the medial structures
2. The MPFL may be significantly thinned in recurrent dislocation cases and may not resist substantially to forceful repeated lateralization forces, and MPFL reconstruction may be considered along with other patellar stabilization procedures

MPFL, medial patellofemoral ligament.

of the VMO to the MPFL as recommended in surgical MPFL reconstruction techniques,^{29,30} as we postulate that too many stitches may cause a progressive slackening of the repaired MPFL by constant pulling of the VMO. The VMO is not advanced onto the dorsal patellar surface, but sutured to its previous patellar position to repair as anatomically as possible the MPFL/VMO complex.

The surgical technique described in this Technical Note is an anatomical retensioning repair of the MPFL aiming to restore patellar stability. The present technique is simple with no hardware being used, does not have the donor site morbidity of an MPFL reconstruction, and can be performed in children without having growth plate concerns. The advantages and disadvantages of this technique are described in Table 2.

References

1. Philippot R, Boyer B, Testa R, Farizon F, Moyon B. The role of the medial ligamentous structures on patellar tracking during knee flexion. *Knee Surg Sports Traumatol Arthrosc* 2012;20:331-336.
2. Stephen JM, Kader D, Lumpaopong P, Deehan DJ, Amis AA. Sectioning the medial patellofemoral ligament alters patellofemoral joint kinematics and contact mechanics. *J Orthop Res* 2013;31:1423-1429.
3. Stefancin JJ, Parker RD. First-time traumatic patellar dislocation: A systematic review. *Clin Orthop Relat Res* 2007;455:93-101.
4. Maenpaa H, Lehto MU. Patellar dislocation. The long-term results of nonoperative management in 100 patients. *Am J Sports Med* 1997;25:213-217.
5. Lewallen LW, McIntosh AL, Dahm DL. Predictors of recurrent instability after acute patellofemoral dislocation in pediatric and adolescent patients. *Am J Sports Med* 2013;41:575-581.
6. Nwachukwu BU, So C, Schairer WW, Green DW, Dodwell ER. Surgical versus conservative management of acute patellar dislocation in children and adolescents: A systematic review. *Knee Surg Sports Traumatol Arthrosc* 2016;24:760-767.
7. Ahmad CS, Stein BE, Matuz D, Henry JH. Immediate surgical repair of the medial patellar stabilizers for acute patellar dislocation. A review of eight cases. *Am J Sports Med* 2000;28:804-810.
8. Buchner M, Baudendistel B, Sabo D, Schmitt H. Acute traumatic primary patellar dislocation: Long-term results comparing conservative and surgical treatment. *Clin J Sports Med* 2005;15:62-66.
9. Fukushima K, Horaguchi T, Okano T, Yoshimatsu T, Saito A, Ryu J. Patellar dislocation: Arthroscopic patellar stabilization with anchor sutures. *Arthroscopy* 2004;20:761-764.
10. Harilainen A, Sandelin J. Prospective long-term results of operative treatment in primary dislocation of the patella. *Knee Surg Sports Traumatol Arthrosc* 1993;1:100-103.
11. Haspl M, Cicak N, Klobucar H, Pecina M. Fully arthroscopic stabilization of the patella. *Arthroscopy* 2002;18:E2.

12. Cash JD, Hughston JC. Treatment of acute patellar dislocation. *Am J Sports Med* 1988;16:244-249.
13. Coons DA, Barber FA. Thermal medial retinaculum shrinkage and lateral release for the treatment of recurrent patellar instability. *Arthroscopy* 2006;22:166-171.
14. Dainer RD, Barrack RL, Buckley SL, Alexander AH. Arthroscopic treatment of acute patellar dislocations. *Arthroscopy* 1988;4:267-271.
15. Nikku R, Nietosvaara Y, Aalto K, Kallio PE. Operative treatment of primary patellar dislocation does not improve medium-term outcome: A 7-year follow-up report and risk analysis of 127 randomized patients. *Acta Orthop* 2005;76:699-704.
16. Vainionpaa S, Laasonen E, Silvennoinen T, Vasenius J, Rokkanen P. Acute dislocation of the patella. A prospective review of operative treatment. *J Bone Joint Surg Br* 1990;72:366-369.
17. Yamamoto RK. Arthroscopic repair of the medial retinaculum and capsule in acute patellar dislocations. *Arthroscopy* 1986;2:125-131.
18. Zeichen J, Lobenhoffer P, Bosch U, Friedemann K, Tscherne H. [Interim results of surgical therapy of patellar dislocation by Insall proximal reconstruction]. *Unfallchirurg* 1998;101:446-453 (in German).
19. Azimi H, Anakwenze O. Medial patellofemoral ligament reconstruction using dual patella docking technique. *Arthrosc Tech* 2017;6:e2093-e2100.
20. Monllau JC, Erquicia JI, Ibanez M, et al. Reconstruction of the medial patellofemoral ligament. *Arthrosc Tech* 2017;6:e1471-e1476.
21. Saccomanno MF, Sircana G, Fodale M, Donati F, Milano G. Surgical versus conservative treatment of primary patellar dislocation. A systematic review and meta-analysis. *Int Orthop* 2016;40:2277-2287.
22. Warren LF, Marshall JL. The supporting structures and layers on the medial side of the knee: An anatomical analysis. *J Bone Joint Surg Am* 1979;61:56-62.
23. Nomura E, Inoue M, Osada N. Anatomical analysis of the medial patellofemoral ligament of the knee, especially the femoral attachment. *Knee Surg Sports Traumatol Arthrosc* 2005;13:510-515.
24. Panagiotopoulos E, Strzelczyk P, Herrmann M, Scuderi G. Cadaveric study on static medial patellar stabilizers: The dynamizing role of the vastus medialis obliquus on medial patellofemoral ligament. *Knee Surg Sports Traumatol Arthrosc* 2006;14:7-12.
25. Amis AA, Firer P, Mountney J, Senavongse W, Thomas NP. Anatomy and biomechanics of the medial patellofemoral ligament. *Knee* 2003;10:215-220.
26. Tuxoe JI, Teir M, Winge S, Nielsen PL. The medial patellofemoral ligament: A dissection study. *Knee Surg Sports Traumatol Arthrosc* 2002;10:138-140.
27. Desio SM, Burks RT, Bachus KN. Soft tissue restraints to lateral patellar translation in the human knee. *Am J Sports Med* 1998;26:59-65.
28. Lorbach O, Zumbansen N, Kieb M, et al. Medial patellofemoral ligament reconstruction: Impact of knee flexion angle during graft fixation on dynamic patellofemoral contact pressure—A biomechanical study. *Arthroscopy* 2018;34:1072-1082.
29. Wang F, Kang HJ, Chen BC, Chen W, Su YL, Zhang YZ. Combination of medial patellofemoral ligament reconstruction with vastus medialis advancement for chronic patellar dislocation. *Chin Med J (Engl)* 2010;123:3024-3029.
30. Ahmad CS, Brown GD, Shubin Stein BE. The docking technique for medial patellofemoral ligament reconstruction: Surgical technique and clinical outcome. *Am J Sports Med* 2009;37:2021-2027.