

ISAR-PEBIS (Paclitaxel-Eluting Balloon Versus Conventional Balloon Angioplasty for In-Stent Restenosis of Superficial Femoral Artery): A Randomized Trial

Ilka Ott, MD; Salvatore Cassese, MD, PhD; Philipp Groha, MD; Birgit Steppich, MD; Felix Voll, MD; Martin Hadamitzky, MD; Tareq Ibrahim, MD; Sebastian Kufner, MD; Karl Dewitz, Cand med; Theresa Wittmann, Cand med; Albert Markus Kasel, MD; Karl-Ludwig Laugwitz, MD; Heribert Schunkert, MD; Adnan Kastrati, MD; Massimiliano Fusaro, MD

Background—Paclitaxel-eluting balloon (PEB) angioplasty has superior efficacy compared with conventional balloon angioplasty (BA) for de novo lesions of superficial femoral artery (SFA). Studies investigating the angiographic and clinical performance of PEB angioplasty versus BA for in-stent restenosis of SFA are limited. We performed a randomized trial to investigate angiographic and clinical performance of PEB versus BA for in-stent restenosis of SFA.

Methods and Results—Patients with symptomatic in-stent restenosis of SFA were randomly assigned to either PEB or BA at 2 centers in Munich, Germany. The primary end point was the percentage diameter stenosis at 6- to 8-month follow-up angiography. Secondary end points were the rate of binary restenosis at follow-up angiography and target lesion revascularization, target vessel thrombosis, ipsilateral amputation, bypass surgery of the affected limb, and all-cause mortality at 24-month follow-up. Seventy patients were assigned to PEB (n=36) or BA (n=34). Mean lesion length was 139 ± 67 mm, and roughly one third of lesions were completely occluded at the time of the index procedure. At control angiography, the percentage diameter stenosis ($44\pm 33\%$ versus $65\pm 33\%$, $P=0.01$) and binary restenosis were significantly reduced with PEB versus BA (30% versus 59%, $P=0.03$). At 24-month follow-up, PEB was associated with a significant reduction of target lesion revascularization in comparison to BA (19% versus 50%, $P=0.007$). There was no difference with respect to other outcomes of interest.

Conclusions—In patients with in-stent restenosis of SFA, a percutaneous therapy with PEB compared with BA has superior angiographic performance at 6 to 8 months and improved clinical efficacy up to 24-month follow-up.

Clinical Trial Registration—URL: <http://www.clinicaltrials.gov>. Unique identifier: NCT01083394. (*J Am Heart Assoc.* 2017;6:e006321. DOI: 10.1161/JAHA.117.006321.)

Key Words: in-stent restenosis • paclitaxel-eluting balloon • peripheral artery disease

A variable degree of obstruction at the level of superficial femoral artery (SFA) is a common finding in patients with atherosclerotic disease of peripheral vessels. Guidelines recommend endovascular therapy as a first-line option for SFA disease. Conventional balloon angioplasty (BA),

peripheral stents (with or without release of antiproliferative drugs), atherectomy devices, and paclitaxel-eluting balloon (PEB) represent valuable options as stand-alone therapies or in combination for patients with SFA disease.¹

Despite the favorable acute mechanical results with contemporary endovascular therapies for SFA disease, the rate of restenosis (vessel narrowing at the site of a treated segment) is as high as 70% after BA and 50% after stenting.² PEB represents a breakthrough in the percutaneous treatment of SFA disease by providing local delivery of a target-specific antirestenotic drug without leaving permanent implants behind. Although recent data lend support for superior efficacy of PEB versus BA in de novo lesions of SFA,³ the angiographic and clinical outcomes of PEB versus BA as therapeutic options for in-stent restenosis (ISR) of SFA remain poorly studied.⁴ In particular, a randomized trial investigating the angiographic and clinical performance of PEB versus BA for ISR of SFA has yet to be performed.

From the Deutsches Herzzentrum München, Technische Universität München, Munich, Germany (I.O., S.C., P.G., B.S., F.V., M.H., S.K., K.D., T.W., A.M.K., H.S., A.K., M.F.); 1. Medizinische Klinik, Klinikum rechts der Isar, Technische Universität München, Munich, Germany (T.I., K.-L.L.); DZHK (German Centre for Cardiovascular Research), partner site Munich Heart Alliance, Munich, Germany (K.-L.L., H.S., A.K.).

Correspondence to: Ilka Ott, MD, Deutsches Herzzentrum München, Technische Universität München, Lazarettstrasse 36, 80636, Munich, Germany. E-mail: ott@dhm.mhn.de

Received April 14, 2017; accepted June 21, 2017.

© 2017 The Authors. Published on behalf of the American Heart Association, Inc., by Wiley. This is an open access article under the terms of the Creative Commons Attribution-NonCommercial-NoDerivs License, which permits use and distribution in any medium, provided the original work is properly cited, the use is non-commercial and no modifications or adaptations are made.

Clinical Perspective

What Is New?

- In this randomized controlled trial, treatment of in-stent restenosis of superficial femoral artery lesions with paclitaxel-eluting balloon angioplasty was superior to balloon angioplasty regarding angiographic diameter stenosis at 6 months and target lesion revascularization at 24 months.

What Are the Clinical Implications?

- Paclitaxel-eluting balloon angioplasty should be the treatment of choice for superficial femoral artery in-stent restenosis.

Against this background, we performed a randomized trial in which patients with symptomatic ISR of SFA were assigned to either PEB or BA and received a follow-up angiography at 6 to 8 months and clinical surveillance at 6- and 24-month follow-up.

Methods

Population

The ISAR-PEBIS (Paclitaxel-Eluting Balloon Versus Conventional Balloon Angioplasty for In-Stent Restenosis of Superficial Femoral Artery) trial was a prospective, randomized, active-controlled trial performed at 2 centers and designed to assess the angiographic and clinical performance of PEB versus BA for ISR of SFA. The trial was approved by the local ethics committee and was carried out in accordance with the Declaration of Helsinki. All patients provided written informed consent before inclusion in the trial.

The criteria for angiographic inclusion comprised the evidence of symptomatic ISR >70% or occlusion of SFA at the stented site. Restenotic lesions of SFA were classified according to Tosaka et al by visual estimate at baseline angiography,⁵ as follows: class I, focal (≤ 50 mm in length; ISR at the stent body, the stent edge, or a combination of these sites); class II, diffuse (>50 mm in length; ISR not only with stent body lesions but also stent edge lesions); and class III, totally occluded ISR. Exclusion criteria were acute ischemia and/or acute thrombosis of the SFA, untreated ipsilateral iliac or popliteal artery stenosis >70%, severe renal insufficiency, life expectancy <1 year, and any contraindication to study medications. Allocation to treatments was accomplished by means of sealed, opaque envelopes containing a computer-generated sequence after the decision to proceed with the intervention. Patients who fulfilled all inclusion criteria and none of the exclusion criteria were randomized at a 1:1 ratio to treatment with PEB or BA.

Interventions

Endovascular procedures were performed by means of an antegrade or contralateral approach using a 6F or 7F introducer sheath. After wiring the lesion, predilation was performed in both study groups with a standard balloon catheter inflated for 2 minutes with a vessel:balloon diameter ratio of 1:1. Those patients assigned to treatment with PEB received an additional dilation with the IN.PACT Admiral (Invatec/Medtronic) balloon catheter. New-generation self-expanding nitinol stents were implanted in patients with >50% residual stenosis or flow limiting dissection at final angiography (bailout stenting). Technical success was defined as residual stenosis <30% at final angiography.

A loading dose of clopidogrel (600 mg) was administered to all clopidogrel-naïve patients before angiography. Immediately after the decision to perform the intervention, patients were given 500 mg aspirin intravenously and 5000 U heparin intra-arterially. After the intervention, all patients received aspirin 100 mg per day indefinitely and clopidogrel 75 mg per day for at least 6 months.

End Points

The primary end point of the trial was the percentage diameter stenosis (DS), as measured by repeat angiography at 6 to 8 months. The first angiogram (at the time of randomization) as well as the repeat angiogram (primary end point evaluation) were performed in identical projections and transmitted to the Imaging Core Laboratory to be quantitatively evaluated. The target lesion was identified by the vascular anatomy, bone landmarks, stent struts, and a ruler placed under the patient's leg. The angiographic imaging of the target lesion was performed in accordance with the Quantitative Vascular Analysis Core Laboratory guidelines. All analyses were performed in the stent area and in the "in-segment" area.

Secondary end points of the trial were binary restenosis rate, as measured at repeat angiography; target lesion revascularization (TLR), target vessel thrombosis, ipsilateral amputation, or bypass surgery of the affected limb; and all-cause mortality at 24 months. The repeat angiography was scheduled per protocol at 6 to 8 months. All TLR were clinically driven and angiographically confirmed before treatment. All patients were evaluated at 6 and 24 months by telephone contact or office visit. The local research coordinators collected and forwarded the data to the Clinical Data Management Center (ISAResearch Center, Munich, Germany). Routine checking of obtained data against source documentation ensured data quality.

Statistical Analysis and Sample Size Calculation

Sample size calculation for the present trial was based on the following assumptions regarding the primary end point: To

demonstrate a reduction in percentage DS from 60% ($\pm 40\%$) after BA to 30% ($\pm 40\%$) after PEB with a 2-sided α level of 0.05 and power of 80%, the number of patients needed was 29 per group. To compensate for possible missing angiographies and withdrawals, 70 patients (35 per groups) were to be included. Continuous data are presented as mean \pm SD. Categorical data are presented as counts and proportions. Data distribution was tested for normality using the Kolmogorov–Smirnov test for goodness of fit. For patient-level data, differences between groups were checked for significance using the Student *t* test or the Wilcoxon rank sum test (continuous data) or using the χ^2 or Fisher exact test if the expected cell value was <5 (categorical variables). Event-free survival was assessed using the methods of Kaplan–Meier. Rates of adverse events were shown as Kaplan–Meier estimates, and *P* values were calculated from univariate Cox proportional hazards models. A 2-sided $P < 0.05$ was considered to indicate statistical significance. Statistical software IBM SPSS version 22 was used for analysis.

Results

Between April 2010 and December 2013, 70 patients with symptomatic (Rutherford classification 2–5) ISR of SFA were enrolled and randomized to receive either PEB ($n=36$) or BA ($n=34$) at 2 German centers. The flow diagram of the study is detailed in Figure 1.

Baseline clinical (Table 1) and angiographic (Table 2) characteristics were well balanced between treatment groups. The majority of patients were male and presented with hypertension and dyslipidemia, and roughly one third had diabetes mellitus. The overwhelming majority of patients complained of severe claudication (Rutherford class ≥ 3).

Lesion length did not differ between PEB and BA treatment groups (132 ± 65 and 146 ± 69 mm, respectively). Notably, there was a numerically higher prevalence of Tosaka class II and III lesions in patients treated with PEB versus BA, although the difference between groups was not significant ($P=0.14$).

All patients received the treatments assigned without crossover between arms. A total of 11 patients underwent bailout stenting based on angiographic evidence of flow limiting dissections after dilation (6% versus 26%, PEB versus BA, respectively; $P=0.02$). In 1 patient assigned to BA, an acute thrombotic occlusion after bailout stenting was successfully treated with thrombus aspiration. Technical and procedural success was achieved in all procedures.

Angiographic Outcomes

Follow-up angiography was obtained in 54 patients (77%). The percentage DS at follow-up angiography—the primary end point of the study—was significantly reduced in lesions

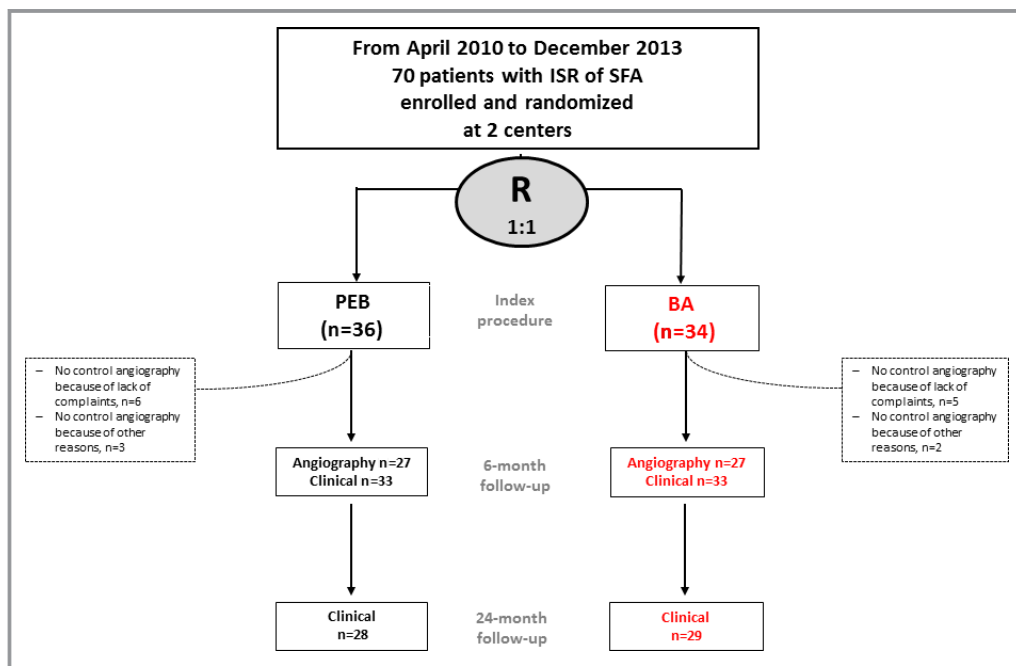


Figure 1. Flow diagram of the study. Enrollment by random assignment (R), death (all-cause), and loss to follow-up over 6 months are shown. BA indicates balloon angioplasty; ISR, in-stent restenosis; PEB, paclitaxel-eluting balloon; SFA, superficial femoral artery.

Table 1. Clinical Characteristics

	PEB (n=36)	BA (n=34)
Age, y	70±10	68±10
Female sex	12 (33)	10 (30)
Hypertension	33 (92)	30 (88)
Dyslipidemia	35 (97)	33 (97)
Diabetes mellitus	12 (33)	12 (35)
Smoking habit	21 (58)	24 (71)
Coronary artery disease	17 (47)	16 (47)
BMI, kg/m ²	27±4	28±4
GFR, mL/min	73±33	80±23
ABI	0.6±0.3	0.7±0.2
Rutherford classification		
Class 2	1 (3)	0
Class 3	34 (94)	33 (97)
Class 4	0	0
Class 5	1 (3)	1 (3)

Values are n (%) or mean±SD. ABI indicates ankle brachial index; BA, balloon angioplasty; BMI, body mass index; GFR, glomerular filtration rate; PEB, paclitaxel-eluting balloon.

treated with PEB compared with those treated with BA ($44\pm33\%$ versus $65\pm33\%$, $P=0.01$; Table 3). Consistently, binary restenosis was significantly reduced with PEB in comparison to BA (30% after PEB and 59% after BA; $P=0.03$).

Table 2. Angiographic Characteristics

	PEB (n=36)	BA (n=34)
Lesion length, mm	132±65	146±69
In-stent restenosis classification		
Tosaka class I	10 (28)	17 (50)
Tosaka class II	13 (36)	7 (21)
Tosaka class III	13 (36)	10 (29)
RVD before, mm	4.8±1.3	4.8±1.2
MLD before, mm	1±0.8	0.8±0.7
DS before, %	80±16	80±16
MLD after, mm	4.9±1.1	4.6±1.2
DS after, %	23±11	18±10
Bailout stenting	2 (6)	9 (26)
Thrombus aspiration	0	1 (3)
Technical success	36 (100)	34 (100)
Procedural success	36 (100)	34 (100)

Values are n (%) or mean±SD. BA indicates balloon angioplasty; DS, diameter stenosis; MLD, minimal lumen diameter; PEB, paclitaxel-eluting balloon; RVD, reference vessel diameter.

Table 3. Angiographic Outcomes at 6- to 8-Month Surveillance

	PEB (n=27)	BA (n=27)	P Value
RVD, mm	5±1.1	4.7±0.9	0.35
MLD, mm	2.8±1.7	1.6±1.7	0.01
DS, %	44±33	65±33	0.01
Binary restenosis, %	8 (30%)	16 (59%)	0.03

Values are n (%) or mean±SD. BA indicates balloon angioplasty; DS, diameter stenosis; MLD, minimal lumen diameter; PEB, paclitaxel-eluting balloon; RVD, reference vessel diameter.

Clinical Outcomes

Mean duration of clinical follow-up was 26 months in both groups.

TLR was significantly reduced in patients treated with PEB compared with those treated with BA. Interestingly, the superior clinical efficacy of PEB compared with BA emerged 6 months after the index procedure (0% versus 21%, $P=0.004$) and persisted to 24-month follow-up (19% versus 50%, $P=0.007$; Table 4, Figure 2). For instance, all but 1 TLR performed at time of control angiography were clinically driven; indeed, 4 patients complained of Rutherford class 3, 2 patients complained of Rutherford class 2, and 1 patient presented an asymptomatic occlusive restenosis at routine duplex ultrasound.⁶ In all cases, TLR was performed percutaneously without requirement for bypass surgery in any treatment group.

One patient experienced a target vessel thrombosis 382 days after PEB therapy and was successfully treated

Table 4. Clinical Outcomes at 6- and 24-Month Follow-up

	PEB (n=36)	BA (n=34)	P Value
6 months			
TLR	0	7 (21)	0.004
Target vessel thrombosis
Ipsilateral amputation
Target vessel bypass
Death	1 (2)	0	0.33
24 months			
TLR	7 (19)	17 (50)	0.007
Target vessel thrombosis	1 (3)	0	0.33
Ipsilateral amputation
Target vessel bypass
Death	3 (8)	0	0.24

Values are n (Kaplan–Meier estimates) or mean±SD. BA indicates balloon angioplasty; PEB, paclitaxel-eluting balloon; TLR, target lesion revascularization.

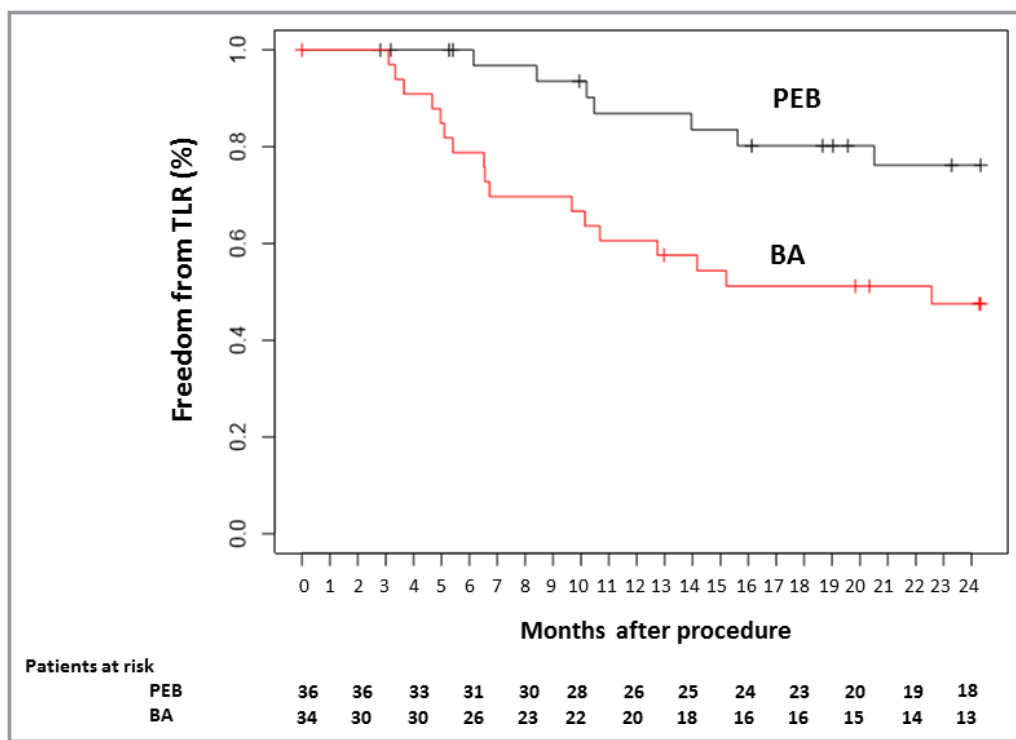


Figure 2. Survival free from target lesion revascularization (TLR) out to 24-month follow-up. Kaplan–Meier curves for patients assigned to receive paclitaxel-eluting balloon (PEB; black line) or balloon angioplasty (BA; red line).

with thrombus aspiration and stenting. Antiplatelet therapy at the time of target vessel thrombosis consisted of aspirin only.

There were no ipsilateral amputations throughout the study period in any treatment group.

Three deaths occurred among patients treated with PEB, at 84, 162, and 483 days after index procedure: One sudden death (unknown reason), 1 cardiac death, and 1 death due to multiorgan failure and sepsis were recorded. No death was reported among patients treated with BA.

Discussion

ISAR-PEBIS was a 2-center, randomized trial that scheduled a control angiography at 6 to 8 months and clinical follow-up at 24 months for 70 participants with ISR of SFA who were randomly assigned to percutaneous therapy with either PEB or BA.

The main results of the trial can be summarized as follows: PEB therapy is associated with antirestenotic efficacy superior to that of BA, due to a lower percentage DS at repeat angiography and less TLR at 24-month follow-up, without safety concerns.

Although the widespread use of new-generation, self-expanding, nitinol stents has reduced the technical shortcomings associated with BA for SFA disease, lumen

renarrowing at the stented level continues to occur and represents a challenging clinical problem.⁵ Multiple treatment options such as BA, repeat stenting, and debulking have been investigated in patients with ISR of SFA, but there is no established best treatment strategy for these patients. Previous data found PEB superior to BA for de novo SFA lesions.³ In contrast, the efficacy of PEB in patients presenting with ISR of SFA remains poorly studied. A small-sample registry of patients with ISR of SFA treated with PEB angioplasty at a single institution reported a primary patency of 92.1% at 1 year.⁷ Another study comparing 2 cohorts of diabetic patients with ISR of SFA treated at a single center with either PEB or BA reported a primary patency after PEB as high as 80.5% at 1 year.⁸

Notably, 2 randomized trials comparing 2 different PEB technologies versus BA for ISR of SFA led to inconsistent results. The FAIR (Femoral Artery In-Stent Restenosis) trial showed a reduction in recurrent restenosis assessed by ultrasound at 6 months and lower risk of TLR at 1 year after a percutaneous therapy with PEB versus BA.⁹ In contrast, the PACUBA I (Paclitaxel Balloon Versus Standard Balloon in In-Stent Restenoses of the Superficial Femoral Artery) trial showed improved primary patency rates but no benefit in terms of TLR at 1 year after a percutaneous therapy with PEB versus BA.¹⁰ The conflicting results of these trials are likely

attributable to the different clinical and angiographic complexity of the participants enrolled, the variable proportions of patient dropout at follow-up, and the heterogeneity of PEB technologies. Indeed, differences in drug dose, excipient to load the antiproliferative drug on the balloon surface, coating process, and catheter backbone may affect the amount of drug actually delivered into the vessel wall and the consequent neointima suppression of PEB. In this regard, no class effect among PEB platforms can be assumed.¹¹

We present the results of the ISAR-PEBIS study, the first randomized trial investigating the performance of PEB versus BA for ISR of SFA out to 2-year follow-up. We found more effective inhibition of neointima proliferation at 6- to 8-month angiography and reduction in terms of TLR at 24 months after percutaneous treatment with PEB versus BA. These results merit careful discussion.

First, by delivering an antiproliferative medication without the requirement of an additional layer of stent, PEB should be preferred over other percutaneous strategies, such as plaque removal devices and stents. Indeed, the use of debulking devices, such as laser atherectomy, as a stand-alone therapy against BA has been associated with inconsistent midterm results.¹² Similarly, although drug-coated¹³ or covered stents¹⁴ showed acceptable patency up to 1-year follow-up, the progressive shrinkage of the vessel lumen by multiple stent layers may potentially impair the vascular compliance and increase the risk of recurrent ISR.¹⁵

Second, the sustained efficacy with PEB versus BA in patients presenting with ISR of SFA in this trial is reassuring. Indeed, recent observations demonstrated a late “catch-up” phenomenon 2 years after PEB for ISR of SFA¹⁶ and a similar risk of reintervention of the treated limbs 3 years after either PEB or BA therapy.¹⁷ Preclinical models of restenosis after peripheral artery stenting have demonstrated that the permanent overstretch of the arterial wall with subsequent persistent neointimal growth due to metallic implants plays a pivotal role in ISR. In this respect, the synergy of different endovascular technologies holds promise¹⁸ and should be investigated in future randomized trials.

Third, in this trial, the number of deaths was higher among patients assigned to PEB compared with those assigned to BA, although this difference did not reach the threshold of statistical significance. Other studies have documented potential safety issues associated with the use of PEB in patients with advanced stages of peripheral artery disease¹⁹; however, the present study was unable to detect differences with regard to rare outcomes among treatment groups, and the play of chance cannot be excluded. Of note, all deaths reported in this trial were not related to peripheral artery disease.

Finally, in this trial, bailout stenting was less frequent after PEB compared with BA. A fairly higher percentage of bailout

stenting in patients treated with BA is a common finding in comparative studies against PEB for de novo or restenotic lesions.^{3,4} On the one hand, in this trial, operators were not blinded to assigned treatments, and the higher threshold for stenting after PEB than after BA therapy may reflect the belief that suboptimal acute results without vascular effects of PEB will translate into unacceptable rates of patency over time. On the other hand, a possible immediate effect of the antirestenotic drug in the PEB group cannot be definitively discarded.

Study Limitations

This study has some limitations. First, despite the favorable results with PEB compared with BA in the overall population, we did not investigate whether certain subgroups of patients or lesions profited the most, given the small sample size available. Second, the analyses regarding clinical outcomes should be interpreted with caution because the study was powered only for the primary angiographic end point. In addition, although PEB reduced the risk of recurrent ISR and TLR compared with BA, any further benefit in terms of walking or functional capacity or quality of life associated with PEB therapy deserves further investigation. Third, there is no consensus regarding the type and duration of antiplatelet therapies after PEB angioplasty. Although patients with ISR of SFA should be regarded as being at higher risk of adverse outcomes, we prescribed per-protocol aspirin and thienopyridines for at least 6 months after the index procedure. A possible treatment effect of PEB dependent on more potent or prolonged antiplatelet therapies deserves further investigation.

Conclusions

In patients with ISR of SFA, a percutaneous therapy with PEB compared with BA displays superior angiographic performance at 6 to 8 months and improved clinical efficacy up to 24-month follow-up.

Acknowledgments

We appreciate the invaluable contribution of the medical and technical staffs operating in the outpatient and inpatient care units and catheterization laboratories of the participating institutions.

Sources of Funding

This was an investigator-initiated industry-independent trial. There was no remuneration for investigators or subjects. Study design and analysis were performed by Deutsches Herzzentrum München, Munich, Germany.

Disclosures

Albert Markus Kasel is a medical consultant for and receives research support from Edwards Lifesciences, outside the submitted work. Adnan Kastrati reports holding patents related to drug-eluting stent technology, outside the submitted work. The other authors declare no potential conflict of interest.

References

- Gerhard-Herman MD, Gornik HL, Barrett C, Barshes NR, Corriere MA, Drachman DE, Fleisher LA, Fowkes FG, Hamburg NM, Kinlay S, Lookstein R, Misra S, Mureebe L, Olin JW, Patel RA, Regensteiner JG, Schanzer A, Shishehbor MH, Stewart KJ, Treat-Jacobson D, Walsh ME. 2016 AHA/ACC guideline on the management of patients with lower extremity peripheral artery disease: a report of the American College of Cardiology/American Heart Association Task Force on Clinical Practice Guidelines. *J Am Coll Cardiol*. 2017;69:e71–e126.
- Schillinger M, Minar E. Claudication: treatment options for femoropopliteal disease. *Prog Cardiovasc Dis*. 2011;54:41–46.
- Cassese S, Byrne RA, Ott I, Ndrepepa G, Nerad M, Kastrati A, Fusaro M. Paclitaxel-coated versus uncoated balloon angioplasty reduces target lesion revascularization in patients with femoropopliteal arterial disease: a meta-analysis of randomized trials. *Circ Cardiovasc Interv*. 2012;5:582–589.
- Cassese S, Ndrepepa G, Kufner S, Byrne RA, Giacoppo D, Ott I, Laugwitz KL, Schunkert H, Kastrati A, Fusaro M. Drug-coated balloon angioplasty for in-stent restenosis of femoropopliteal arteries. A meta-analysis. *EuroIntervention*. 2017;13:1–8. pii: EIJ-D-16-00735. DOI: 10.4244/EIJ-D-16-00735. [Epub ahead of print]
- Tosaka A, Soga Y, Iida O, Ishihara T, Hirano K, Suzuki K, Yokoi H, Nanto S, Nobuyoshi M. Classification and clinical impact of restenosis after femoropopliteal stenting. *J Am Coll Cardiol*. 2012;59:16–23.
- Humphries MD, Pevac WC, Laird JR, Yeo KK, Hedayati N, Dawson DL. Early duplex scanning after infrainguinal endovascular therapy. *J Vasc Surg*. 2011;53:353–358.
- Virga V, Stabile E, Biamino G, Salemme L, Cioppa A, Giugliano G, Tesorio T, Cota L, Popusoi G, Pucciarelli A, Esposito G, Trimarco B, Rubino P. Drug-eluting balloons for the treatment of the superficial femoral artery in-stent restenosis: 2-year follow-up. *JACC Cardiovasc Interv*. 2014;7:411–415.
- Liistro F, Angioli P, Porto I, Ricci L, Ducci K, Grotti S, Falsini G, Venteruzzo G, Turini F, Bellandi G, Bolognese L. Paclitaxel-eluting balloon vs. standard angioplasty to reduce recurrent restenosis in diabetic patients with in-stent restenosis of the superficial femoral and proximal popliteal arteries: the DEBATE-ISR study. *J Endovasc Ther*. 2014;21:1–8.
- Krankenbergh H, Tubler T, Ingwersen M, Schluter M, Scheinert D, Blessing E, Sixt S, Kieback A, Beschorner U, Zeller T. Drug-coated balloon versus standard balloon for superficial femoral artery in-stent restenosis: the randomized femoral artery in-stent restenosis (FAIR) trial. *Circulation*. 2015;132:2230–2236.
- Kinstner CM, Lammer J, Willfort-Ehringer A, Matzek W, Gschwandner M, Javor D, Funovics M, Schoder M, Koppensteiner R, Loewe C, Ristl R, Wolf F. Paclitaxel-eluting balloon versus standard balloon angioplasty in in-stent restenosis of the superficial femoral and proximal popliteal artery: 1-year results of the PACUBA trial. *JACC Cardiovasc Interv*. 2016;9:1386–1392.
- Herdeg C, Oberhoff M, Baumbach A, Blattner A, Axel DI, Schroder S, Heinle H, Karsch KR. Local paclitaxel delivery for the prevention of restenosis: biological effects and efficacy in vivo. *J Am Coll Cardiol*. 2000;35:1969–1976.
- Dippel EJ, Makam P, Kovach R, George JC, Patlola R, Metzger DC, Mena-Hurtado C, Beasley R, Soukas P, Colon-Hernandez PJ, Stark MA, Walker C; Investigators EI. Randomized controlled study of excimer laser atherectomy for treatment of femoropopliteal in-stent restenosis: initial results from the EXCITE ISR trial (excimer laser randomized controlled study for treatment of femoropopliteal in-stent restenosis). *JACC Cardiovasc Interv*. 2015;8:92–101.
- Zeller T, Dake MD, Tepe G, Brechtel K, Noory E, Beschorner U, Kultgen PL, Austermann M, Peeters P. Superiority of stent-grafts for in-stent restenosis with paclitaxel-eluting stents. *JACC Cardiovasc Interv*. 2013;6:274–281.
- Bosiers M, Deloese K, Callaert J, Verbist J, Hendriks J, Lauwers P, Schroe H, Lansink W, Scheinert D, Schmidt A, Zeller T, Beschorner U, Noory E, Torsello G, Austermann M, Peeters P. Superiority of stent-grafts for in-stent restenosis in the superficial femoral artery: twelve-month results from a multicenter randomized trial. *J Endovasc Ther*. 2015;22:1–10.
- Iida O, Takahara M, Soga Y, Hirano K, Yamauchi Y, Zen K, Kawasaki D, Nanto S, Yokoi H, Uematsu M; Investigators Z. The characteristics of in-stent restenosis after drug-eluting stent implantation in femoropopliteal lesions and 1-year prognosis after repeat endovascular therapy for these lesions. *JACC Cardiovasc Interv*. 2016;9:828–834.
- Schmidt A, Piorkowski M, Gorner H, Steiner S, Bausback Y, Scheinert S, Banning-Eichenseer U, Staab H, Branzan D, Varcoe RL, Scheinert D. Drug-coated balloons for complex femoropopliteal lesions: 2-year results of a real-world registry. *JACC Cardiovasc Interv*. 2016;9:715–724.
- Grotti S, Liistro F, Angioli P, Ducci K, Falsini G, Porto I, Ricci L, Venteruzzo G, Turini F, Bellandi G, Bolognese L. Paclitaxel-eluting balloon vs standard angioplasty to reduce restenosis in diabetic patients with in-stent restenosis of the superficial femoral and proximal popliteal arteries: three-year results of the DEBATE-ISR study. *J Endovasc Ther*. 2016;23:52–57.
- Gandini R, Del Giudice C, Merolla S, Morosetti D, Pampana E, Simonetti G. Treatment of chronic SFA in-stent occlusion with combined laser atherectomy and drug-eluting balloon angioplasty in patients with critical limb ischemia: a single-center, prospective, randomized study. *J Endovasc Ther*. 2013;20:805–814.
- Zeller T, Baumgartner I, Scheinert D, Brodmann M, Bosiers M, Micari A, Peeters P, Vermassen F, Landini M, Snead DB, Kent KC, Rocha-Singh KJ; Investigators IPDT. Drug-eluting balloon versus standard balloon angioplasty for infrapopliteal arterial revascularization in critical limb ischemia: 12-month results from the IN.PACT DEEP randomized trial. *J Am Coll Cardiol*. 2014;64:1568–1576.