



Contents lists available at ScienceDirect

International Journal of Surgery Case Reports

journal homepage: www.casereports.com

Stent graft placement for an incidental finding of hepatic artery pseudoaneurysm post hepatectomy, a case report and literature review

Charbel Aoun^{a,*}, Ziad El Rassi^b^a General Surgery Resident, Saint Georges Hospital University Medical Center, Faculty of Medicine, University of Balamand, Beirut, Lebanon^b Professor of Clinical Surgery, General and Digestive Surgery-Oncologic Surgery, Saint Georges Hospital University Medical Center, Faculty of Medicine, University of Balamand, Beirut, Lebanon

ARTICLE INFO

Article history:

Received 30 April 2018

Received in revised form 14 June 2018

Accepted 30 June 2018

Available online 11 July 2018

Keywords:

Pseudoaneurysm

Hepatectomy

Stent graft

Case report

ABSTRACT

INTRODUCTION: Hepatic artery pseudoaneurysm is usually iatrogenic, with bleeding occurring early or late postoperatively.

CASE PRESENTATION: A 61-year-old man with pseudoaneurysm of the common hepatic artery post hepatectomy treated with a stent-graft. The patient was asymptomatic and the pseudoaneurysm appeared incidentally on follow-up. Selective catheterization of the common hepatic artery showed a pseudoaneurysm close to its origin. Covered stent was deployed in the main hepatic artery. Completion angiography showed no residual spasm and adequate patency of the common hepatic artery, with complete exclusion of the pseudoaneurysm.

DISCUSSION: Using stentgraft for pseudoaneurysm management has multiple advantages when compared to other traditional techniques. However, stent placement has its own complications.

CONCLUSION: Stent graft placement post hepatic artery pseudo-aneurysm is safe and effective; however its complications should be evaluated with multidisciplinary team.

© 2018 The Authors. Published by Elsevier Ltd on behalf of IJS Publishing Group Ltd. This is an open access article under the CC BY-NC-ND license (<http://creativecommons.org/licenses/by-nc-nd/4.0/>).

1. Introduction

Hepatic artery pseudoaneurysms are usually iatrogenic [1], with bleeding occurring early or late postoperatively. Several traditional treatment options were used in the past and still seen nowadays [2,3]. In our case report, a covered stent graft was applied with successful outcome. Hepatic artery pseudoaneurysm diagnosis, presentation and treatment options were also reviewed. This case was managed in an academic university medical center. This case report is in line with the SCARE criteria [4].

2. Case report

A 61-year-old man, previously healthy presented with jaundice, dark urine, and clay colored stools starting 1 month prior to presentation. Labs showed elevated direct and total bilirubin of value 6.4 and 8.1 mg/dl respectively. Abdominal magnetic resonance imaging (MRI) was done that showed perihilar cholangiocarcinoma (Klatskin type III – confluence between right and left hepatic ducts), with the mass traversing the left hepatic duct, however distal common bile duct and portal vein patent. No ascites was seen. He

was scheduled for Endoscopic retrograde cholangiopancreatography (ERCP) that showed complete obstruction under hilum. Then sphincterotomy and dilation with a balloon were done. During ERCP, biopsies were taken with brushing and left plastic stent and right metallic stent were placed. Biopsy result showed adenocarcinoma moderately differentiated. Even after ERCP and placement of 2 stents, the bilirubin continued to elevate reaching 9.7 and 11.4 mg/dl for direct and total bilirubin respectively. So the decision was taken for left hepatectomy, cholecystectomy and right hepatico-jejunal Roux-en-Y anastomosis.

On postoperative day 30, a control computed tomography scan was done that showed incidental finding of the pseudoaneurysm abutting the hepatico-jejunal anastomosis (Fig. 1).

Diagnostic angiography of the celiac axis, followed by selective catheterization of the common hepatic artery showed a pseudoaneurysm close to the origin of the main hepatic artery (Fig. 2).

To avoid the possibility of hepatic infarction due to microcoil migration or the possible risk of delayed refilling, we opted for the deployment of a covered stent into the main hepatic artery, as treatment to the main hepatic artery pseudo-aneurysm.

A retrograde puncture of the right common femoral artery was done, followed by the insertion of a 5 French vascular sheath. Selective catheterization and angiography of the celiac axis was done followed by cannulation of the hepatic artery and exchange for a 6 French sheath. Contrast injection demonstrated markedly

* Corresponding author.

E-mail address: charbelaoun28@gmail.com (C. Aoun).

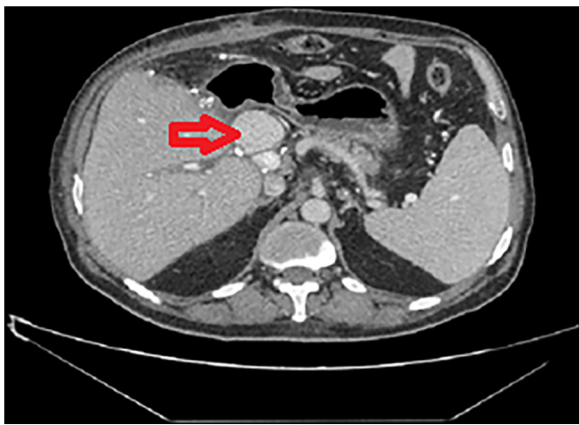

Fig. 1. Pseudoaneurysm (arrow) abutting the hepatico-jejunal anastomosis.

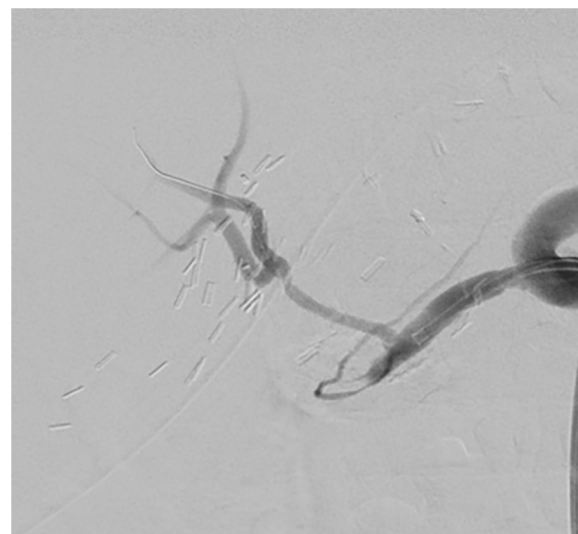


Fig. 4. Angiography showing adequate patency of the main hepatic artery, with sealing of the pseudoaneurysm.

spastic main hepatic artery with a large pseudo-aneurysm, feeding from a defect in the mid aspect of the main hepatic artery. A 3.5 mm × 16 mm covered stent was deployed in the main hepatic artery and its balloon was inflated (Fig. 3). Follow-up contrast injection revealed no residual filling of the pseudo-aneurysm with severe spasm involving the main artery distal to the stent. This was treated with intra-arterial injection of nitroglycerin. Completion angiography showed no residual spasm and adequate patency of the main hepatic artery, with excellent sealing of the pseudo-aneurysm (Fig. 4).

3. Discussion

Hepatic artery pseudoaneurysms (HAP) are rare but potentially lethal complications of hepatic, biliary, and pancreatic interventions. In general, the hepatic artery is the second most frequent

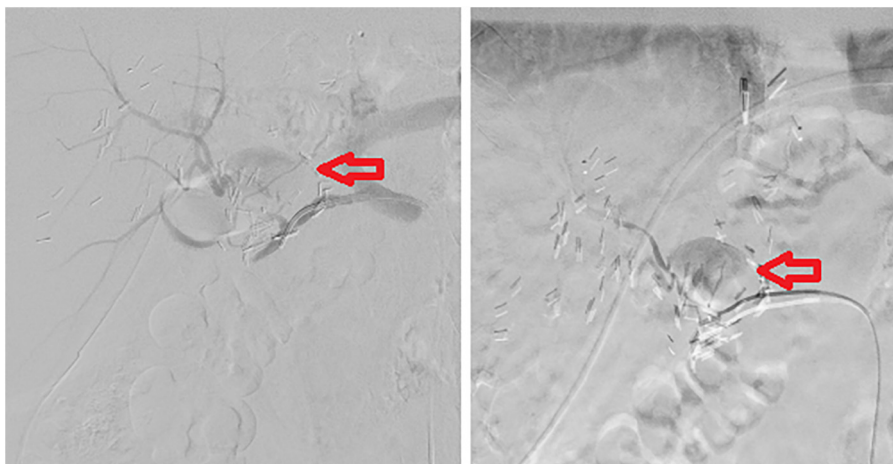


Fig. 2. Selective injection with the catheter tip into the common hepatic artery showing the origin of the pseudoaneurysm (arrow).

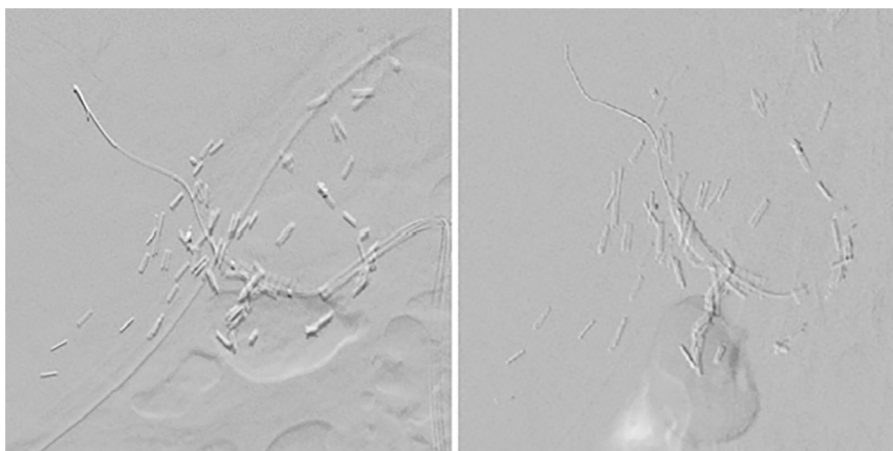


Fig. 3. Deployment of the covered stent.

site of visceral pseudoaneurysms, the splenic artery being the most common [5]. HAP are usually iatrogenic but can be due to trauma or infection. However, when iatrogenic it can be caused by dissection or retraction, clamp injuries or thermal injury due to electrocautery usage [1]. Pseudoaneurysms bleeding can occur early or late post-operatively.

The diagnosis of HAP is usually made by contrast-enhanced CT, which shows the size of the HAP and its relationship to the surrounding structures. Color Doppler and standard ultrasonography also can be used. Selective angiography is the most sensitive test utilized reaching 100% in Tobben et al. series [6].

The presentation of HAP varies from a silent incidental finding to an acute life-threatening hemorrhage caused by rupture [7]. It can resolve spontaneously by thrombosing; however there is a high risk of rupture, which is associated with a high mortality rate, mandating early identification and intervention. Up to 60% of HAPs are clinically silent and found incidentally [8], as in our case.

The traditional treatment of hepatic artery pseudoaneurysms originally consisted of open ligation or excision and vascular reconstruction. However over the years, coil embolization had favorable outcome [2]. By using coils or in combination with glue, the artery is closed. So the aneurysm's blood supply is cut and clot formation is induced [3]. However, the main complications of this procedure include coil migration that can lead to organ infarction, delayed reperfusion of an aneurysm, formation of abscess, and rarely rupture of an aneurysm. Also, hepatic artery closure reduces hepato-portal blood flow and it is inadequate post hepatectomy or in patients with portal hypertension [3,9].

Our technique of using stentgraft for pseudoaneurysm management has multiple advantages when compared to other techniques. In emergency conditions, there is direct bleeding control by excluding the pseudoaneurysm from perfusion. Other advantages include preservation of the arterial flow to the liver maintaining liver function of the remnant part, less morbidity and mortality compared to open techniques, and less fluoroscopy time during intervention [3,9,10].

However, stent placement has its own complications including stent infection, endoleaks and stent thrombosis. Also after stent placement, double-antiplatelet therapy, with all of its complications, is recommended with lifetime aspirin 100 mg/day and clopidogrel 75 mg for a total of 6 weeks [9].

4. Conclusion

Stent graft placement post hepatic artery pseudo-aneurysm is safe and effective; however its complications should be evaluated on every case independently. Large case series with long-term follow-up are required to evaluate and assess its usage indication. General and vascular surgeons with interventional radiologists should be on the case to manage any complication arising from stent placement.

Conflict of interest

Nothing to declare.

Funding

Nothing to declare.

Ethical approval

Approval has been given.

Ethics committee: SGHUMC Research Ethics Committee.

Reference number: H549561.

Consent

Written informed consent was obtained from the patient for publication of this case report and accompanying images. A copy of the written consent is available for review by the Editor-in-Chief of this journal on request.

Author contributions

Charbel Aoun: Data collection and analysis, writing the paper.

Ziad El Rassi: Study concept and design, operating surgeon on the case.

Registration of research studies

Not applicable.

Guarantor

Charbel Aoun.

References

- [1] John Harvey, Herbert Dardik, Theresa Impeduglia, Daniel Woo, Frank DeBernardis, Endovascular management of hepatic artery pseudoaneurysm hemorrhage complicating pancreaticoduodenectomy, *J. Vasc. Surg.* 43 (March (3)) (2006) 613–617, <http://dx.doi.org/10.1016/j.jvs.2005.11.031>, ISSN 0741-5214.
- [2] Alan B. Lumsden, Samer G. Mattar, Robert C. Allen, Emile A. Bacha, Hepatic artery aneurysms: the management of 22 patients, *J. Surg. Res.* 60 (2) (1996) 345–350, <http://dx.doi.org/10.1006/jsre.1996.0055>, ISSN 0022-4804.
- [3] S.F. Pasha, P. Glociczki, A.W. Stanson, P.S. Kamath, Splanchnic artery aneurysms, *Mayo Clin. Proc.* 82 (2007) 472–479.
- [4] R.A. Agha, A.J. Fowler, A. Saetta, I. Barai, S. Rashmohan, D.P. Orgill, The SCARE statement: consensus-based surgical case report guidelines, *Int. J. Surg.* 34 (October) (2016) 180–186, <http://dx.doi.org/10.1016/j.ijsu.2016.08.014>, Published online 2016 Sep 7.
- [5] K.S. Baker, J. Tisnado, S.R. Cho, M.C. Beachley, Splanchnic artery aneurysms and pseudoaneurysms: transcatheter embolization, *Radiology* 163 (1987) 135–139.
- [6] P.J. Tobben, A.B. Zajko, J.H. Sumkin, A. Bowen, C.R. Fuhrman, M.L. Skolnick, et al., Pseudoaneurysms complicating organ transplantation: roles of CT, duplex sonography, and angiography, *Radiology* 169 (1988) 65–70.
- [7] D. Finley, M. Hinojosa, M. Paya, et al., Hepatic artery pseudoaneurysm: a report of seven cases and a review of the literature, *Surg. Today* 35 (543) (2005), <http://dx.doi.org/10.1007/s00595-005-2987-6>.
- [8] E. Otah, B.J. Cushman, G.N. Rozenblit, R. Neff, K.E. Otah, A.M. Cooperman, Visceral artery pseudoaneurysms following pancreaticoduodenectomy, *Arch. Surg.* 137 (2002) 55–59.
- [9] F. Pedersoli, P. Isfort, S. Keil, et al., Stentgraft implantation for the treatment of postoperative hepatic artery pseudoaneurysm, *Cardiovasc. Intervent. Radiol.* 39 (2016) 575, <http://dx.doi.org/10.1007/s00270-015-1274-1>.
- [10] U. Sachdev-Ost, Visceral artery aneurysms: review of current management options, *Mt. Sinai J. Med.* 77 (2010) 296–303, <http://dx.doi.org/10.1002/msj.20181>.

Open Access

This article is published Open Access at sciendo.com. It is distributed under the [IJSCR Supplemental terms and conditions](#), which permits unrestricted non commercial use, distribution, and reproduction in any medium, provided the original authors and source are credited.