



Contents lists available at ScienceDirect

Gynecology and Minimally Invasive Therapy

journal homepage: www.e-gmit.com

Case report

Microcystic stromal tumor resected by laparoscopic surgery

Midori Murakami ^{a, b, d}, Junko Wroblewski ^{b, c, *, d}, Hidehiro Kawagoe ^b^a Department of Obstetrics and Gynecology, University of Occupational and Environmental Health School of Medicine, Kitakyushu, Japan^b Department of Obstetrics and Gynecology, National Hospital Organization Kokura Medical Center, Kitakyushu, Japan^c Department of Obstetrics and Gynecology, Japanese Red Cross Yamaguchi Hospital, Yamaguchi, Japan

ARTICLE INFO

Article history:

Received 15 June 2016

Received in revised form

17 September 2016

Accepted 9 November 2016

Available online 13 December 2016

Keywords:

laparoscopic surgery
microcystic stromal tumor
sex cord-stromal tumor

ABSTRACT

We report a case of microcystic stromal tumor (MCST) resected by laparoscopy. MCST is a very rare ovarian tumor with distinctive microcystic features and a characteristic stromal tumor immunophenotype. The present case was a 26-year-old woman who underwent laparoscopic surgery for suspected endometrial cyst of the left ovary. The mass was 8 cm in size and contained bloody fluid, and after attempting cystectomy, we eventually performed left salpingo-oophorectomy with a final postoperative pathological diagnosis of MCST. Although MCST has not yet been associated with malignancy, there are reported links to mutations in the β -catenin gene, and long-term prognosis is still unknown. As MCST resection by laparoscopy has not yet been fully described in the literature, the current case provides an example of when an unexpected, potentially malignant mass is encountered during routine cystectomy and details its subsequent management laparoscopically.

Copyright © 2016, The Asia-Pacific Association for Gynecologic Endoscopy and Minimally Invasive Therapy. Published by Elsevier Taiwan LLC. This is an open access article under the CC BY-NC-ND license (<http://creativecommons.org/licenses/by-nc-nd/4.0/>).

Introduction

Microcystic stromal tumor (MCST) is a very rare ovarian tumor with distinctive microcystic features and a characteristic stromal tumor phenotype, first reported by Irving and Young in 2009.¹ A variant within the sex cord-stromal tumor category, MCST typically affects patients who are 20–60 years old. Tumors are typically unilateral, average approximately 9 cm in size, and have both cystic and solid components.^{2,3} Because of its solid component, MCST is often resected by laparotomy, with laparoscopic resection not yet adequately described in the literature.

Here, we report a laparoscopic surgery for a suspected endometrial cyst of the left ovary whose postoperative pathological diagnosis was instead MCST. To the best of our knowledge, this is the first report of MCST resected through laparoscopy, and the current case provides an example of when an unexpected,

potentially malignant mass is encountered during routine cystectomy and details its subsequent management laparoscopically.

Case Report

Informed consent for use of patient record and specimens was obtained in written form.

A 26-year-old nulliparous woman presented to our hospital for further evaluation of an abnormal cervical pap smear and dysmenorrhea. There were no complaints of abdominal pain, and personal and family medical history were unremarkable. Upon physical examination, a 6-cm mass was discovered in the left lower abdomen. Transvaginal ultrasound sonography revealed a smooth, thick surface consisting mainly of a cystic component. During internal examination, the tumor was soft, elastic and immovable, with possible adhesions. Magnetic resonance imaging (MRI) revealed a cystic left ovarian tumor with high-signal-intensity appearance on T2-weighted imaging with fluid–fluid level and iso-signal intensity on T1-weighted imaging. There was neither solid component nor contrast enhancement, and MRI revealed a bloody fluid component without any sign of malignancy (Figure 1). The serum tumor markers levels for CA19-9, CA125, and carcinoembryonic antigen (CEA) were within normal limits. Based on chief complaint and imaging results, the diagnosis was endometrial cyst. During outpatient follow-up, however, the tumor seemed to

Conflicts of interest: The authors have no conflicts of interest relevant to this article.

* Corresponding author. Department of Obstetrics and Gynecology, Japanese Red Cross Yamaguchi Hospital, 53-1 Yawatanobaba, Yamaguchi-shi, Yamaguchi-ken 753-0092, Japan.

E-mail address: junkom001@hotmail.com (J. Wroblewski).

^d Both authors contributed equally to this work.

<http://dx.doi.org/10.1016/j.gmit.2016.11.005>

2213-3070/Copyright © 2016, The Asia-Pacific Association for Gynecologic Endoscopy and Minimally Invasive Therapy. Published by Elsevier Taiwan LLC. This is an open access article under the CC BY-NC-ND license (<http://creativecommons.org/licenses/by-nc-nd/4.0/>).

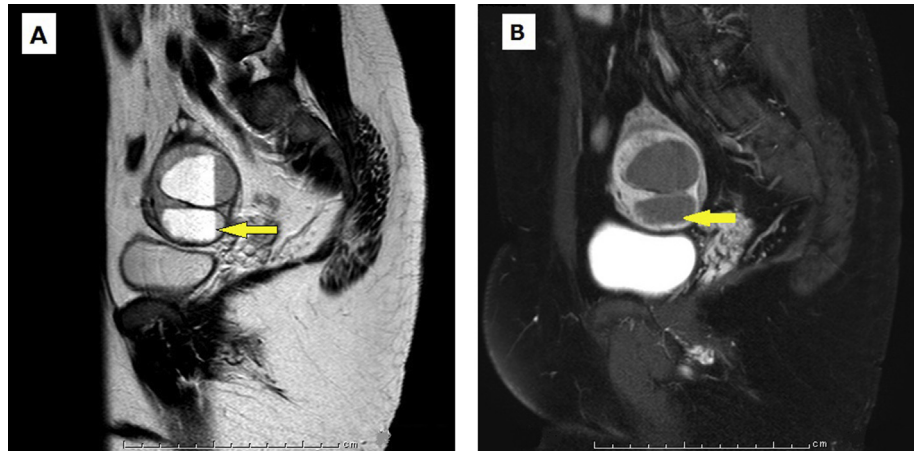


Figure 1. Magnetic resonance imaging. (A) T2-weighted imaging showing a double cystic left ovarian tumor with high-signal-intensity appearance and fluid–fluid level (arrow). (B) T1-weighted imaging showing iso-signal intensity (arrow) in which a bloody fluid component was indicated. There was neither solid component nor contrast enhancement.

have increased in size, and we consequently administered four gonadotrophin-releasing hormone analog (GnRHa) injections at monthly intervals and scheduled a laparoscopic cystectomy.

Four months later, during laparoscopy we discovered an 8-cm cystic mass present on the left ovary without adhesion formation. The uterus and right ovary were unremarkable, with a small amount of serous ascites. For cystectomy, on a part of the mass that was furthest from the oviduct, we chose an area where the tumor wall appeared thick and made a superficial incision in the outermost layer of tissue. From there, we tried to identify the boundary between the normal ovarian surface and tumor layers, but the border was ambiguous and ill-defined, making dissection difficult. In addition, because the tumor surface was also rigid yet fragile, it fragmented easily during the separation process (Figure 2A), rupturing and releasing a bloody fluid. The final resected specimen was thick but brittle, with an irregular surface that suggested the possibility of malignancy. However, definitive determination was

difficult midsurgery. Bloody fluid continued to ooze from the abraded area, and neither ligation nor cauterization was effective in stopping blood loss, eventually reaching a total of 500 ml. The procedure was paused momentarily to discuss treatment options with her family that would balance curative treatment and fertility preservation, and after receiving their consent, we finally chose left salpingo-oophorectomy in case any residual tumor remained in the normal ovarian surface layer.

Histopathologically, the tumor was composed of a proliferation of cells with uniform round nuclei and clear or eosinophilic cytoplasm arranged in microcystic, macrocystic, reticulated and solid patterns, and accompanied by myxoid stroma and hemorrhage (Figures 2B–2D). Immunohistochemically, the tumor cells were positive for vimentin (Figure 2F) and CD10, and nuclei were positive for β -catenin (Figure 2E) and FOXL2. Cells were negative for α -inhibin (Figure 2G), as well as for AE1/AE3, CAM5.2, and epithelial membrane antigen (EMA). The MIB-1 labeling index was 8%, and

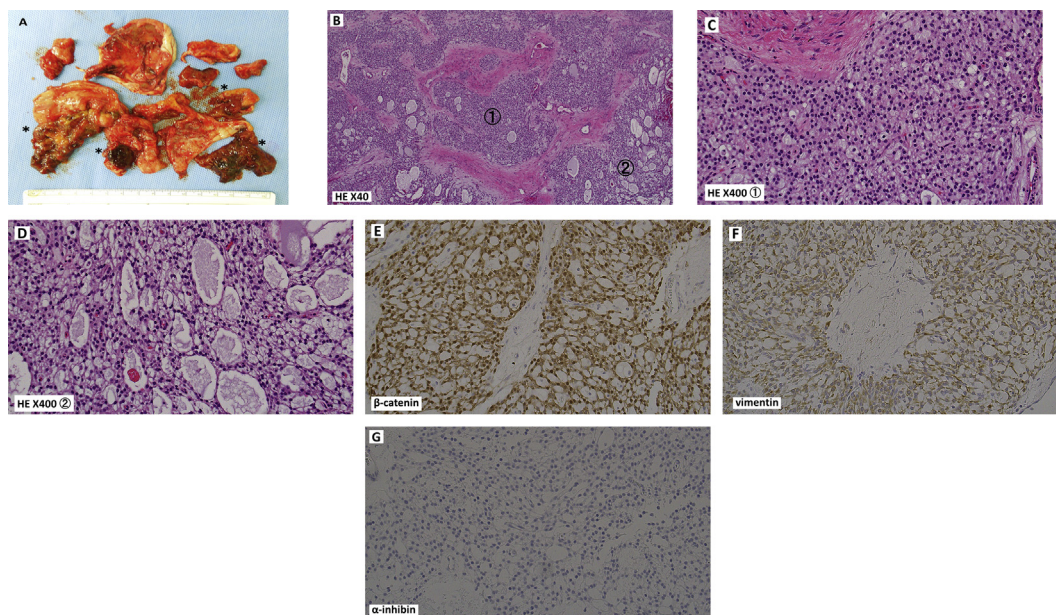


Figure 2. (A) Gross view of the excised specimen. The areas marked by asterisks indicate those areas that were difficult to dissect from the normal ovarian surface. Note that the tumor was fragmented by the dissection process. (B) The different components of the tumor, indicated by ① and ②. (C) Enlargement of ① from B: cells with uniform round nuclei and clear or eosinophilic cytoplasm and a solid pattern with collagenous stroma. (D) Enlargement of ② from B: larger, irregular microcystic, macrocystic, and reticulated component. (E) Immunohistochemistry for β -catenin. Note the positive immunoreactive nuclei. (F) Cells staining positive for vimentin. (G) Lack of immunoreactivity for α -inhibin.

mutation of the *CTNNB1* gene (Exon 3) was not detected by sequencing. Taken together, these characteristics were indicative of MCST. At the time of writing, almost 3 years have passed without recurrence.

Discussion

Irving and Young¹ first reported 16 cases of a hitherto uncharacterized distinctive ovarian neoplasm in 2009, and in 2014, MCST was classified as a sex cord-stromal tumor by the World Health Organization.² Originally considered strictly benign, MCST has recently drawn further attention through reports of genetic mutations that could lead to tumorigenesis and links to other diseases.^{4–7} Its clinicopathologic characteristics include typically unilateral tumors that are often <10 cm in size (range, 2–27 cm), appear at a mean age of 45 years (range, 26–63 years), display a mixture of cystic and solid components, and lack hormonal manifestations or malignant behavior.¹ The solid component is usually firm and tan–white with a focally hemorrhagic cut surface, and MCST is recognized to consist of three components: microcysts, solid cellular zones, and collagenous stroma. The microcystic pattern is characterized by small, rounded-to-oval cystic spaces coalescing into larger, irregular channels, whereas the solid cellular areas are usually intersected by fibrous bands and hyaline plaques. Immunohistochemically, tumor cells are usually positive for CD10, vimentin, WT-1, cyclin-1, and FOXL2 and negative for the sex cord markers inhibin and calretinin as well as for hormone receptors and neuroendocrine markers. They may be focally positive for keratin but are negative for EMA.^{1–3}

As mentioned previously, MCST has drawn increased interest because of its unknown potential for malignancy. Maeda et al⁴ recognized a morphologic resemblance between MCST and pancreatic solid pseudopapillary neoplasm, with the former displaying β -catenin nuclear accumulation and a mutation in Exon 3 of *CTNNB1* that was identical to the latter. Furthermore, Irving et al⁵ demonstrated the *CTNNB1* mutation in 57% of MCST cases.

It is fairly well established that the Wnt/ β -catenin pathway is involved in tumorigenesis. β -Catenin levels are regulated by a multiprotein complex that includes adenomatous polyposis coli (APC), and reports have linked β -catenin degradation to familial adenomatous polyposis (FAP).⁶ Interestingly, Lee et al⁷ reported a case in which both MCST and FAP were found in the same patient. They detected a novel somatic mutation of the *APC* gene in MCST ovarian tissue, but mutations in either β -catenin (*CTNNB1*) or FOXL2 were absent, representing a case in which MCST was caused by a somatic mutation of *APC*. Nevertheless, MCST tumor cells demonstrate low mitotic activity, and MCST is currently classified as a benign tumor.² And although short-term prognosis is indeed good, long-term prognosis remains unknown, necessitating ongoing caution.

Laparoscopy for benign ovarian tumors has become increasingly common, as have reports of sex cord-stromal tumors dissected by laparoscopic surgery.^{8,9} However, when performed for reproductive-age individuals, fertility preservation is a significant consideration as well, and consequently, cystectomy is regularly chosen. However, in one comparative study involving granulosa cell tumor – a sex cord-stromal tumor – the cystectomy group had a higher recurrence rate than the group in which salpingo-oophorectomy was performed.¹⁰ Therefore, when dissecting tumors via cystectomy for fertility preservation, and histology indicates a sex cord-stromal tumor, secondary surgery to remove any leftover ovarian tissue from the tumor lesion side should be considered.

The current case is the first detailed report of MCST resection by laparoscopy. MRI displayed a bilocular cyst containing bloody fluid, and suspecting an endometrial cyst of the left ovary, we attempted cystectomy. However, the cyst was hard yet brittle with ill-defined

borders and thus extremely difficult to dissect from the normal ovarian surface layer. Although we removed the main part of the tumor, gross inspection alone could not rule out malignancy. Together with the possibility that the remaining ovarian surface layer hid a residual tumor and the occurrence of significant blood loss, we chose salpingo-oophorectomy with a preferential view toward curative treatment. In the end, the second resected area of ovarian tissue was unremarkable.

When considering changing operative method midsurgery, frozen section diagnosis could obviously be advantageous. Because there was no suspicion of malignancy when surgery was first scheduled, however, we made no provisions for frozen section analysis ahead of time. And because our hospital is not equipped to handle same-day processing, we were unable to incorporate their data into our midsurgery decision-making process. Regardless, despite the possible utility in identifying other types of tumors, frozen section analysis of MCST may indeed be too difficult owing to its unique immunohistochemical signature.

Similarly, concerning counselling of the patient (and her family) on the discovery of possible malignancy midsurgery, a crucial part of the preoperative informed consent process at our hospital is a strong emphasis that, in the event of suspicion of malignancy, inability to complete the originally intended surgery, etc., the predetermined operative method might need to be changed. Emphasizing this fact ahead of time can facilitate easier communication with family members during time-sensitive processes such as those encountered midsurgery.

MCST is characterized pathologically by the presence of typically lobulated cellular regions separated by hyaline bands and fibrous plaques, possibly explaining the difficult cystectomy and increased blood loss in the current patient. Consequently, even in cases of cystic ovarian tumors such as endometrial cysts, when the resection process proves difficult we should consider the possibility of a sex cord-stromal tumor. Accordingly, to avoid dissemination of the contents of the cyst, we suggest placing the tumor mass in a collecting bag first and performing the cystectomy inside when possible. In the event of leakage, cyst contents and fluid should be suctioned off completely and the abdominal cavity rinsed thoroughly with saline.

Although MCST has not yet been associated with malignancy, there are the aforementioned possible links to mutations in the β -catenin gene, and long-term prognosis is still unknown. Correspondingly, we have continued to follow up with the patient concerning recurrence and suggest that in the future, inquiries into any family history of FAP also be made in such cases.

Definitive preoperative tissue diagnosis for ovarian tumors is usually considered impossible; indeed, one purpose of surgery is confirmation of a pathological diagnosis. In recent years, when there is no cause for suspicion, laparoscopy has been increasingly chosen over laparotomy for cosmetic purposes and to mitigate the risk of adhesion formation. And as many gynecologists who do not specialize in oncology routinely perform laparoscopic surgery for benign ovarian tumors, it is even more crucial to highlight that unexpected instances of potentially malignant and/or rare tumors (such as MCST here) can and indeed do occur and that there is a need to consider their management in a laparoscopic context. Similarly, the accumulation of data as in the present case will be crucial in determining the most appropriate management of MCST cases going forward.

Acknowledgments

We thank Gregory Wroblewski of the Yamaguchi University Graduate School of Medicine's Division of Neuroanatomy (Ube,

Japan) for his critical reading of the manuscript and for ensuring the accuracy of its English grammar and usage.

References

1. Irving JA, Young RH. Microcystic stromal tumor of the ovary: report of 16 cases of a hitherto uncharacterized distinctive ovarian neoplasm. *Am J Surg Pathol*. 2009;33:367–375.
2. Kurman RJ, Carcangiu ML, Herrington CS. *WHO Classification of Tumours of Female Reproductive Organs*. Lyon: International Agency for Research on Cancer; 2014:47.
3. Oliva E, Yong RH. Stromal tumours of the ovary: an update. Mini-symposium: pathology of the ovary. *Diagn Histopathol*. 2014;20(9):376–384.
4. Maeda D, Shibahara J, Sakuma T, et al. β -Catenin (CTNNB1) S33C mutation in ovarian microcystic stromal tumors. *Am J Surg Pathol*. 2011;35:1429–1440.
5. Irving JA, Lee CH, Yip S, Oliva E, Mcggage WG, Young RH. Microcystic stromal tumor. A distinctive ovarian sex cord-stromal neoplasm characterized by FOXL2, SF-1, WT-1, Cyclin D1, and β -catenin nuclear expression and CTNNB1 mutation. *Am J Surg Pathol*. 2015;39(10):1420–1426.
6. Polakis P. Wnt signaling and cancer. *Genes Dev*. 2000;14:1837–1851.
7. Lee SH, Koh YW, Roh HJ, Cha HJ, Kwon YS. Ovarian microcystic stromal tumor: a novel extracolonic tumor in familial adenomatous polyposis. *Genes Chromosomes Cancer*. 2015;54(6):353–360.
8. Gremeau AS, Bourdel N, Jardon K, et al. Surgical management of non-epithelial ovarian malignancies: advantages and limitations of laparoscopy. *Eur J Obstet Gynecol Reprod Biol*. 2014;172:106–110.
9. Wee J, Li X, Chern B, Chua I. Struma ovarii: management and follow-up of a rare ovarian tumour. *Singapore Med J*. 2015;56:35–39.
10. Miyazaki N, Takeda Y, Kokabu T, et al. A case of late recurrence of a granulosa cell tumor of the ovary after laparoscopic surgery. *Adv Obstet Gynecol*. 2015;67:86–94.