




Case Report

Acute presentation of spinal gouty arthritis: A case report and review of literature

Asad S. Akhter, Ahmed Mohyeldin, Andrew J. Grossbach

Department of Neurosurgery, The Ohio State University Wexner Medical Center, Columbus, Ohio.

E-mail: Asad S. Akhter - asad.akhter@osumc.edu; Ahmed Mohyeldin - ahmed.mohyeldin@osumc.edu; *Andrew J. Grossbach - andrew.grossbach@osumc.edu



***Corresponding author:**

Andrew J. Grossbach,
Department of Neurosurgery,
The Ohio State University
Wexner Medical Center,
410 W 10th Avenue, Doan Hall,
Columbus 43210, Ohio.

andrew.grossbach@osumc.edu

Received : 31 October 19
Accepted : 01 November 19
Published : 29 November 19

DOI
10.25259/SNI_528_2019

Quick Response Code:



ABSTRACT

Background: Gout is an inflammatory arthritis that results from faulty purine metabolism, affecting approximately 4% of adults in the US, and predominately affects people in the fourth decade of life. Further, spinal gout is rarely the first presentation of gout, especially in younger individuals.

Case Description: A 26-year-old male came to the emergency room with acute lower extremity numbness and weakness. The MR demonstrated an enhancing epidural lesion at T6–T8 in the mid-thoracic spine. He subsequently underwent a decompressive laminectomy and fusion at levels T6–T9, resulting in full recovery 1 year later. The pathology demonstrated needle-like monosodium urate crystals consistent with the diagnosis of spinal gouty arthritis.

Conclusion: Gout rarely initially presents in a young adult in the spine. Here, we reviewed the case of spinal gout in a 26-year-old male who successfully underwent spinal surgery.

Keywords: Gout, Paralysis, Spinal cord injury, Spine

INTRODUCTION

Gout, that afflicts approximately 4% of adults in the United States, is an inflammatory arthritis that results from faulty purine metabolism.^[6] It becomes acutely symptomatic when the final product of purine metabolism, uric acid, reaches high saturation levels in the blood. This is attributed either to decreased clearance or overproduction. The uric acid then crystallizes into monosodium urate which is then deposited into tissues; it particularly involves the synovial joints of the feet, hands, and, rarely, the spine. These crystals produce an inflammatory response that results in swollen, tender, and hot joints; the deposits are known as tophi. Here, we report a case of tophaceous gout leading to neurological deficits in a 26-year-old male along with a review of the relevant literature.

CASE REPORT

Clinical findings

A 26-year-old male presented with 1–2 months of progressive right lower extremity weakness culminating in a 1-day history of the inability to ambulate. On examination, he exhibited 4-/5

hip flexion, knee extension, and knee flexion bilaterally in the lower extremities, 2/5 right-sided plantar flexor weakness, left lower extremity anteromedial hip numbness, and patellar hyperreflexia.

Radiographic presentation

The thoracic MR with and without contrast demonstrated a right posterior-lateral T2 enhancing epidural lesion extending from T6 to T8 contributing to severe canal/cord stenosis and mild cord T6–T9 cord edema [Figure 1a-f]. The noncontrast thoracic computed tomography scan demonstrated multilevel periarticular lytic/erosive lesions involving the T6–T7 to T8–T9 facet joints, accompanied by lobulated high-density juxta-articular material extending into the adjacent canal [Figure 2a-e].

Surgery

The next day, he underwent a T6–T9 decompressive laminectomy for the resection of the epidural mass

accompanied by pedicle screw instrumentation [Figure 3a and b]. At each level, there was a “white, cheese-like” material causing substantial dural compression; the material was grossly consistent with tophaceous deposits within the facet joints and the pathological confirmation of needle-like monosodium urate crystals.

Postoperative course

On postoperative day 1, the patient was 4+/5 in the lower extremities bilaterally, and the numbness of the anteromedial segment of his left lower extremity was markedly improved. He was discharged 6 days later, and at 1 postoperative year, his neurological examination was normal.

Pathology

The final pathology demonstrated whitish aggregates of strand-like material surrounded by inflammatory cells, including many foreign body giant cells. Under polarized

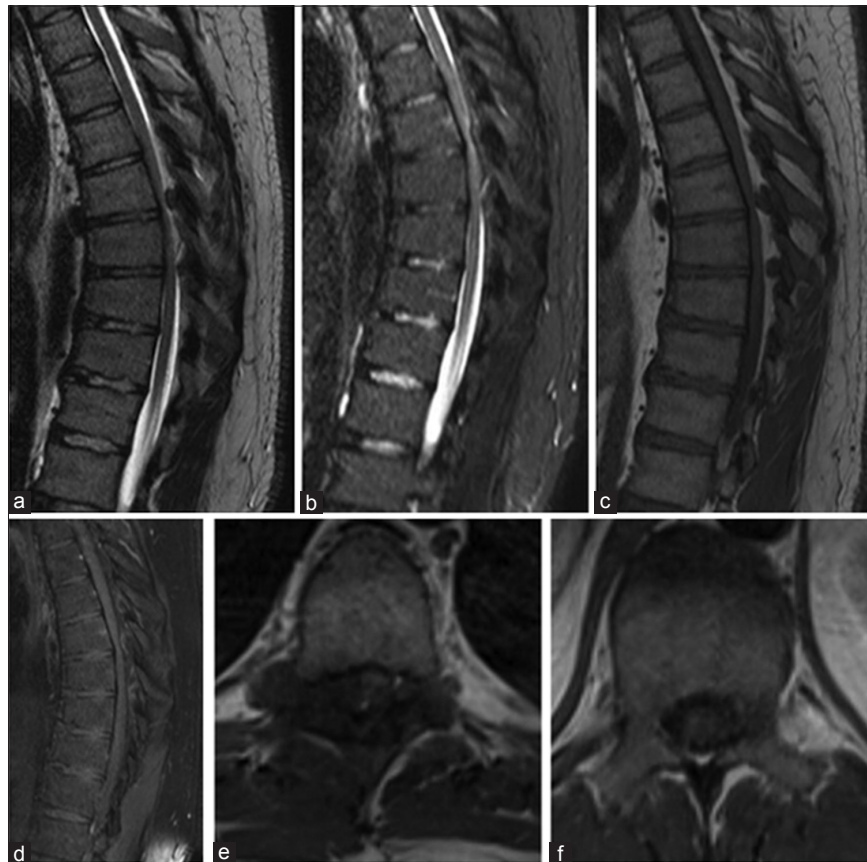


Figure 1: Magnetic resonance imaging (MRI) images with the right lateral epidural abnormality in the mid-thoracic spine with spinal cord compression. (a) Sagittal T2 sequences, (b) sagittal short-tau inversion recovery sequences, (c) sagittal T1 sequences without contrast, (d) sagittal T1 sequences with contrast, (e) axial T1 MRI with contrast demonstrating extension of a tophus into the spinal canal and compressing the spinal cord to the left, (f) axial T1 magnetic resonance imaging with contrast at a level with no inflammatory or degenerative changes and no spinal cord compression.

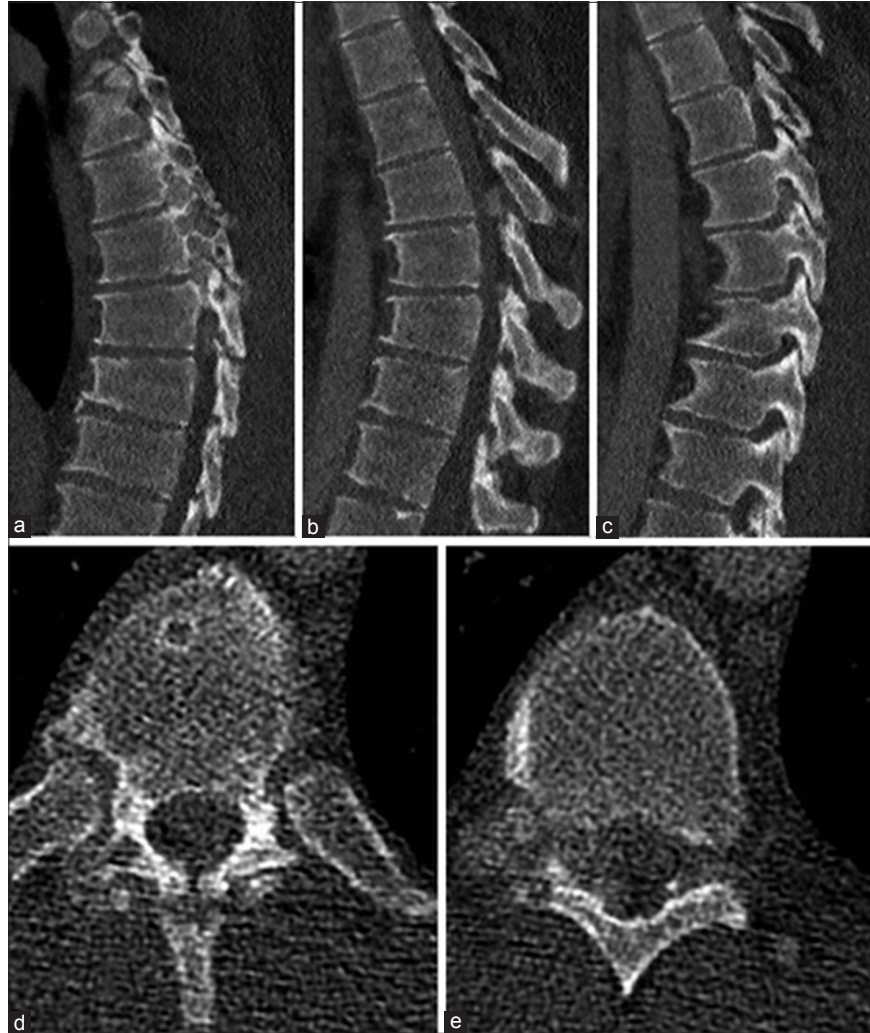

Figure 2: Computed tomography (CT) images showing lytic process of bilateral thoracic facet joints with compression of the spinal cord. (a) Sagittal CT scans of the mid-thoracic spine demonstrating erosive changes of the right facet joints, (b) sagittal STIR sequences, (c) sagittal T1 sequences without contrast, (d) sagittal T1 sequences with contrast, (e) axial T1 magnetic resonance imaging with contrast demonstrating extension of a tophus into the spinal canal and compressing the spinal cord to the left.

light, these aggregates revealed strongly negative birefringent needle-shaped crystals consistent with gout.

Further, the postoperative rheumatologic workup documented elevated serum and urine uric acid levels. In addition, an X-ray of the right hand showed a synovial inflammatory process involving the ring finger. The patient was started on colchicine 0.6 mg b.i.d. and allopurinol 200 mg q.d.

DISCUSSION

Here, we described a rare case of spinal tophaceous gout in a 26-year-old male who newly presented with an acute paraparesis. The diagnosis of gout was not originally entertained, given the patient's negative history and young age.

In a review of 131 cases, Toprover *et al.* found that gout can affect the lumbar (38%), cervical (24.8%), and thoracic spine (17.8%).^[3] The most frequent clinical manifestation is typically back pain; however, more severe neurologic symptoms have been described, including the onset of acute weakness.^[1]

The current epidemiologic studies show that the prevalence of gout in patients between the ages of 18 and 44 is <0.3%.^[4] As of 2019, only 159 cases of spinal gout have been reported; gout is typically diagnosed in the fourth decade of life, the average age in men 30 years old.^[2] Around 50% of patients present with neurological sequela requiring surgery if there is a neurological compromise. Here, our patient required surgical decompression/fusion to both establish the diagnosis and treat the acute paraparesis. Only 13 reported cases

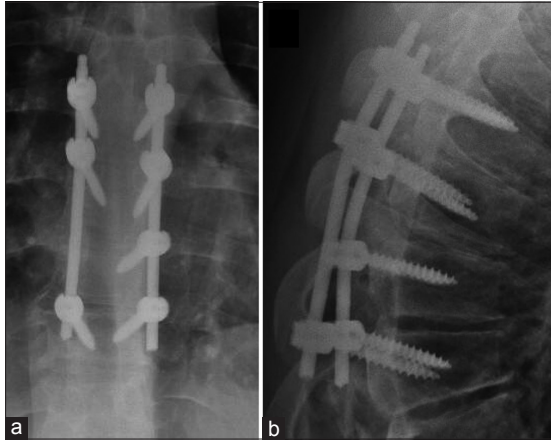


Figure 3: (a) Postoperative anteroposterior and lateral thoracic X-rays demonstrating a short T6-T9 fusion construct. (b) Postoperative lateral X-rays of the thoracic spine demonstrating short fusion of the thoracic spine.

demonstrate patients who were diagnosed with spinal gout, with only one of those patients having no prior history.^[5]

CONCLUSION

Here, we presented the rare scenario of a 26-year-old male acutely developing paraparesis secondary to T6-T9 tophaceous gout.

Declaration of patient consent

The authors certify that they have obtained all appropriate patient consent forms.

Financial support and sponsorship

Nil.

Conflicts of interest

There are no conflicts of interest.

REFERENCES

1. Draganescu M, Leventhal LJ. Spinal gout: Case report and review of the literature. *J Clin Rheumatol* 2004;10:74-9.
2. Dwarki K, Dothard A, Abadie B, Miles MC. Rogue one: A story of tophaceous gout in the spine. *BMJ Case Rep* 2018;2018:bcr-2017-221163.
3. Toprover M, Krasnokutsky S, Pillinger MH. Gout in the spine: Imaging, diagnosis, and outcomes. *Curr Rheumatol Rep* 2015;17:70.
4. Wallace KL, Riedel AA, Joseph-Ridge N, Wortmann R. Increasing prevalence of gout and hyperuricemia over 10 years among older adults in a managed care population. *J Rheumatol* 2004;31:1582-7.
5. Wang W, Li Q, Cai L, Liu W. Lumbar spinal stenosis attributable to tophaceous gout: Case report and review of the literature. *Ther Clin Risk Manag* 2017;13:1287-93.
6. Zhu Y, Pandya BJ, Choi HK. Prevalence of gout and hyperuricemia in the US general population: The national health and nutrition examination survey 2007-2008. *Arthritis Rheum* 2011;63:3136-41.

How to cite this article: Akhter AS, Mohyeldin A, Grossbach AJ. Acute presentation of spinal gouty arthritis: A case report and review of literature. *Surg Neurol Int* 2019;10:232.