

# A Case of Frontotemporal Dementia Presenting as Nicotine Dependence and Carbohydrate Craving

Sir,

Frontotemporal dementia (FTD) is a progressive dementing condition characterized by selective degeneration of the frontal and anterior temporal lobes that causes a profound alteration in character and social conduct, in the context of relative preservation of perception, spatial skills, praxis, and memory.<sup>[1]</sup> FTD is not a rare disorder and is often misdiagnosed. FTD patients make up about 10% of all patients with dementing diseases.<sup>[2,3]</sup> Because FTD is usually a presenile onset disorder, among dementia patients with age at onset of less than 65 years, FTD accounts for approximately 20% of neurodegenerative dementias.<sup>[4]</sup> Core behavioral features of the Consensus Criteria are impaired social interactions, impaired personal regulation, emotional blunting, and loss of insight.<sup>[1]</sup> A characteristic feature of FTD is behavioral disinhibition, which can be manifested by substance use. As per our literature review, a few cases of behavioral variant FTD reported with substance abuse, but none of them reported a female patient presenting with nicotine dependence and showing significant improvement in these behaviors with antipsychotic medications.

### CASE REPORT

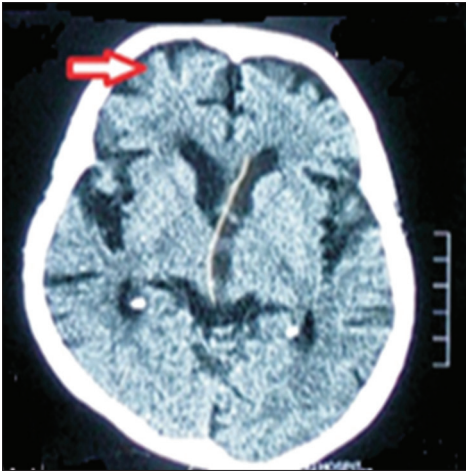
A 72-year-old female was brought by her son with 2 years history of excessive use of tobacco in the form of *gutkha* (chewable tobacco), around 12–15 packets/day. This was a new onset symptom, which the family members did not notice until it increased to five to six packets per day and the patient started repeatedly demanding money to purchase tobacco. Once the family found out about this repeated use of tobacco, they started restricting her access to money. Within a year, family members noticed that the patient started to steal money and even sell small household items, including her grandson's mobile phone. She used this money to purchase tobacco packets. When family members questioned her activities, she would get irritable and abusive toward them, which was described as against her usual personality. Another new onset behavior that the family noted was that she was eating sugar in increased quantities. She would mix half a glass of sugar in water and drink it and add sugar to everything she eats. She would drink around 3–4 l of milk per day and eat 8–10

raw eggs. The family also noticed disinhibited behaviors like changing clothes in inappropriate places and being abusive toward everyone. Gradually, the patient started being forgetful about minor issues, repeatedly asking for food even after a meal, and blaming family members of taking away her things, which she had misplaced.

Physical examination revealed no significant findings, with stable vitals and systemic examination being within normal limits. On mental status examination, the patient was not cooperative and showed disinhibited behavior, occasional irrelevant speech, irritable affect, paranoid delusions, and immediate and recent memory deficits. After the initial history and mental status examination, the differential diagnoses of FTD, Alzheimer's dementia, and late onset psychosis were considered.

Routine blood investigations revealed increased thyroid-stimulating hormone (10.8 mU/l) and triglyceride (250 mg/dl) levels. Magnetic resonance imaging (MRI) of brain [Figure 1] showed significant atrophic changes in bilateral frontal and medial basal temporal lobes (right > left side) and perisylvian cortex. Mini Mental Status Examination score was 13 out of 31, which is suggestive of moderate cognitive impairment. Her attention was arousable, but concentration was not well sustained. Bender Gestalt Test (BGT) revealed difficulties in visual-motor integration, in discriminating visual stimuli, and in shifting attention from the original design to what is being drawn, features suggestive of significant visuoconstructive deficits. Her impaired concentration could have played some role in these BGT results. The test also showed memory disturbances and difficulties in concentration and comprehension. A final diagnosis of frontotemporal dementia behavioral variant (bvFTD) was made as per the International Consensus Criteria,<sup>[5]</sup> and the other two differentials were ruled out based on the history, examination, and investigation findings. The MRI findings played a key role in confirming the diagnosis.

The patient was started on quetiapine tablet 50 mg/day and the dose was gradually increased to 200 mg/day over a period of 2 weeks. A tablet preparation containing



**Figure 1:** MRI brain section showing atrophic changes in bilateral frontotemporal regions (more on the right compared to left, indicated by an arrow)

both donepezil 5 mg and memantine 5 mg was started and then changed to a tablet preparation containing both donepezil 5 mg and memantine 10 mg. The patient was also started on rosuvastatin tablet 10 mg and thyroxine tablet 50 mcg after liaising with a physician. Psychoeducation for family members regarding the nature, course, and prognosis of the illness and the need for treatment was done. Over a period of 4–6 weeks, the patient showed significant improvement in her behavioral symptoms, mainly the craving for nicotine and carbohydrates and the irritability. No disinhibited behaviors were noted. The patient is on regular follow-up with the clinical team, with no significant behavioral problems but gradually progressing cognitive deficits.

## DISCUSSION

The above case description and investigation findings helped us make the diagnosis of bvFTD. A literature review showed a few case reports of FTD presenting as pure psychiatric syndromes. One of the cases presented with persistent paranoid delusions.<sup>[6]</sup> Another case presented with clear schizophrenic symptoms and was treated with antipsychotics for a few years.<sup>[7]</sup> Another case presented with pathological gambling.<sup>[8]</sup> In another case report, where a case of frontotemporal lobar dementia whose presentation was consistent with bipolar affective disorder with psychosis in addition to ongoing substance abuse and the illness was refractory to treatment for bipolar disorder, the authors emphasized the need for the clinicians to consider differential diagnoses in manic and psychotic symptoms resistant to polypharmacy.<sup>[9]</sup>

Nucleus accumbens, part of the ventral striatum and the mesolimbic pathway, which are the reward

pathway of the brain,<sup>[10]</sup> are responsible for addictive and reward-seeking behaviors. Atrophic changes in these areas can be implicated in these behaviors in patients with FTD. A study, which looked at the anatomical correlates of reward-seeking behaviors in bvFTD, revealed a significant correlation between primary reward seeking and atrophy of the right ventral putamen extending into the right pallidum. The authors concluded that these behaviors are caused, at least in part, by abnormal reward processing.<sup>[11]</sup>

Several medical and environmental risk factors such as traumatic brain injury, hypertension, hyperlipidaemia, and tobacco use might be associated with FTDs.<sup>[12]</sup> Hence, a thorough evaluation of the patient, as was conducted in our case, is mandatory. Our review of the literature did not reveal any reports of FTD with female patients presenting with nicotine dependence as one of the important presenting symptoms, especially in the Indian context.

When it comes to the treatment of the substance use behaviors, a case report highlights how topiramate led to improvement in the drug-seeking behaviors.<sup>[13]</sup> In our patient, the use of quetiapine along with donepezil and memantine led to significant improvement in the drug dependence and other behavioral problems within 4–6 weeks. The effective use of quetiapine along with the anti-dementia medications for the treatment of drug dependence in bvFTD has not been reported earlier. In the geriatric population, any late-onset behavioral symptoms should always raise a suspicion of neurodegenerative disorders, especially with an increase of substance abuse or dependence among the elderly population; one of the etiological factors for substance abuse in the elderly could be FTD. The main purpose of reporting this case is to highlight the varied presentation of a neurodegenerative disorder in an elderly woman and how early diagnosis and appropriate treatment can lead to good improvement in these behavioral symptoms and improve the quality of life in these patients.

### Declaration of patient consent

The authors certify that they have obtained all appropriate patient consent forms. In the form the patient(s) has/have given his/her/their consent for his/her/their images and other clinical information to be reported in the journal. The patients understand that their names and initials will not be published and due efforts will be made to conceal their identity, but anonymity cannot be guaranteed.

### Financial support and sponsorship

Nil.

**Conflicts of interest**

There are no conflicts of interest.

**Preethi V. Reddy, Lavanya Anuroop<sup>1</sup>,  
Veda Shetageri<sup>1</sup>, Raghavendra K. Kumar<sup>2</sup>,  
Ganeshan Gopalakrishnan<sup>1</sup>**


Departments of Psychiatry and <sup>2</sup>Child Psychiatry, National Institute of Mental Health and Neurosciences, <sup>1</sup>Department of Psychiatry, M V Jayaram Medical College and Research Centre, Bangalore, Karnataka, India

**Address for correspondence:** Dr. Veda Shetageri  
Department of Psychiatry, M V Jayaram Medical College and Research Centre, Hoskote, Bangalore, Karnataka, India.  
E-mail: drveda\_24@rediffmail.com

**REFERENCES**

1. Neary D, Snowden JS, Gustafson L. Frontotemporal lobar degeneration: A consensus on clinical diagnostic criteria. *Neurology* 1998;51:1546-54.
2. Mendez MF, Selwood A, Mastri AR. Pick's disease versus Alzheimer's disease: A comparison of clinical characteristics. *Neurology* 1993;43:289-92.
3. Pasquier F, Lebert F, Lavenu I. Diagnostic clinique des de'mences fronto-temporales. *Rev Neurol* 1998;154:217-23.
4. Robert PH, Lafont V, Snowden JS. Crite`res diagnostiques des de'ge'nerescences lobaires fronto-temporales. *Encephale* 1999;25:612-21.
5. Rascovsky K. Sensitivity of revised diagnostic criteria for the behavioural variant of frontotemporal dementia. *Brain* 2011;134:2456-77.
6. Iroka N, Jehangir W, Littlefield J II. Paranoid personality masking an atypical case of frontotemporal dementia. *J Clin Med Res* 2015;7:364-6.
7. Velakoulis D, Walterfang M, Mocellin R. Frontotemporal dementia presenting as schizophrenia-like psychosis in young people: Clinicopathological series and review of cases. *Br J Psychiatry* 2009;194:298-305.
8. Manes FF. Frontotemporal dementia presenting as pathological gambling. *Nat Rev Neurol* 2010;6:347-52.
9. Ibanez N. Atypical presentation of frontotemporal dementia masquerading as bipolar disorder and substance abuse: A case report. *W V Med J* 2012;108:16-8.
10. Pontieri FE, Tanda G, Orzi F, Di Chiara G. Effects of nicotine on the nucleus accumbens and similarity to those of addictive drugs. *Nature* 1996;382:255-7.
11. Perry DC, Sturm VE, Seeley WW, Miller BL, Kramer JH, Rosen HJ. Anatomical correlates of reward-seeking behaviours in behavioural variant frontotemporal dementia. *Brain* 2014;137:1621-6.
12. Kalkonde YV, Jawaid A, Qureshi SU, Shirani P, Wheaton M, Pinto-Patarroyo GP, et al. Medical and environmental risk factors associated with frontotemporal dementia: A case-control study in a veteran population. *Alzheimer's Dement* 2012;8:204-10.
13. Cruz M, Marinho V, Fontenelle LF, Engelhardt E, Laks J. Topiramate may modulate alcohol abuse but not other compulsive behaviors in frontotemporal dementia: Case report. *Cogn Behav Neurol* 2008;21:104-6.

This is an open access journal, and articles are distributed under the terms of the Creative Commons Attribution-NonCommercial-ShareAlike 4.0 License, which allows others to remix, tweak, and build upon the work non-commercially, as long as appropriate credit is given and the new creations are licensed under the identical terms.

Access this article online	
<b>Website:</b> www.ijpm.info	<b>Quick Response Code</b> 
<b>DOI:</b> 10.4103/IJPSYM.IJPSYM_390_18	

**How to cite this article:** Reddy PV, Anuroop L, Shetageri V, Kumar RK, Gopalakrishnan G. A case of frontotemporal dementia presenting as nicotine dependence and carbohydrate craving. *Indian J Psychol Med* 2019;41:391-3.  
© 2019 Indian Psychiatric Society - South Zonal Branch | Published by Wolters Kluwer - Medknow