

## Pierpont Syndrome: A Collaborative Study

Emma M.M. Burkitt Wright,<sup>1</sup> Mohnish Suri,<sup>2</sup> Susan M. White,<sup>3,4,5</sup> Nicole de Leeuw,<sup>6</sup> Anneke T. Vulto-van Silfhout,<sup>6</sup> Fiona Stewart,<sup>7</sup> Shane McKee,<sup>7</sup> Sahar Mansour,<sup>8</sup> Fiona C. Connell,<sup>9</sup> Maya Chopra,<sup>10</sup> Edwin P. Kirk,<sup>10</sup> Koen Devriendt,<sup>11</sup> Willie Reardon,<sup>12</sup> Han Brunner,<sup>4</sup> and Dian Donnai<sup>1\*</sup>

<sup>1</sup>Genetic Medicine, Manchester Academic Health Science Centre, University of Manchester and Central Manchester University Hospitals NHS Foundation Trust, St Mary's Hospital, Manchester, UK

<sup>2</sup>Clinical Genetics Service, Nottingham University Hospitals NHS Trust, Nottingham, UK

<sup>3</sup>Genetic Health Services Victoria, Royal Children's Hospital, Parkville, Victoria, Australia

<sup>4</sup>Department of Paediatrics, University of Melbourne, Melbourne, Victoria, Australia

<sup>5</sup>Murdoch Childrens Research Institute, Royal Children's Hospital, Melbourne, Victoria, Australia

<sup>6</sup>Human Genetics, Radboud University Nijmegen Medical Centre, Nijmegen, The Netherlands

<sup>7</sup>Medical Genetics, Belfast City Hospital, Belfast, UK

<sup>8</sup>South West Thames Regional Genetics Service, St George's Hospital, London, UK

<sup>9</sup>South East Thames Regional Genetics Service, Guy's Hospital, London, UK

<sup>10</sup>Department of Medical Genetics, Sydney Children's Hospital, Randwick, New South Wales, Australia

<sup>11</sup>Departement Menselijke Erfelijkheid, Katholieke Universiteit Leuven, Leuven, Belgium

<sup>12</sup>Our Lady's Hospital for Sick Children, Crumlin, Dublin, Ireland

Received 28 February 2011; Accepted 23 April 2011

Pierpont syndrome is a multiple congenital anomaly syndrome with learning disability first described in 1998. There are only three patients with Pierpont syndrome who have previously been published in the literature. Details of a series of patients with features of this condition were therefore obtained retrospectively to better characterize its key features. These patients were noted to have distinctive shared facial characteristics, in addition to plantar fat pads and other limb abnormalities. Further individuals with equally striking hand and foot findings were identified whose facies were less characteristic, and hence we considered them unlikely to be affected with the same condition. Despite several patients with possible Pierpont syndrome having had high-resolution array CGH or SNP array, the etiology of this phenotype remains unknown. Whilst it is as yet unclear whether it is a single entity, there appears to be a group of patients in whom Pierpont syndrome may be a recognizable condition, with typical facies, particularly when smiling, and characteristic hand and foot findings. © 2011 Wiley-Liss, Inc.

**Key words:** Pierpont syndrome; fetal digital pads; plantar fat pads; learning disability

### INTRODUCTION

Pierpont et al. [1998] reported two patients with a new syndrome of plantar fat pads, characteristic facial features and developmental delay. Only one further affected patient has been recorded in the

#### How to Cite this Article:

Burkitt Wright EMM, Suri M, White SM, de Leeuw N, Vulto-van Silfhout AT, Stewart F, McKee S, Mansour S, Connell FC, Chopra M, Kirk EP, Devriendt K, Reardon W, Brunner H, Donnai D. 2011. Pierpont syndrome: A collaborative study.

Am J Med Genet Part A 155:2203–2211.

literature since then [Oudesluijs et al., 2005]. We report here seven new possible patients with Pierpont syndrome, several of whom, including a pair of monozygotic twins, closely resemble the original three. Four further individuals in whom this diagnosis was considered because of typical hand and foot findings did not share the characteristic facial appearances, and had a wide variety of other clinical features, including structural anomalies and a variable degree of developmental problems. These patients were therefore

Grant sponsor: UK National Institute for Health Research's Manchester Biomedical Research Centre.

\*Correspondence to:

Dian Donnai, Genetic Medicine, St Mary's Hospital, Oxford Road, Manchester, M13 9WL, UK. E-mail: dian.donnai@cmft.nhs.uk

Published online 10 August 2011 in Wiley Online Library (wileyonlinelibrary.com).

DOI 10.1002/ajmg.a.34147

excluded from the phenotypic analysis, as their presentations were not sufficiently suggestive of being affected by the same condition.

Updated information was sought on previously published patients by contacting the papers' authors. Additional possibly affected individuals for consideration were identified through presentations at national and international dysmorphology meetings and personal communication networks in the clinical genetics community. Consent was sought from parents/guardians for inclusion in this retrospective case series. Clinical synopses and photographs were collected, and a table of relevant features was compiled.

Discussion regarding which features may be core to this emerging syndrome has focused especially on the specificity of fat pads on the anteromedial border of the heels and persistent fetal digital pads. We therefore instituted a study to better define the phenotype of patients with a possible diagnosis of Pierpont syndrome. Results of genetic investigations are discussed, where these had been undertaken in the patients identified.

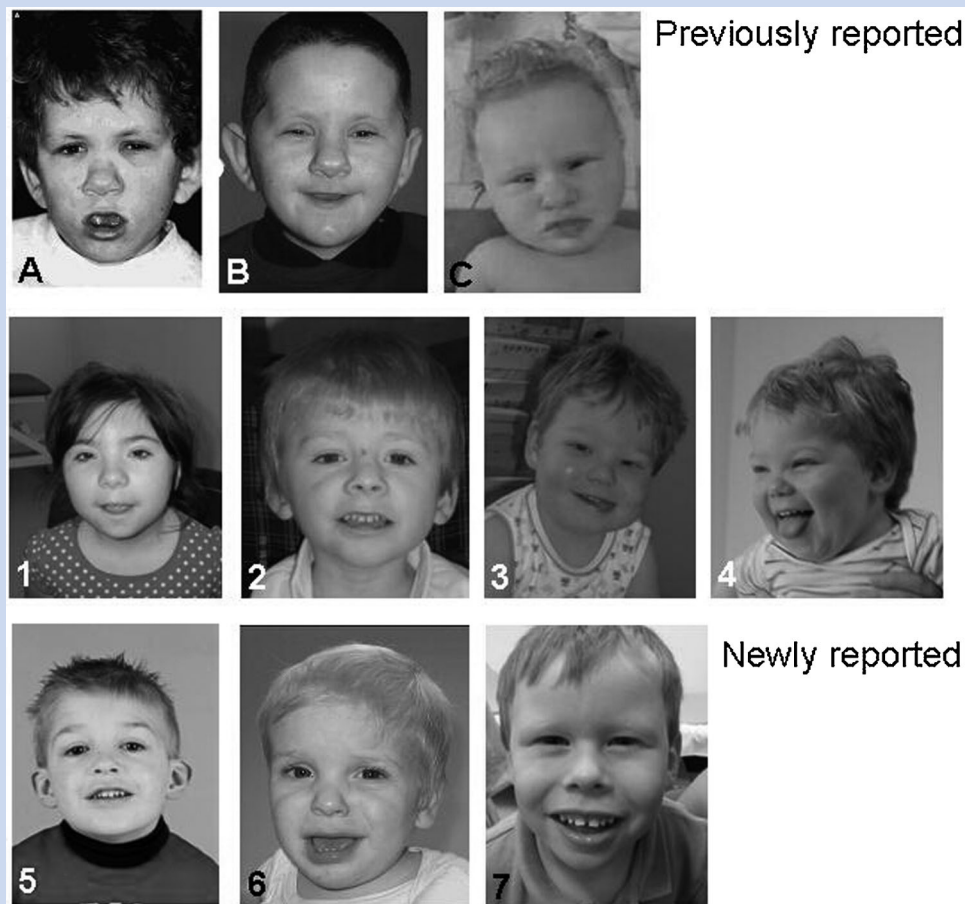## PATIENTS

### Previously Reported Individuals

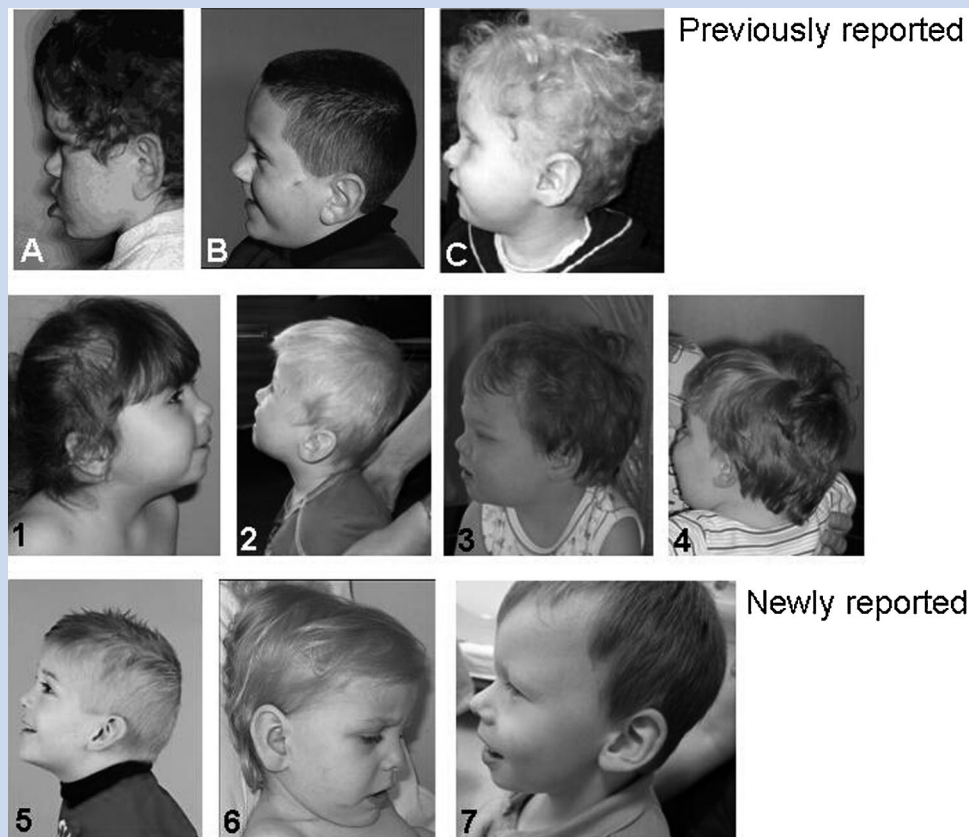
**Patient A.** The initial patient in the original report [Pierpont et al., 1998; Figs. 1A and 2A] was a boy whose development was first noted to be delayed at 6 months of age. Subsequently his milestones were severely delayed, walking first at the age of 4 years. He lost his few words of expressive speech. His growth remained below the 5th centile for height, weight, and head circumference. He suffered from myoclonic and grand mal seizures from 5 years of age, and required repeated surgery for hip subluxation and inguinal hernias. By 12 years of age, the fat pads on his feet had disappeared, and he had a progressive scoliosis.

**Patient B.** The second patient in this first report was described initially at 2<sup>1</sup>/<sub>2</sub> years of age. By 10 years he still had no speech. He too developed a scoliosis, and his facial appearance is shown in Figs. 1B and 2B.

**Patient C.** The confirmatory case report was of a 2-year-old boy with prolonged and marked feeding problems and otherwise



**FIG. 1.** Facial appearance of patients. *Upper row:* previously reported patients A, B, and C. *Lower rows:* patients 1–7 in this study. Note the monozygotic twins in the center [patients 3 and 4]. Shared facial characteristics demonstrated across the group include narrow palpebral fissures, a thin vermilion border to the upper lip, a full lower lip and full cheeks [Color figure can be seen in the online version of this article, available at [http://onlinelibrary.wiley.com/journal/10.1002/\(ISSN\)1552-4833](http://onlinelibrary.wiley.com/journal/10.1002/(ISSN)1552-4833)]



**FIG. 2.** Facial profiles of patients. *Upper row:* previously reported patients A, B, and C. *Lower rows:* patients 1–7 in this study. Note the short nose, posteriorly rotated ears and short neck in the majority of patients. [Color figure can be seen in the online version of this article, available at [http://onlinelibrary.wiley.com/journal/10.1002/\(ISSN\)1552-4833](http://onlinelibrary.wiley.com/journal/10.1002/(ISSN)1552-4833)]

moderate developmental delay [Oudesluijs et al., 2005; Figs. 1C and 2C]. Like the two previous patients reported, he required surgery for inguinal hernias and hydroceles. He also subsequently required steroid treatment for an unexplained pericardial effusion. Brain MRI showed relatively small frontal lobes, widening of lateral and third ventricles and of the subarachnoid space, a relatively large cerebellum, and delayed myelination.

The ages of the mothers of these three individuals at the time of their birth were 35, 36, and 32 years, respectively, whilst the ages of the fathers were 58, 37, and 37 years.

### Newly Identified Individuals

Patients identified with a possible diagnosis of Pierpont syndrome were those with characteristic hand and foot abnormalities and a facial appearance resembling the three previously reported patients. Their facial appearances are shown in Figures 1 and 2, and include a broad face, with short and narrow palpebral fissures, a long philtrum and thin upper lip vermilion. Growth and neurodevelopmental parameters for each patient are summarized in Table I, while Table II summarizes the dysmorphic features that were present. Four further patients with hands and feet typical of Pierpont syndrome, but without the characteristic facial features, and with otherwise divergent phenotypes were

excluded from the phenotypic analysis, but are described briefly below.

**Patient 1.** A 5-year-old girl was referred to genetics in the neonatal period for failure to thrive and dysmorphic features (Figs. 1(1) and 2(1)). The pregnancy had been complicated by a maternal deep vein thrombosis for which enoxaparin was administered. Her parents were unrelated, of Caucasian and Iranian origin respectively, and she had a healthy younger brother. At 5 years of age, her growth parameters remained significantly below the 0.4th centile, and severe feeding difficulties had necessitated gastrostomy. She had moderate global developmental delay, and also had astigmatism. Renal ultrasound showed mild pelviectasis, but her renal function was biochemically normal. Carnitine, 7-dehydrocholesterol, transferrin isoelectric focusing and urine mucopolysaccharide screen all showed normal results. On examination, she had the typical pads on her feet and hands and the characteristic facial features described above, as shown in Figures 1–4.

**Patient 2.** This 5-year-old boy was the second child of unrelated parents, and was referred to genetics at 18 months with severe global developmental delay and dysmorphism (Figs. 1(2) and 2(2)). The pregnancy was exposed to fluoxetine until 8 weeks' gestation. Fetal finger and toe pads were present, and he also had symmetrical plantar fat pads. He had normal birthweight and head circumference. At 5 years of age, his weight and head circumference were on



TABLE II. Morphological Features in Patients With Pierpont Syndrome

	A	B	C	1	2	3	4	5	6	7
Midface hypoplasia	+	+	+	+	+	+	+	+	+	—
High forehead and hairline	+	+	+	+	—	+	+	—	+	—
Long upper lip with thin vermilion border	+	+	—	+	+	+	+	+	+	+
Broad, flat philtrum	+	+	+	+	+	+	+	+	+	+
Everted lower lip	+	+	+	+/-	+	—	—	+	+	+
Full cheeks	+	+	+	+	+	+	+	+	+	+
Brachycephaly	n/k	n/k	+	+	+	+	+	+	+	n/k
Short palpebral fissures	+	+	—	+	+	+	+	+	+	+
Deep-set eyes	+	?	+	+	—	+	+	—	+	+
Strabismus	+	+	+	—	+	+	+	—	—	—
Hypertelorism/telecanthus	+	n/k	+	+	—	+	+	+	+	—
Fleshy, posteriorly rotated ears	+	+	+	+	+	—	—	+	+	—
Short, broad nose	+	+	+	+	+	+	+	+	+	+
Widely spaced teeth	+	+	+	+	+	+	+	+	+	+
Central palatal ridge	+	+	—	n/k	n/k	—	—	n/k	n/k	n/k
Short neck	+	+	+	+	—	+	+	+	+	—
Increased internipple distance, hypoplastic areolae	+	+	+	+	n/k	n/k	n/k	n/k	—	n/k
Fetal finger and toe pads	+	+	+	+	+	+	+	+	+	+
Short, broad hands and feet	?	?	—	+	+	+	+	—	+	+
Deep creases on palms, pillowing in between	+	+	+	+	+	+	+	+	+	+
Fat pads anteromedial to calcanei	+	+	+	+	+	+/-	+/-	+	+	+

and below the 0.4th centile, respectively, he had recently been diagnosed with autistic spectrum disorder, and had significant language delay (four to five single words). He was also hypermetropic. His brain MRI scan showed normal appearances. Results of a urine metabolic screen, blood electrolytes, liver, and thyroid function tests were all normal. He too had the characteristic facial appearance (Figs. 1(2) and 2(2)).

**Patients 3 and 4.** Monozygotic twin boys were born prematurely at 30 weeks' gestation to unrelated healthy parents. Facial dysmorphism was noted (Figs. 1(3,4) and 2(3,4)), and they were hypertonic in infancy. At four years of age, they had moderate motor delay, but stronger verbal skills. Both had severe feeding difficulties with intractable vomiting, suggestive of a primary gastrointestinal motility problem. Gastrostomies were required by both boys because of this, and they remained small for their age. In view of these features, extensive metabolic work up was undertaken, including urine and blood amino acids, carnitine profile, lysosomal enzymes, and transferrin isoelectric focusing. Muscle biopsy in one twin demonstrated suboptimal oxidation with borderline ATP production, and urinary ethylmalonic acid and fumarate succinate were elevated in both. Urinary purine and pyrimidine analysis showed a slightly high uracil. Their facial appearances were very typical, as were their fetal digital pads. They had fleshy hands and feet which were short and broad, with particular fullness anteromedial to the heels, as shown in Figure 3.

**Patient 5.** A 4<sup>1</sup>/<sub>2</sub>-year-old boy of unrelated healthy parents was referred to genetics with moderate developmental delay, alternating strabismus, conductive hearing loss and mild dysmorphism (Figs. 1(5) and 2(5)). He had facial features similar to other patients, but also had sparse scalp hair, with low posterior and anterior hairlines, long eyelashes and small widely spaced teeth. He had

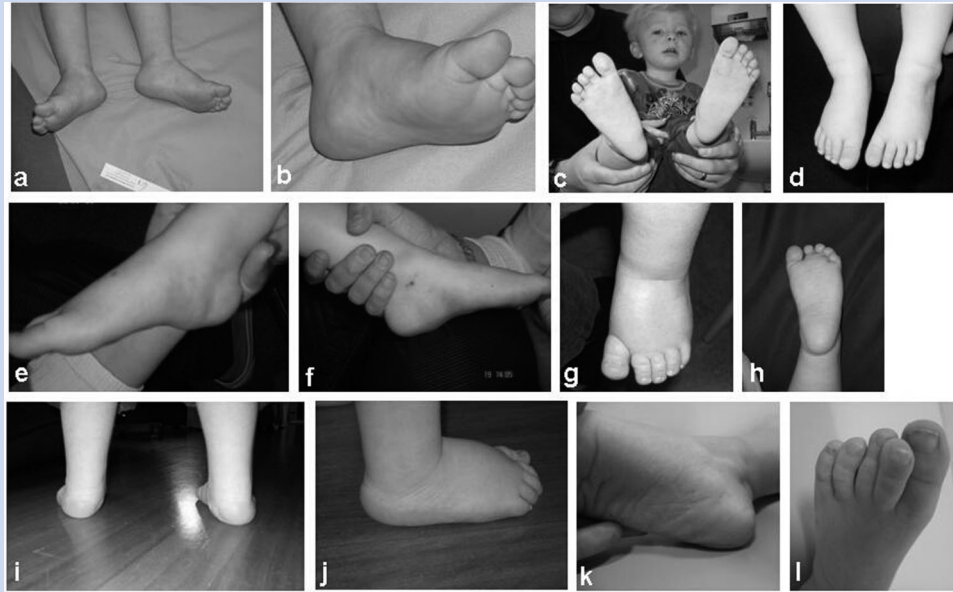
typical hands and feet with digital pads and fat pads near his heels (Fig. 3). He had no history of feeding problems, and his growth parameters were within normal limits.

**Patient 6.** A 2<sup>1</sup>/<sub>2</sub>-year-old boy, the second child of healthy unrelated parents, was referred to genetics in view of global developmental delay, microcephaly (0.4th centile, with height and weight 2nd–9th centiles) and congenital anomalies, namely unilateral retinal coloboma, undescended testes with a small scrotal naevus, and a posteriorly placed anus with a sacral dimple. Additionally, he had thin, blond hair with sparse eyebrows, eczema and dimples over his knees and elbows. He showed an unusual breathing pattern of gulping air, and had two unexplained near collapses when he vomited. He had typical findings in his hands and feet and also most of the typical facial features, including the broad face, long philtrum, and thin upper lip vermilion (Figs. 1(6) and 2(6)).

**Patient 7.** This 3-year-10-month-old boy born to non-consanguineous Caucasian parents presented with moderate developmental delay and significant gastro-esophageal reflux. There was no significant family history. He had significant speech delay, especially of expressive language. He was noted to have facial dysmorphism, see Figs. 1(7) and 2(7), fat pads anteromedial to the heels and persistent fetal digital pads. He had widely spaced teeth which erupted early (first tooth at 2 months and a full set of primary dentition by 16 months). He suffered from recurrent tonsillitis and upper respiratory tract infections, and was treated with hyoscine patches for persistent drooling.

### Patients not Included in Phenotypic Analysis

Four other patients, in whom the diagnosis of Pierpont syndrome had been considered on account of suggestive hand and foot findings and learning disability, were females with very variable



**FIG. 3. Feet of patients. a,b: patient 1; c–f: patient 2. g–j: patient 3; k,l: patient 7. Note marked plantar fat pads anteromedial to the heels and prominent toe pads. [Color figure can be seen in the online version of this article, available at [http://onlinelibrary.wiley.com/journal/10.1002/\(ISSN\)1552-4833](http://onlinelibrary.wiley.com/journal/10.1002/(ISSN)1552-4833)]**

degrees of learning disability and a diverse range of dysmorphic features. None had the characteristic facial features described above. One had an antenatally diagnosed enlarged cisterna magna, with cerebellar hypoplasia and a secundum atrial septal defect being diagnosed postnatally. A second had esophageal atresia and atrioventricular septal defect with isomerism and low birthweight. Her developmental progress was very delayed, but a cerebral hemorrhage (after cardiac surgery) and seizures were likely to have been significant contributors to this. Another patient suffered from intractable myoclonic epilepsy, cortical blindness, severe motor delay, and failure to thrive. A further patient with typical digital findings and fat pads anteromedial to her heels had a much milder phenotype than any of the other patients described here in whom the diagnosis of Pierpont syndrome has been considered. She had mild short stature and speech delay, with other subtle dysmorphic features including mild generalized hirsutism and resorption of her anterior maxillary tooth roots.

## METHODS

Routine karyotyping was carried out in all patients. The genomes of patients C and 1–3 were then screened for copy number alterations using the Affymetrix NspI 250K SNP array (Affymetrix, Santa Clara, CA). SNP array experiments were performed according to the manufacturer's protocols. Copy number estimates were determined using the CNAG software package (v2.0) [Nannya et al., 2005]. The deletion found using this in patient 3 was assessed in his parents and identical twin brother (patient 4) by FISH, as shown in Table I.

## RESULTS

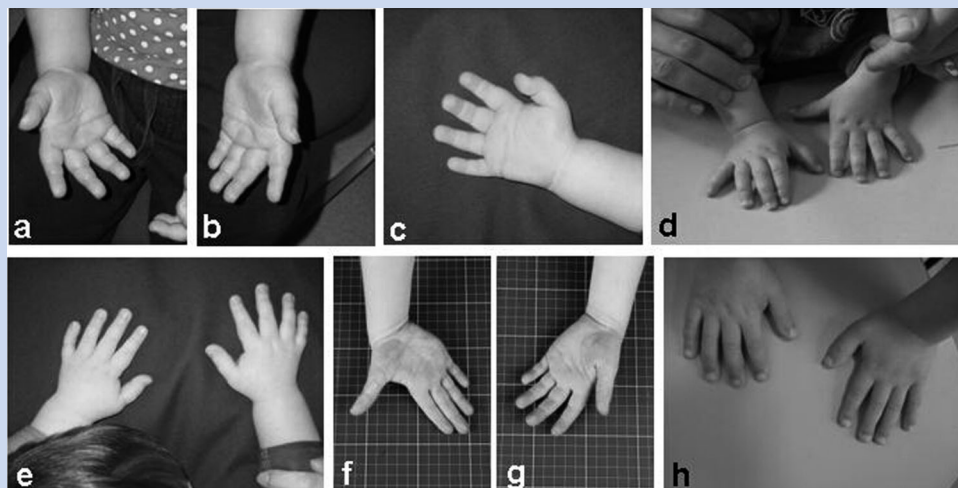
In all patients, routine chromosome analysis demonstrated no abnormalities. The results of other investigations in each of these individuals, along with their clinical features, are described in Table I. Facial appearances are shown in Figures 1 and 2, while feet and hands are shown in Figures 3 and 4. Dysmorphic features are listed in Table II, and considered further in the discussion below, while Table III summarizes growth and developmental progress across the group of patients.

## DISCUSSION

Within this case series, there were distinctive characteristics that were common across the majority of individuals. These appeared to be within four main areas: craniofacial features, findings in the hands and feet, neurodevelopment, and feeding and growth problems. Each of these are discussed below.

### Craniofacial Features

Facial features include a broad face, high anterior hairline, and narrow palpebral fissures, which can take on a crescent moon shape when smiling due to fullness of the cheeks in some patients. The eyes also appeared deep-set in the original patients and in several of the newly reported individuals. The patients' noses are frequently noted to be broad, with a relatively broad tip and hypoplastic alae. A prominent premaxilla accentuating a long, smooth philtrum, with a thin upper lip vermilion and full lower lip appear typical, as do large, fleshy ears. These are shown in Figures 1 and 2. Further common



**FIG. 4.** Hands of patients. a,b: patient 1; c: patient 2; d,e: patient 3; f,g: patient 5; h: patient 7. Note fleshy appearance to the hands, including deep palmar creases. [Color figure can be seen in the online version of this article, available at [http://onlinelibrary.wiley.com/journal/10.1002/\(ISSN\)1552-4833](http://onlinelibrary.wiley.com/journal/10.1002/(ISSN)1552-4833)]

features in the patients appear to include brachycephaly and small, widely spaced teeth. When smiling, the similarity between affected individuals becomes even more apparent, as shown in Figure 5. We consider patients 1–4 in this study to bear the most resemblance facially to the original three patients.

Microcephaly was present in the majority of patients. In four patients, this was proportionate to their other growth parameters, and in three it was disproportionate, while two had a normal head circumference. Although this does not point to an overall pattern of head growth that might be characteristic for this patient group, most patients reported here did have some similarities of head shape, with a brachycephalic appearance.

### Fetal Digital Pads and Fat Pads Anteromedial to the Heels

Short, broad feet with plantar fat pads, deep creases, and toe pads were present, as shown in Figure 3. Similarly, broad hands, with “pillowing” [as described by Pierpont et al., 1998] of the tissue of the palms, deep palmar creases, and fetal pads were present, as shown in Figure 4. It is important to note that the fat pads in the two original patients became less prominent with time; in the first, they had disappeared by 12 years of age, and this is also the case for some of the patients newly reported here for whom longer term follow-up data are available.

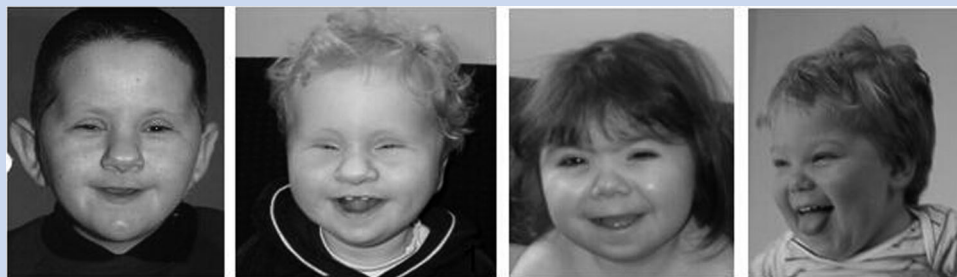Persistent fetal finger and toe pads are a relatively non-specific finding, as they are known to occur in several recognizable dysmorphic syndromes, including notably in Kabuki syndrome [Adam and Hudgins, 2005], as well as in normal individuals. In contrast, fat pads anteromedial to the heels, whilst they have been noted in neurofibromatosis type I [personal observation] and microdeletion at 8q24 with a Langer–Giedion phenotype [McBrien et al., 2008], are much less commonly observed, suggesting that these may be a feature more specifically associated with, if not pathognomic of, Pierpont syndrome. To avoid unwarranted suspicion of Pierpont syndrome, it is important to recognize that fat pads anteromedial to the heels, like persistent fetal digital pads, may occur both in other syndromic conditions and in normal individuals.

### Neurodevelopmental and Neurological Features

A variable degree of learning disability has been demonstrated in patients with a possible diagnosis of Pierpont syndrome. The group reported here all had moderate or severe developmental delay. No patients with features of this syndrome have yet been identified with normal intellectual function, though the short history over which it has been recognized, and the small numbers observed to date mean that this cannot currently be excluded as a possibility. While the

**TABLE III.** Growth and Developmental Parameters in Patients With Pierpont Syndrome

Growth	
Height centile	<0.4th–9th
Weight centile	<0.4th–50th
OFC centile	<0.4th–10th
Neurodevelopmental progress	
Intellectual disability	Moderate [9] Severe [1]
Speech	None [4] Single words [6]
Walking	18 months–2 years
Seizures	Absences [3]
Feeding problems	Nasogastric feeding [4] Gastrostomy [3] Severe vomiting [3]



**FIG. 5. Faces of patients when smiling.** Accentuation of the facial similarities between patients in this situation is shown here in previously reported patients A. Faces of patients (left to right): B from the original report, C from the confirmatory report, 1 and 4 from this study. Note “crescent moon” appearance of the palpebral fissures due to fullness of the cheeks. [Color figure can be seen in the online version of this article, available at [http://onlinelibrary.wiley.com/journal/10.1002/\(ISSN\)1552-4833](http://onlinelibrary.wiley.com/journal/10.1002/(ISSN)1552-4833)]

degree of learning disability of patients described here was variable, all had at least moderate developmental delay. The original three patients had no speech development, or this was limited to very few single words. The newly described patients mostly have better speech than this, though in all cases this was significantly delayed. At this stage, there seem no recurrent personality traits or behavioral features that appear characteristic of the syndrome.

Seizures, in particular absence seizures, have been reported in several patients. While they are clearly not universal, it currently appears that epilepsy may be sufficiently more common in children with Pierpont syndrome to be considered a feature of the condition.

### Nutrition and Growth

Difficulties in feeding were not seen in all patients in this cohort, but were both severe and persistent in several of them. The extent of feeding difficulties was more severe than the degree of other developmental problems observed in many of these patients. While all three of the original patients reported had notable constipation, this was not a recurrent feature in those newly described here. However, the upper gastrointestinal manifestations of the monozygotic twins, patients 3 and 4, caused them significant problems, and several others in the cohort had significant feeding difficulty, including the need for gastrostomy. Patients 3 and 4, as a result of their feeding problems, underwent extensive metabolic investigations as mentioned above in the case description. Most of the results for these were normal or borderline, and the significance of the abnormalities identified to their phenotype is uncertain.

The patterns of growth in the group as a whole were varied, with more children being small for their age than overgrown. Given the severity of the feeding problems observed in many of the children reported here, we would suggest that these could be considered a significant feature of, and potential marker for, the condition.

Other findings that were noted in patients of the original reports include genitourinary abnormalities including inguinal hernias, small penis, and hypoplastic scrotum. These were not noted in the further patients newly described here, whereas undescended testes have been described in one additional individual (patient 6). The significance of the additional finding of ocular coloboma in this

individual, when such a feature has not been identified in any of the other patients with possible Pierpont syndrome, is currently uncertain. Although it had not yet occurred in any patient newly reported here, the development of scoliosis in the two patients of the original report suggests that this is a feature for which to be alert in patients with a possible diagnosis of Pierpont syndrome.

The median paternal age of new and previously reported patients was 37 years [mean: 42 years], of six paternal details available, with a range of 27–58 years. One of the six pregnancies reported for the first time here was known to have been exposed to maternal cigarette smoking, and maternal ages at delivery ranged from 20 to 39 years. These maternal factors appear similar to those observed across normal pregnancies in the population.

It is not yet absolutely clear whether Pierpont syndrome is a distinct entity. However, the three original patients shared many distinctive phenotypic characteristics, especially facially, including a high forehead, hypoplastic midface, a short, broad nose and small, widely spaced teeth. The patients reported here, especially patients 1–4, all share most of these facial similarities and, similarly have significant developmental delay. All have persistent fetal digital pads, and all have fat pads or fullness anteromedial to their heels.

Investigations to date, including SNP array at 250 kb resolution (or greater) where possible in these patients (Table I), have not shown a cause for their syndromic features. The observation of advanced paternal age in all three previously published patients, and in several of those newly reported here, makes a new dominant mutational mechanism, for example, resulting in a point mutation in an as yet unidentified gene, a potential explanation, as for a growing range of *de novo* dominant developmental disorders, examples of which include Costello syndrome [Aoki et al., 2005] and other neurocardiofaciocutaneous disorders [Burkitt Wright and Kerr, 2010], and Crouzon and Apert syndromes [Wilkie et al., 1995]. As for many other syndromic conditions, especially those for which the genetic basis remains unclear, environmental factors or other modifying influences may be important.

All three individuals in previously published literature have been male, but this new case series included a female with typical features (patient 1), making the previous postulation of X-linked recessive inheritance less likely. As with other currently unexplained syn-



dromes, uncovering the mechanisms of inheritance, and the loci that may be involved, will be important both in confirming recurrence risks for families and understanding the pathogenesis of the condition. To date, there has been no known instance of a child with a diagnosis of Pierpont syndrome being born to consanguineous parents, nor of any affected non-twin sibling pairs.

## CONCLUSIONS

Pierpont syndrome has been described as a rare multiple congenital anomaly syndrome with as yet unknown etiology, on the basis of three identified individuals in two reports. We report on seven further possible cases of this syndrome. These patients were ascertained by the presence of fat pads anteromedial to their heels, fetal digital pads, and learning disability and many of these individuals did share significant facial similarities. However, there were also patients identified with both learning disability and typical hand and foot findings whose facial features were not characteristic, leading us to suggest that they do not have Pierpont syndrome, but rather are affected with other conditions. The fact that several of the patients with apparently typical features of Pierpont syndrome have had older fathers raises the possibility of advanced paternal age as a risk factor for the condition. In view of the possibility of mutations in a single gene, or group of functionally related genes, being responsible for the phenotypes described here, this cohort of patients would be worthwhile to investigate by whole exome sequencing or other technologies.

## ACKNOWLEDGMENTS

EBW is a Wellcome Trust clinical research training fellow supported by the UK National Institute for Health Research's

Manchester Biomedical Research Centre. The authors have no competing interests to declare.

## REFERENCES

- Adam MP, Hudgins L. 2005. Kabuki syndrome: A review. *Clin Genet* 67:209–219.
- Aoki Y, Niihori T, Kawame H, Kurosawa K, Ohashi H, Tanaka Y, Filocamo M, Kato K, Suzuki Y, Kure S, Matsubara Y. 2005. Germline mutations in RAS proto-oncogene cause Costello syndrome. *Nat Genet* 38:1038–1040.
- Burkitt Wright EMM, Kerr BA. 2010. RAS-MAPK pathway disorders: Important causes of congenital heart disease, feeding difficulties, developmental delay and short stature. *Arch Dis Child* 95:724–730.
- McBrien J, Crolla JA, Huang S, Kelleher J, Gleeson J, Lynch SA. 2008. Further case of microdeletion of 8q24 with phenotype overlapping Langer-Giedion without TRPS1 deletion. *Am J Med Genet Part A* 146A:1587–1592.
- Nannya Y, Sanada M, Nakasaki K, Hosoya N, Wang L, Hangaishi A, Kurokawa M, Chiba S, Bailey DK, Kennedy GC, Ogawa S. 2005. A robust algorithm for copy number detection using high-density oligonucleotide single nucleotide polymorphism genotyping arrays. *Cancer Res* 65:6071–6079.
- Oudesluijs GG, Hordijk R, Boon M, Sijens PE, Hennekam RC. 2005. Plantar lipomatosis, unusual facies, and developmental delay: Confirmation of Pierpont syndrome. *Am J Med Genet Part A* 137A:77–80.
- Pierpont ME, Stewart FJ, Gorlin RJ. 1998. Plantar lipomatosis, unusual facial phenotype and developmental delay: A new MCA/MR syndrome. *Am J Med Genet* 75:18–21.
- Wilkie AOM, Slaney SF, Oldridge M, Poole MD, Ashworth GJ, Hockley AD, Hayward RD, David DJ, Pulleyn LJ, Rutland P, Malcolm S, Winter RM, Reardon W. 1995. Apert syndrome results from localized mutations of FGFR2 and is allelic with Crouzon syndrome. *Nat Genet* 9:165–172.