



BRIEF REPORT

A mysterious cause of recurrent acute liver dysfunction for over a decade

Ahmet Burak Dirim^{1,*}, Tugba Kalayci², Merve Guzel Dirim³, Semra Demir⁴, Bilger Cavus⁵, Asli Cifcibasi Ormeci⁵, Filiz Akyuz⁵ and Sabahattin Kaymakoglu⁵

¹Division of Nephrology, Department of Internal Medicine, Istanbul Faculty of Medicine, Istanbul University, Istanbul, Turkey; ²Division of Medical Genetics, Department of Internal Medicine, Istanbul Faculty of Medicine, Istanbul University, Istanbul, Turkey; ³Department of Internal Medicine, Istanbul Faculty of Medicine, Istanbul University, Istanbul, Turkey; ⁴Division of Allergy and Immunology, Department of Internal Medicine, Istanbul Faculty of Medicine, Istanbul University, Istanbul, Turkey; ⁵Division of Gastroenterology, Department of Internal Medicine, Istanbul Faculty of Medicine, Istanbul University, Istanbul, Turkey

*Corresponding author. Department of Internal Medicine, Division of Nephrology, Istanbul University, Istanbul Faculty of Medicine, Istanbul, Turkey. Tel: +90-212 414 20 00/33040; Fax: +90-212 414 20 28; Email: ahmetburakdirim@gmail.com

Key words: recurrent acute liver failure; NBAS (neuroblastoma-amplified sequence); immunodysregulation; clinical exome sequencing

Introduction

Acute liver failure (ALF) is an uncommon disease in pediatric cases. Etiology includes infections, autoimmune diseases, inborn errors of metabolism, and intoxications. Metabolic disorders account for 25% of resolved cases. However, the etiology remains unknown in half of pediatric ALF [1]. The recognition of molecular etiopathogenesis has been facilitated after the common use of next-generation sequencing techniques. Recently, biallelic variants in neuroblastoma-amplified sequence (NBAS), Leucyl-tRNA synthetase 1 (LARS1), and RAD50-interacting protein (RINT1) were identified in recurrent ALF (RALF) [2–4]. In a multicenter and multinational study performed by Staufner *et al.* [5], 110 patients with pathogenic NBAS variants were reported, suggesting that NBAS might constitute a substantial part of unsolved RALF. Although there are no clear data on the ethnic diversity, as RALF-related genes are recessively inherited, it should be considered in populations with a high consanguinity rate, including those in Turkey. Here we report a patient

with a history of idiopathic RALF that is resolved after 12 years by the detection of novel and rare compound heterozygous variants in the NBAS gene on clinical exome sequencing.

Case report

A 19-year-old female was admitted to the emergency department with complaints of malaise and nausea for 2 days. Her temperature was calculated as 38.5 °C 3 days before hospital admission. Her history was notable for recurrent hepatitis and ALF episodes with an unknown etiology. The alanine aminotransferase (ALT) level was 345 U/L (reference range, 7–35 U/L) and the aspartate aminotransferase (AST) level was 278 U/L (reference range, 5–42 U/L) at admission. Alkaline phosphatase (ALP), gamma-glutamyltransferase (GGT), international-normalized-ratio (INR), and bilirubin levels were normal. We hospitalized the patient for idiopathic recurrent acute liver dysfunction.

When the prior medical history was evaluated elaborately, it was recognized that the first ALF attack was manifested with

Submitted: 10 July 2021; Revised: 12 October 2021; Accepted: 25 October 2021

© The Author(s) 2021. Published by Oxford University Press and Sixth Affiliated Hospital of Sun Yat-sen University

This is an Open Access article distributed under the terms of the Creative Commons Attribution-NonCommercial License (<https://creativecommons.org/licenses/by-nc/4.0/>), which permits non-commercial re-use, distribution, and reproduction in any medium, provided the original work is properly cited. For commercial re-use, please contact journals.permissions@oup.com

gastrointestinal bleeding, coagulopathy, jaundice, and hepatic encephalopathy at the age of 7 years. The ALT level was 6,846 U/L, the AST level was 5,971 U/L, the ALP level was 205 U/L (reference range, 35–105 U/L), and the GGT level was 110 U/L (reference range, 5–85 U/L). The INR was 3.2 (reference range, 0.85–1.2) and the direct bilirubin level was 4 mg/dL (reference range, <0.3 mg/dL). The patient was healthy until this first ALF attack and the family history was unremarkable. Abdominal computed tomography was normal for the liver. Patchy hemorrhages were detected with no signs of portal hypertension during esophago-gastroscopy. Viral serology, metabolic-disease panels, and auto-immune screening were negative. Liver-function tests were normalized and she recovered without sequela after 2 weeks of supportive treatment in the intensive care unit.

The patient had three more ALF episodes in the next 3 years. Liver biopsy was performed in the course of the third attack. However, results of the liver biopsy were not diagnostic and it showed diffuse hepatocellular regeneration. Recurrent ALF with unexplainable etiology raised a suspicion of Munchausen by proxy. Her parents were separated from the child via a court order because of high serum levels of lithium in the toxicological screen during an attack. Despite the separation of the patient from the family, two new episodes were observed in the next year and the lithium levels were normal at these presentations. Attacks had a milder clinical course characterized by elevated liver enzymes without liver failure in the last couple of years. We hospitalized her during the 11th attack.

Liver enzymes were normalized in 1 week after hospitalization. Intriguingly, she denoted that recurrent ALF attacks were triggered by fever. Hence, we suspected infantile liver failure syndrome 2 (ILFS2) related to NBAS or (ILFS3) related to RINT1. An immunological assessment showed a decreased natural killer (NK) cell count and low IgA, IgE, IgG1, IgG2, and IgG3 levels. Also, a Pelger-Huët anomaly was seen in the peripheral blood smear (Figure 1A). A skeletal survey revealed no abnormalities. According to these findings, ILFS2 diagnosis was more likely than ILFS3. Clinical exome sequencing (CES) was performed, which confirmed the NBAS-related ILFS (ILFS2).

CES analysis revealed novel c.1226C>T and a known ultra-rare c.2479_2498del heterozygous variants in the NBAS gene.

Parental screening showed that c.1226C>T was inherited from her father and c.2479_2498del was inherited from her mother (Figure 1B).

Discussion

Pathogenic variants in the NBAS gene cause different clinical findings in patients, including SOPH syndrome (short stature, optic atrophy, and Pelger-Huët anomaly) and ILFS2 [1, 4, 6]. RALF is typically triggered by fever in patients with ILFS2 and ILFS3. However, there are some distinct clinical features between these two conditions. While vertebral body abnormalities are one of the findings of ILFS3 [4, 7, 8], osteogenesis imperfecta-like phenotype is frequently seen in ILFS2 [1, 7–10]. Our patient had no skeletal features. However, she was osteopenic, which might be related to NBAS deficiency.

ILFS2 is characterized by unique clinical and laboratory characteristics. Features such as the Pelger-Huët anomaly, osteopenia, short stature, joint hypermobility, and vomiting during attacks were present in our patient as consistent with the cases reported in the literature [1, 4, 6–8] (Supplementary Table 1). Liver biopsy usually shows non-specific findings in NBAS deficiency. However, dilated endoplasmic reticulum, abnormal mitochondria, or dense mitochondrial matrix could be found by scanning electron microscopy [11].

Besides those features, NBAS deficiency could cause immunologic abnormalities and immunodysregulation. Hypogammaglobulinemia and low levels of CD19(+) B and NK cells were described in this entity. Elevated IgE levels and an increased CD4/CD8 ratio could also be observed [12]. Our case had a decreased NK cell count and low IgA, IgE, IgG1, IgG2, and IgG3 levels. Intriguingly, the IgG4 concentration was within normal limits. IgG subgroup analyses have not been reported previously, as far as we know.

There is no definite treatment for NBAS deficiency. Antipyretics for reducing the systemic inflammatory response and parenteral high-dose glucose treatment could be beneficial during attacks [1]. Additionally, intravenous immunoglobulin (IVIG) treatment to prevent infections could be reasonable in patients with hypogammaglobulinemia [12]. For this reason, we

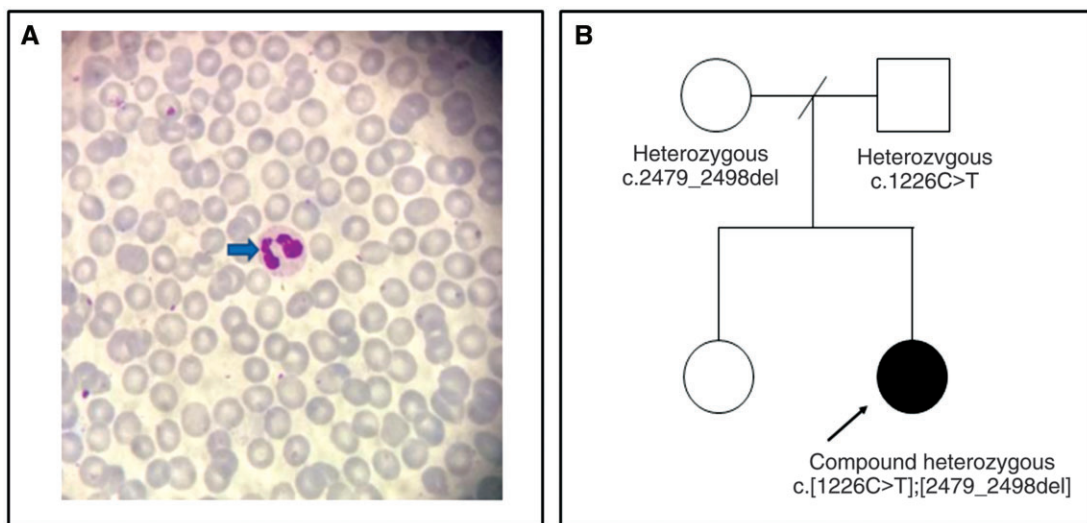


Figure 1. Peripheral blood smear. (A) Pelger-Huët anomaly of the proband. (B) Pedigree and molecular results of the proband and parents. Clinical exome sequencing analysis revealed heterozygous c.1226C>T and c.2479_2498del variants in the NBAS gene in the proband. Parental analysis showed that c.1226C>T was inherited from the father and c.2479_2498del was inherited from the mother, with a confirmed compound heterozygous form in the proband c.[1226C>T];[2479_2498del].

started IVIG 0.4 g/kg monthly to prevent RALF triggered by infections and fever. No attack has been observed for a year so far.

In conclusion, NBAS deficiency should be kept in mind in RALF triggered by fever. Patients could get a late diagnosis in adulthood, as our patient did. Diagnosis of NBAS deficiency is based on genetic screening and next-generation sequencing is a valuable, cost-effective method especially in genetically heterogeneous disorders. Immunodeficiency-related recurrent infections could also contribute to the incidents of ALF. Hence, IVIG treatment in NBAS-deficient patients with hypogammaglobulinemia could be beneficial to prevent RALF.

Supplementary Data

Supplementary data is available at *Gastroenterology Report* online.

Authors' contributions

Original draft: A.B.D. and T.K. Critical revision: M.G.D., S.D., B.C., A.C.O., F.A., and S.K. All authors reviewed and approved the final version.

Funding

None.

Acknowledgements

Written informed consent was obtained from the patient.

Conflicts of interest

None declared.

References

1. Staufner C, Haack TB, Köpke MG *et al.* Recurrent acute liver failure due to NBAS deficiency: phenotypic spectrum, disease mechanisms, and therapeutic concepts. *J Inherit Metab Dis* 2016;**39**:3–16.
2. Casey JP, McGettigan P, Lynam-Lennon N *et al.* Identification of a mutation in LARS as a novel cause of infantile hepatopathy. *Mol Genet Metab* 2012;**106**:351–8.
3. Arasaki K, Takagi D, Furuno A *et al.* A new role for RINT-1 in SNARE complex assembly at the trans-Golgi network in coordination with the COG complex. *Mol Biol Cell* 2013;**24**:2907–17.
4. Haack TB, Staufner C, Köpke MG *et al.* Biallelic mutations in NBAS cause recurrent acute liver failure with onset in infancy. *Am J Hum Genet* 2015;**97**:163–9.
5. Staufner C, Peters B, Wagner M *et al.* Defining clinical subgroups and genotype-phenotype correlations in NBAS-associated disease across 110 patients. *Genet Med* 2020;**22**:610–21.
6. Jiang B, Xiao F, Li X *et al.* Case report: pediatric recurrent acute liver failure caused by Neuroblastoma Amplified Sequence (NBAS) gene mutations. *Front Pediatr* 2020;**8**:607005.
7. Li X, Cheng Q, Li N *et al.* SOPH syndrome with growth hormone deficiency, normal bone age, and novel compound heterozygous mutations in NBAS. *Fetal Pediatr Pathol* 2018;**37**:404–10.
8. Cousin MA, Conboy E, Wang JS *et al.* RINT1 Bi-allelic variations cause infantile-onset recurrent acute liver failure and skeletal abnormalities. *Am J Hum Genet* 2019;**105**:108–21.
9. Aoki T, Ichimura S, Itoh A *et al.* Identification of the neuroblastoma-amplified gene product as a component of the syntaxin 18 complex implicated in Golgi-to-endoplasmic reticulum retrograde transport. *Mol Biol Cell* 2009;**20**:2639–49.
10. Uemura T, Sato T, Aoki T *et al.* p31 deficiency influences endoplasmic reticulum tubular morphology and cell survival. *Mol Cell Biol* 2009;**29**:1869–81.
11. Li JQ, Qiu YL, Gong JY *et al.* Novel NBAS mutations and fever-related recurrent acute liver failure in Chinese children: a retrospective study. *BMC Gastroenterol* 2017;**17**:77.
12. Ricci S, Lodi L, Serranti D *et al.* Immunological features of neuroblastoma amplified sequence deficiency: report of the first case identified through newborn screening for primary immunodeficiency and review of the literature. *Front Immunol* 2019;**10**:1955.