

Safety and Efficacy of Early Tube Removal Following Percutaneous Transhepatic Gallbladder Drainage: an Observational Study

Hidehiro Kamezaki, MD, PhD,* Toshio Tsuyuguchi, MD, PhD,†
 Kenji Shimura, MD,‡ Dai Sakamoto, MD, PhD,* Junichi Senoo, MD, PhD,*
 Hideaki Mizumoto, MD, PhD,§ Michio Kubota, MD,||
 Yu Yoshida, MD, PhD,¶ Ryosaku Azemoto, MD, PhD,¶
 Harutoshi Sugiyama, MD, PhD,† and Naoya Kato, MD, PhD#

Background: There are currently no guidelines concerning the advisability and timing of tube removal following percutaneous transhepatic gallbladder drainage (PTGBD). The present study aimed to assess the feasibility and risks of early removal of the PTGBD tube under the scenario of subsiding inflammation, patent cystic and common bile ducts, and absence of intraperitoneal leakage.

Methods: Patient background and outcomes were assessed retrospectively in 701 cases of acute cholecystitis treated with PTGBD. The median times until tube removal and tube dislodgement and the cumulative rates of tube dislodgement were calculated.

Results: Tube removal was performed in 275 patients after a median time of 16 days (range: 6 to 213 d); biliary peritonitis was observed in 2 patients following tube removal. Tubes were removed in 8 and 35 patients within 7 and 10 days, respectively. Tube dislodgement was observed in 82 patients after a median time of 12 days (range: 1 to 125 d).

Conclusion: The present study suggests that drainage tube removal is safe and effective when performed after a short drainage period of 7 to 10 days if the criteria for the removal of the drainage tube were met.

Key Words: percutaneous, gallbladder, drainage, tube removal, acute cholecystitis, peritonitis

(*Surg Laparosc Endosc Percutan Tech* 2020;30:164–168)

Acute cholecystitis is a very common inflammatory disease of the gallbladder. Early or urgent cholecystectomy is essential for patients with acute cholecystitis who do not respond to

conservative treatment.^{1,2} Even though cholecystectomy appears to be a safe treatment option for patients with acute cholecystitis, a recently published systematic review and meta-analysis study has reported a mortality rate of 3.5% in the elderly population.³ Acute cholecystitis demands proper treatment and may be fatal in the absence of immediate treatment during the acute phase.⁴

Percutaneous transhepatic gallbladder drainage (PTGBD) is widely recognized as a safe and effective method for the treatment of acute cholecystitis, and it should be immediately performed in cases where early cholecystectomy is not indicated.⁵ The 2013 Tokyo Guidelines for the management of acute cholecystitis recommend PTGBD as the first option for surgical intervention in patients with acute cholecystitis or as a rescue treatment in hospitals when the option for cholecystectomy is unavailable.^{1,2} PTGBD has a 100% technical success rate⁶ and a low mortality rate of 0% to 4%.^{7–9} The most recently published 2018 Tokyo Guidelines for the management of acute cholecystitis state that PTGBD should be performed in cases of grade II cholecystitis wherein inflammation cannot be controlled by antibiotics and general supportive care, in cases of grade III cholecystitis with negative predictive factors (eg, jaundice, neurological, or respiratory dysfunction), in cases of grade III cholecystitis without negative predictive factors but with a poor performance status, and in cases not treated in advanced centers with experienced surgeons and intensive care units.¹⁰ However, problems such as patient discomfort and tube dislodgement can develop when the drainage period is prolonged, and a shorter drainage period is therefore desirable. The recent guidelines provided new evidence and recommendations for gallbladder drainage, antimicrobial therapy, and the role of surgical intervention, but did not provide any insights into the advisability and timing of tube removal after PTGBD. The present study aimed to analyze the outcomes in a large sample set of PTGBD cases to assess the timing of tube removal after PTGBD and the feasibility and risks of early tube removal. We hypothesized that tube removal after PTGBD could be safe and effective when performed after a shorter drainage period.

METHODS

Study Design and Patient Background

This retrospective observational study of patient backgrounds and outcomes included 701 patients with acute cholecystitis who were treated with PTGBD following the 2013 Tokyo Guidelines during the 44-month period between April 2014 and November 2017. The patients were recruited from the Eastern Chiba Medical Center (75 patients), Asahi General

Received for publication June 24, 2019; accepted November 6, 2019.
 From the *Department of Gastroenterology, Eastern Chiba Medical Center, Togane City; †Endoscopy Center, Chiba University Hospital, Chiba; ‡Department of Gastroenterology, Asahi General Hospital, Asahi; §Department of Gastroenterology, Funabashi Municipal Medical Center, Funabashi; ¶Department of Gastroenterology, Kimitsu Chuo Hospital, Kisarazu; #Department of Gastroenterology, Graduate School of Medicine, Chiba University Hospital, Chiba Prefecture; and ||Department of Gastroenterology, Numazu City Hospital, Numazu, Shizuoka Prefecture, Japan.

The authors declare no conflicts of interest.

Reprints: Hidehiro Kamezaki, MD, PhD, Department of Gastroenterology, Eastern Chiba Medical Center, 3-6-2, Okayamadai, Togane City 283-8686, Chiba Prefecture, Japan (e-mail: ugn29814@yahoo.co.jp).

Copyright © 2020 The Author(s). Published by Wolters Kluwer Health, Inc. This is an open-access article distributed under the terms of the Creative Commons Attribution-Non Commercial-No Derivatives License 4.0 (CCBY-NC-ND), where it is permissible to download and share the work provided it is properly cited. The work cannot be changed in any way or used commercially without permission from the journal.

Hospital (381 patients), Funabashi Municipal Medical Center (23 patients), Numazu City Hospital (57 patients), and Kimitsu Chuo Hospital (165 patients). Patients with mild, moderate, or severe acute cholecystitis who were treated with PTGBD and who were older than 20 years of age were included in the study. The study design was approved by the Ethics Committee of Eastern Chiba Medical Center (Registration No. 75). Informed consent was not required due to the retrospective nature of the study.

Surgical Methods

The surgical procedure for PTGBD used in the study was the same as that previously used by Wise and colleagues.^{11,12} In brief, following ultrasound-guided transhepatic gallbladder puncture using an 18 G ultrasonic needle (Hanaco Medical, Saitama, Japan), a pigtail catheter (7 or 8 Fr; Hanaco Medical) was placed in the gallbladder using a guidewire (Radifocus, outer diameter 0.89 mm; Terumo Medical, Tokyo, Japan) under fluoroscopy (Seldinger technique). The drains were not sutured to the skin, but fixed using a special stabilizer (Create Medic, Yokohama, Japan).

PTGBD tube removal was performed in cases wherein elective surgery was delayed (most commonly defined as at least 6 weeks)¹⁰ or was not an option. Tube removal was performed when the patients were still hospitalized. Before the removal of the drainage tube, the feasibility of tube removal was assessed by 3 criteria: (1) the inflammation was subsiding, (2) the cystic duct and common bile duct were visible on tube imaging, and (3) no intraperitoneal leakage was detected. Subsidence of inflammation was confirmed by the decline of fever, a normal blood cell count, and resolution of abdominal pain. A visible cystic and common bile duct and intraperitoneal leakage were confirmed by fluoroscopy after the injection of the cholecystostomy catheter with contrast material. Frontal spot films were obtained to confirm the patency and visibility of the cystic duct, common bile duct, and duodenum (Fig. 1), and to assess intraperitoneal leakage.

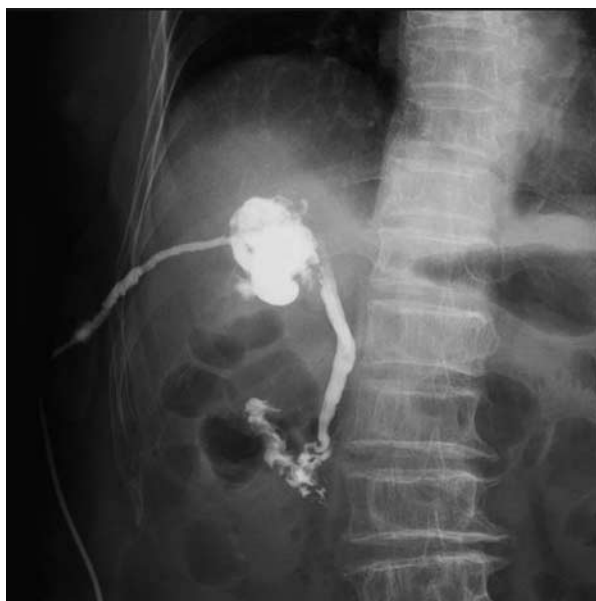


FIGURE 1. Fluoroscopic image of frontal spot film showing the cystic duct and common bile duct with no intraperitoneal leakage.

A guidewire was used for tube removal to straighten the catheter tip, which might otherwise be coiled or hooked, and thereby prevent any injury to internal organs. Subjects whose tubes could not be removed after several attempts, or who did not undergo tube removal or tube dislodgement, were monitored for inflammation during the observation period. Patients with intraperitoneal leakage or nonpatent ducts were monitored conservatively using antibiotics and general supportive care. Biliary peritonitis was diagnosed by the presence of fever, elevated white blood cell counts, and abdominal pain.

Data Analysis

The median patient age and median time until PTGBD tube removal were recorded. Patient characteristics were compared between those with or without tube removal, and with or without tube dislodgement using the Mann-Whitney test for continuous variables (eg, age) and χ^2 tests for categorical variables (eg, sex, severity of acute cholecystitis). In addition, the median time to tube dislodgement and cumulative tube dislodgement rates were determined. Complications following tube removal and tube dislodgement were noted. Cumulative rates of cholecystitis after tube removal and tube dislodgement rates were evaluated using the Kaplan-Meier method.

RESULTS

Patient Background

The patient cohort was comprised of 456 (65%) male individuals and 245 (35%) female individuals and had a median age of 76 years (range: 20 to 99 y). Acute cholecystitis was determined to be mild, moderate, and severe in 34 (5%), 524 (75%), and 143 (20%) patients, respectively. Patients were followed up for a median of 22 days (range: 1 to 1050 d) following PTGBD tube placement.

Tube Removal

Tube removal was performed in 275 (39.2%) patients (Table 1, Fig. 2). Patients with tube removal had a higher median age compared with patients without tube removal (78 vs. 74.5 y; $P < 0.001$). There were no significant differences in sex composition and severity of acute cholecystitis between the 2 groups. The median time until tube removal was 16 days (range: 6 to 213 d); of the 275 patients, tube removal was performed within 7 days in 8 (3%) patients, between 8 and 14 days in 108 (39%) patients, between 15 and 21 days in 86 (31%) patients, between 22 and 28 days in 33 (12%) patients, between 29 and 56 days in 24 (9%) patients, and beyond 57 days in 16 (6%) patients. Patients were followed up for a median of 73 days (range: 0 to 1291 d) following tube removal.

Of the 275 patients with tube removal, biliary peritonitis was observed in only 2 (0.7%) patients (Fig. 2) who had their tubes removed after 23 and 26 days, respectively; biliary peritonitis was not observed in any of the 35 (12.7%)

TABLE 1. Characteristics of Patients With and Without Percutaneous Transhepatic Gallbladder Drainage Tube Removal

	Tube Removal (N = 275)	Nonremoval (N = 426)	P
Sex (male/female)	178/97	278/148	0.886
Age [median (range)]	78 (23-99)	74.5 (20-94)	<0.001
Acute cholecystitis: mild/moderate/severe	12/208/55	22/316/88	0.859

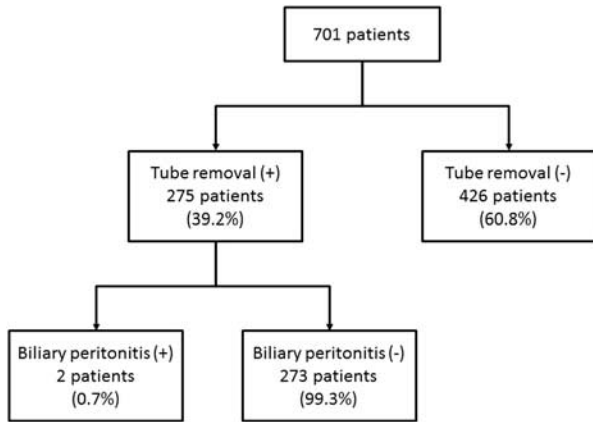


FIGURE 2. Flow diagram summarizing the percutaneous transhepatic gallbladder drainage tube removal in the study population.

patients whose tubes were removed within 10 days of placement. Cholecystitis was observed in 70 (25.4%) patients; the cumulative rates of cholecystitis following tube removal were as follows: 3.4% within 30 days, 6.8% within 90 days, 7.7% within 180 days, 15.6% within 365 days, 20.1% within 730 days, and 25.4% within 1095 days (Fig. 3).

Tube Dislodgement

Tube dislodgement was observed in 82 of 701 cases (Table 2, Fig. 4). Patients with tube dislodgement had a higher median age compared with patients without tube dislodgement (79.5 vs. 76 y; $P=0.027$). There were no significant differences in sex composition and severity of acute cholecystitis between the 2 groups. The median time to dislodgement was 12 days (range: 1 to 125 d). The cumulative tube dislodgement rates were as follows: within 7 days, 3.6%; within 10 days, 5.4%; within 20 days, 9.6%; within 30 days, 11.7%; within 90 days, 17.2%; and within 180 days, 25% (Fig. 5). PTGBD was repeated promptly in 5 cases (6%) with visible gallbladder distension because of suspected high internal pressure, whereas the clinical course was monitored conservatively using antibiotics and general supportive care in the remaining 77 (94%) cases.

Only 1 of the 77 patients (1.3%), who had the tube dislodged after 2 days, developed biliary peritonitis. There

TABLE 2. Characteristics of Patients With and Without Percutaneous Transhepatic Gallbladder Drainage Tube Dislodgement

	Tube Dislodgement (N = 82)	Nondislodgement (N = 619)	P
Sex (male/female)	58/24	398/221	0.251
Age [median (range)]	79.5 (34-93)	76 (20-99)	0.027
Acute cholecystitis: mild/moderate/severe	2/56/24	32/468/119	0.074

was no overlap in patient population between patients with tube dislodgement and patients with tube removal in this study. The 2 patients who developed biliary peritonitis after tube removal and the 1 patient who developed biliary peritonitis following tube dislodgement were completely cured using antibiotic treatment.

DISCUSSION

Even though tube removal is desirable after a shorter drainage period, or even if tube removal is possible, there are currently no guidelines concerning the advisability and timing of tube removal after PTGBD. In our cohort of 701 patients, the median time to tube removal was 16 days, and the incidence of biliary peritonitis was low. Our results indicated a possibility for safe and effective tube removal after a shorter drainage period of 7 to 10 days under the scenario of subsiding inflammation, patent cystic and common bile ducts, and absence of intraperitoneal leakage (predefined criteria for tube removal); tube removal was achieved successfully in 8 patients within 7 days, and in 35 patients within 10 days without an episode of biliary peritonitis. Furthermore, 73% of the patients in our study had tube removal within 3 weeks. Tube dislodgement occurred in 82 (11.7%) cases after a median time of 12 days following placement. However, 94% of these cases were successfully treated using antibiotics. We expect that younger patients were likely to go into surgery to remove gallbladder than

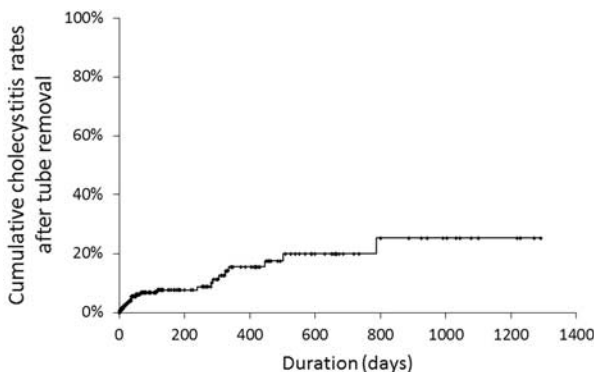


FIGURE 3. Graph of cumulative cholecystitis rate after tube removal. The x-axis represents the duration in days, and the y-axis represents the percentage.

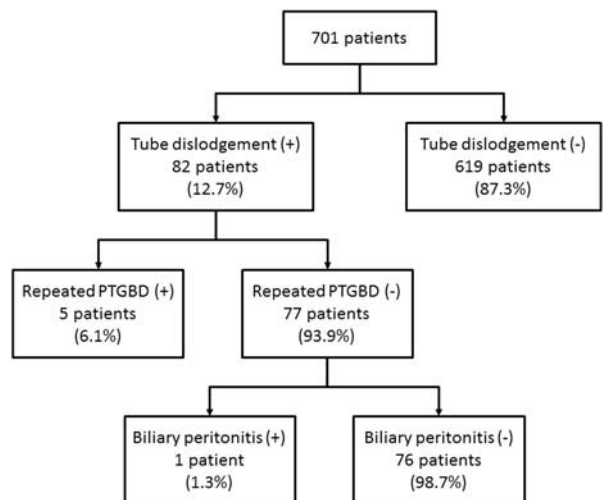


FIGURE 4. Flow diagram summarizing tube dislodgement followed by percutaneous transhepatic gallbladder drainage (PTGBD) in the study population.

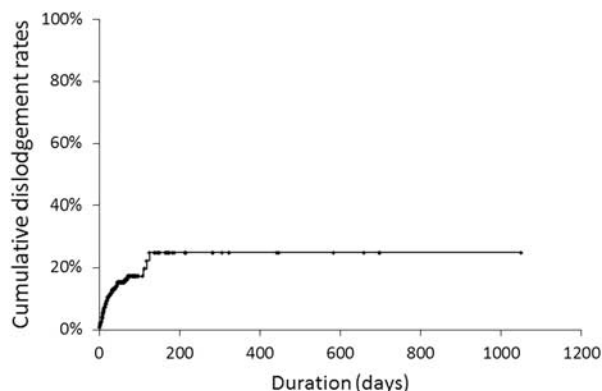


FIGURE 5. Graph of cumulative tube dislodgement rate. The x-axis represents the duration in days, and the y-axis represents the percentage.

elderly patients; hence, tube removal was likely not to be performed until surgery in younger patients. We expect that elderly patients were likely to pull out the PTGBD tube by themselves accidentally because of delirium or dementia.

A serious complication of PTGBD tube removal is bile leakage into the peritoneum, which can result in sepsis and bile peritonitis.^{13–15} Hatjidakis et al¹⁶ performed a prospective assessment of events after tube removal in 33 patients. Of these 33 patients, 3 patients inadvertently underwent tube removal in 3 to 5 days after the drainage, which resulted in bile leakage in 2 cases (6%). Compared with a previous study in 163 patients using the same surgical technique for tube removal as used in the present study, which showed a mean duration of drainage of 42.6 days, the median time to tube removal was only 16 days in the present study.¹¹ Our results thus indicated a possibility for safe and effective tube removal after a shorter drainage period. This difference in outcome may be due to the larger sample size used in our study (n = 701) or due to the effectiveness of the feasibility examination that was performed in our patients before tube removal.

Previous reports have highlighted the significance of the formation and maturation of a sealed track before tube removal to prevent bile leakage.^{11,15,16} Various studies have indicated that track maturation occurred within 20 days,^{15,16} and tube removal was safe and effective after a minimum of ~3 weeks.¹¹ However, the results of our study demonstrated the possibility of safe and effective tube removal at a shorter duration of 7 to 10 days after PTGBD if the criteria for tube removal were met. Nearly 27% of the patients in our retrospective study had tube removal after 3 weeks. We speculate this was because doctors were guided by previous reports recommending a minimum of 3 weeks before tube removal,¹¹ or because it took > 3 weeks in several patients to meet the 3 predefined criteria for drainage tube removal. Notably, the complication of biliary peritonitis was rarely observed in our cohort, and all patients who developed biliary peritonitis following tube removal or tube dislodgement were successfully treated using antibiotics. To the best of our knowledge, this is the first study to report that drainage tube removal is safe and effective when performed after a shorter drainage period. Furthermore, this study included a significantly large cohort of patients with acute cholecystitis who underwent PTGBD (n = 701), compared with other previous studies on this topic.^{11,15}

However, this study had some limitations. First, the study was retrospective in nature, and we did not report on disease duration or confirm whether early tube removal would be safe and effective in all patients undergoing PTGBD for acute cholecystitis. In particular, early removal of a PTGBD tube may not be safe where maturation of the drainage tract could be potentially delayed or complicated by fibrous adhesion, as in cases of chronic hepatitis or liver cirrhosis. Second, it is not known whether the cases of acute cholecystitis in this study were benign, as cholecystectomy was not performed in some cases. It has been previously reported that only ~10% of patients with acute cholecystitis are treated using PTGBD¹⁷; hence, there is a possibility of selection bias in this study cohort. Last, tubes of different diameters (7 or 8 Fr) were used in patients in this study, and we did not investigate the relationship between tube diameter and tube removal. Prospective studies are required to further support the safety of tube removal after a shorter drainage period with bile leakage in specific patient populations. Nevertheless, our findings demonstrated the possibility of safe and effective removal of drainage tube following a shorter duration of 7 to 10 days if the criteria for tube removal were met, and revealed a new clinical management strategy for acute cholecystitis. Furthermore, the results can be used by gastroenterologists, surgeons, and researchers in the management of acute cholecystitis.

ACKNOWLEDGMENTS

Editorial support, in the form of medical writing, assembling tables, and creation of high-resolution images based on authors' detailed directions, collating author comments, copyediting, fact checking, and referencing, was provided by Editage, Cactus Communications.

REFERENCES

- Miura F, Takada T, Strasberg SM, et al. TG13 flowchart for management of acute cholangitis and cholecystitis. *J Hepatobiliary Pancreat Sci.* 2013;20:47–54.
- Yamashita Y, Takada T, Strasberg SM, et al. TG13 surgical management of acute cholecystitis. *J Hepatobiliary Pancreat Sci.* 2013;20:89–96.
- Loozen CS, van Ramshorst B, van Santvoort HC, et al. Early cholecystectomy for acute cholecystitis in the elderly population: a systematic review and meta-analysis. *Dig Surg.* 2017;34:371–379.
- Takada T, Strasberg SM, Solomkin JS, et al. TG13: Updated Tokyo Guidelines for the management of acute cholangitis and cholecystitis. *J Hepatobiliary Pancreat Sci.* 2013;20:1–7.
- Yamada K, Yamashita Y, Yamada T, et al. Optimal timing for performing percutaneous transhepatic gallbladder drainage and subsequent cholecystectomy for better management of acute cholecystitis. *J Hepatobiliary Pancreat Sci.* 2015;22:855–861.
- Privalov VA, Shramchenko VA, Gubnitskii AE, et al. Surgical management of acute cholecystitis in elderly and old age patients. *Khirurgiia (Mosk).* 1998;7:28–30.
- Melin MM, Sarr MG, Bender CE, et al. Percutaneous cholecystostomy: a valuable technique in high-risk patients with presumed acute cholecystitis. *Br J Surg.* 1995;82:1274–1277.
- Welschbillig-Meunier K, Pessaux P, Lebigot J, et al. Percutaneous cholecystostomy for high-risk patients with acute cholecystitis. *Surg Endosc.* 2005;19:1256–1259.
- McKay A, Abulfaraj M, Lipschitz J. Short- and long-term outcomes following percutaneous cholecystostomy for acute cholecystitis in high-risk patients. *Surg Endosc.* 2012;26:1343–1351.

10. Okamoto K, Suzuki K, Takada T, et al. Tokyo Guidelines: flowchart for the management of acute cholecystitis. *J Hepatobiliary Pancreat Sci.* 2018;25:55–72.
11. Wise JN, Gervais DA, Akman A, et al. Percutaneous cholecystostomy catheter removal and incidence of clinically significant bile leaks: a clinical approach to catheter management. *AJR Am J Roentgenol.* 2005;184:1647–1651.
12. Tsuyuguchi T, Itoi T, Takada T, et al. TG13 indications and techniques for gallbladder drainage in acute cholecystitis (with videos). *J Hepatobiliary Pancreat Sci.* 2013;20:81–88.
13. vanSonnenberg E, D'Agostino HB, Goodacre BW, et al. Percutaneous gallbladder puncture and cholecystostomy: results, complications, and caveats for safety. *Radiology.* 1992;183:167–170.
14. Picus D, Hicks ME, Darcy MD, et al. Percutaneous cholecystolithotomy: analysis of results and complications in 58 consecutive patients. *Radiology.* 1992;183:779–784.
15. D'Agostino HB, vanSonnenberg E, Sanchez RB, et al. Imaging of the percutaneous cholecystostomy tract: observations and utility. *Radiology.* 1991;181:675–678.
16. Hatjidakis AA, Karampekios S, Prassopoulos P, et al. Maturation of the tract after percutaneous cholecystostomy with regard to access route. *Cardiovasc Intervent Radiol.* 1998; 21:36–40.
17. Yokoe M, Takada T, Hwang TL, et al. Descriptive review of acute cholecystitis: Japan-Taiwan collaborative epidemiological study. *J Hepatobiliary Pancreat Sci.* 2017;24:319–328.