

# Early Experience With Tenecteplase at a Comprehensive Stroke Center

Spozhy Panezai, MD, Ilya Dubinsky, PharmD, BCPS, Sindhu Sahito, MD, Nancy Gadallah, DO, Laura Suhan, APN, Siddhart Mehta, MD, and Jawad Kirmani, MD

**Correspondence**  
Dr. Panezai  
spanezai@hotmail.com

*Neurology: Clinical Practice* December 2021 vol. 11 no. 6 e885-e889 doi:10.1212/CPJ.0000000000001096

## Abstract

### Purpose of Review

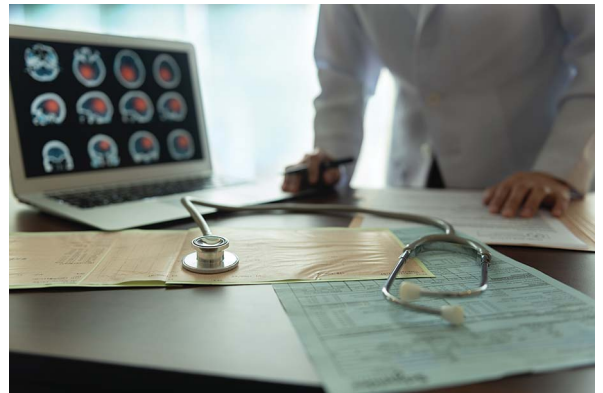
Tenecteplase has been studied and recommended as an alternative thrombolytic agent in patients with acute stroke. A brief review of clinical trials and guidelines pertinent to our clinical decision algorithm is described. This is followed by operational steps that were made to create and implement a clinical pathway based on available evidence in which tenecteplase is used in select patients with stroke at our comprehensive stroke center.

### Recent Findings

A number of patients have been treated at our center with IV tenecteplase. A case is presented to illustrate the successful implementation of this new process.

### Summary

Development of our protocol is discussed in detail to enable other centers to create their own clinical pathways for thrombolytic treatment of acute ischemic stroke using tenecteplase.



To date, IV alteplase is the only Food and Drug Administration (FDA)-approved treatment for patients with acute ischemic stroke who present within 3 hours of symptom onset, and it is also recommended for treatment in select patients up to 4.5 hours.<sup>1</sup> Tenecteplase, an alternative IV thrombolytic agent, is a genetically modified variant of alteplase with certain advantages including longer half-life, which allows for bolus administration, greater resistance to plasminogen activator inhibitor-1, and greater fibrin specificity, which reduces fibrinogen depletion and the risk of systemic bleeding.<sup>2,3</sup> It is approved by the FDA in treatment of ST-segment elevation myocardial infarction at a dose of 0.5 mg/kg and has been shown to have similar 30-day mortality to alteplase but with fewer systemic hemorrhages.<sup>4</sup> In a recent meta-analysis of 5 randomized trials, tenecteplase was found to be noninferior to alteplase in acute ischemic stroke and showed a similar safety profile.<sup>5</sup> The latest update to the American Stroke Association (ASA) guidelines on Emergency Management of Acute Ischemic Stroke and TIA includes recommendations on the use of tenecteplase as an alternative to alteplase.<sup>1</sup> Based on the EXTEND IA TNK trial, the use of tenecteplase 0.25 mg/kg IV bolus was found to be superior to IV alteplase in patients who presented within 4.5 hours and were eligible to undergo mechanical thrombectomy.<sup>6</sup> In an earlier trial (NOR-TEST), in patients who had no major intracranial occlusion and had minor neurologic impairment (National Institutes of Health Stroke Scale score (NIHSS) < 6), tenecteplase 0.4 mg/kg IV bolus was beneficial

HMH JFK University Medical Center (SP, SS, NG, LS, SM, JK), Neuroscience Institute, Edison, NJ; and Emergency Department (ID), HMH JFKUMC, Edison, NJ.

Funding information and disclosures are provided at the end of the article. Full disclosure form information provided by the authors is available with the full text of this article at [Neurology.org/cp](https://www.neurology.org/cp).

The Article Processing Charge was funded by the authors.

This is an open access article distributed under the terms of the Creative Commons Attribution-NonCommercial-NoDerivatives License 4.0 (CC BY-NC-ND), which permits downloading and sharing the work provided it is properly cited. The work cannot be changed in any way or used commercially without permission from the journal.

within 6 hours of symptom onset.<sup>7</sup> Based on ASA recommendations and results of other trials, our comprehensive stroke center created a clinical pathway for selecting and treating patients with acute ischemic stroke with IV tenecteplase.

## Case 1

An 89-year-old Caucasian woman with a history of hypertension and atrial fibrillation presented with sudden-onset right hemiparesis, left gaze deviation, and aphasia. Her NIHSS score was 21. Brain CT showed a hyperdense sign in the left M1 segment of the middle cerebral artery, and the CT angiogram showed segmental occlusion involving the mid to distal left M1 segment and occlusion of the inferior left M2 sylvian branch (Figure 1). Blood pressure on presentation was 177/72 mm Hg, and blood glucose was 152 mg/dL. The patient was within the time window for thrombolytic therapy. After a brief delay to confirm that the patient was not on anticoagulation, she was treated with tenecteplase 19.5 mg IV bolus (dose 0.25 mg/kg—off-label administration after obtaining consent from the patient's family, which included verbal and documented discussion of risks and benefits). The time from symptom onset to thrombolysis was 1 hour and 25 minutes. The door-to-needle time was 38 minutes. The patient was transferred to the neurointerventional suite for mechanical thrombectomy. Before the procedure, the patient's NIHSS score improved to 18. The door-to-puncture time was 63 minutes, and tenecteplase administration to groin puncture time was 25 minutes. Diagnostic angiography revealed that the patient had recanalization of the left M1 occlusion with remaining distal cortical branch filling defect, so thrombectomy was not performed. After the angiogram, the patient's NIHSS score improved to 3, and by the next day, it improved to 1 for right lower extremity drift. Repeat CT head after 24 hours did not demonstrate any evidence of hemorrhage. MRI revealed small multifocal left parietal, frontal, caudate, and left posterior putaminal acute infarcts.

The patient was started on oral anticoagulation with apixaban 5 mg twice daily for secondary stroke prevention for presumed cardioembolic origin and was discharged to rehabilitation therapy.

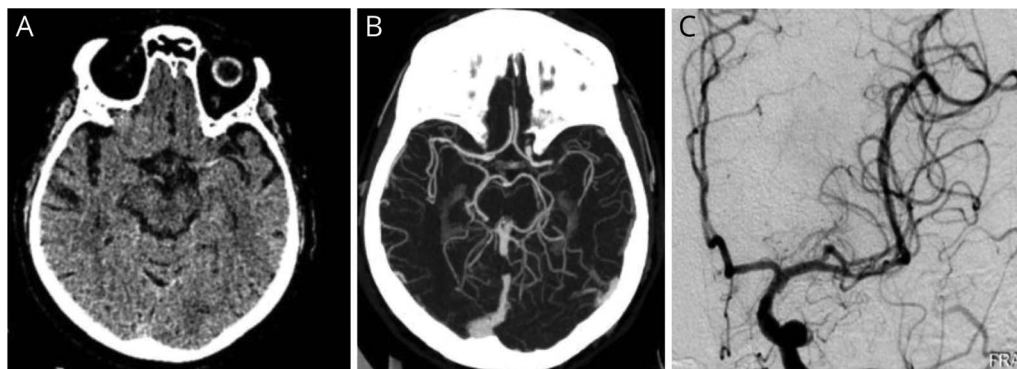
## Discussion

Our program regularly conducts reviews of our stroke clinical practice guidelines to keep current with published recommendations. After review of the 2019 ASA's updated guidelines, the HMH JFK Medical Center's Stroke and Neurovascular (SNC) team created a pathway in which tenecteplase could be offered to select patients presenting with acute ischemic stroke. This pathway was created with the joint efforts of the SNC members (physicians and advanced practice nurses), clinical pharmacy specialists, emergency medicine, and nursing.

### Dose and Clinical Characteristics Determination

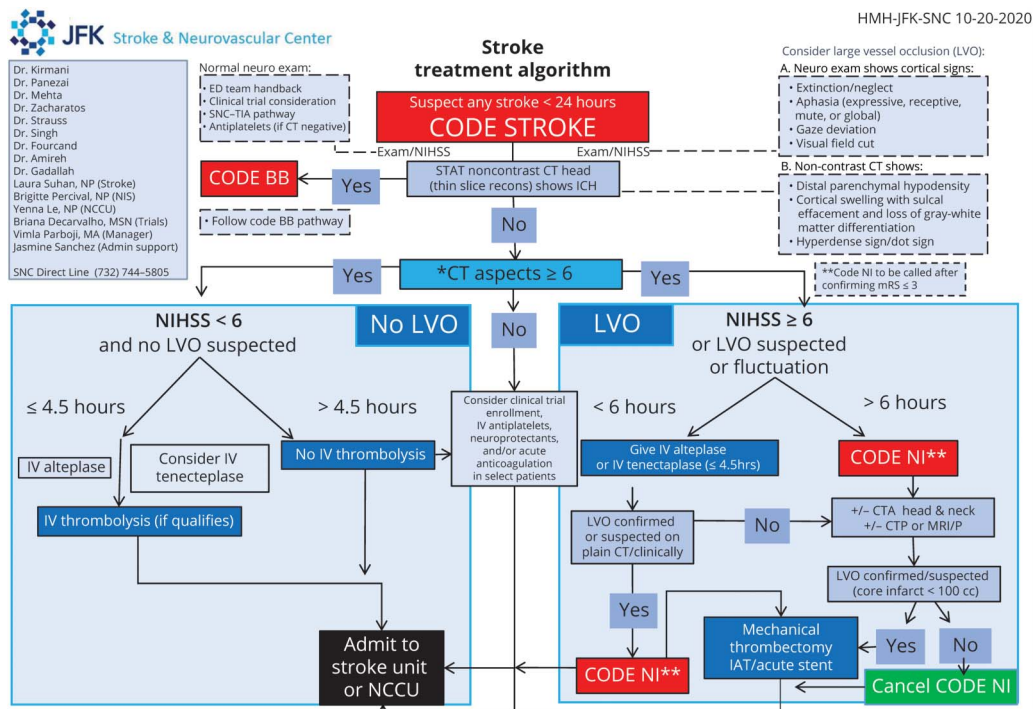
An initial literature search was performed to establish dosing, treatment windows, and patient selection at our center. In 2010, a small phase 2b randomized controlled trial compared 0.1, 0.25, and 0.4 mg/kg IV tenecteplase with alteplase 0.9 mg/kg in patients with acute ischemic stroke within 3 hours of symptom onset.<sup>8</sup> Although conclusions could not be drawn because the trial was terminated prematurely for slow enrollment, it helped examine optimal dosing for tenecteplase. In 2012, results of another phase 2b study that randomized 75 patients to be treated with 0.1 or 0.25 mg/kg of tenecteplase or 0.9 mg/kg alteplase IV within 6 hours of stroke symptom onset were published. After 24 hours of treatment, tenecteplase use was found to be associated with better reperfusion and clinical improvement with no significant between-group differences in intracerebral hemorrhage or other serious adverse events.<sup>9</sup> The ATTEST trial, published in 2015, was a single-center, phase 2 randomized trial that assessed 104 patients with stroke eligible for either tenecteplase 0.25 mg/kg or alteplase 0.9 mg/kg IV. It was determined that clinical outcomes did not differ between

**Figure 1** Case 1



(A) CT of the head revealing hyperdense left MCA. (B) CTA documenting left MCA M1 occlusion. (C) Cerebral angiography demonstrating recanalization of the left MCA after tenecteplase IV bolus. CTA = CT angiography; MCA = middle cerebral artery.

**Figure 2** HMH JFK Stroke and Neurovascular Center's Acute Stroke Treatment Clinical Pathway



Code NI = Code Neurointervention; Code BB = Code Brain Bleed; IAT = intra-arterial thrombolysis; LVO = large-vessel occlusion; CTP = CT perfusion; MRP = magnetic resonance perfusion; NCCU = neurocritical care unit.

the 2 groups and larger trials would be required to further assess safety and efficacy.<sup>10</sup>

Based on the above evidence, ASA guidelines, and reviews by other established authorities in the field, our multidisciplinary stroke committee determined that 0.25 mg/kg tenecteplase IV bolus in patients with and without large vessel occlusion (LVO) within 4.5 hours showed a trend toward increased early neurologic improvement and lower risk of intracerebral hemorrhage compared with alteplase.<sup>1,2,11</sup> Recent publication of the Extend IA TNK 2 study confirmed that 0.4-mg/kg IV compared with 0.25 mg/kg IV in treating patients with LVO did not improve reperfusion or functional outcomes.<sup>12</sup> This trial was also the first substantial head-to-head comparison of the 2 candidate doses of tenecteplase and suggested that the lower dose of 0.25 mg/kg was as effective and perhaps safer. The Norwegian tenecteplase stroke trial (NOR-TEST) had already demonstrated no significant difference and a similar safety profile between tenecteplase 0.4 mg/kg vs alteplase 0.9 mg/kg dose. A 2019 post hoc sub-analysis of severely neurologically impaired patients (NIHSS score  $\geq 15$ ) from the NOR-TEST trial found that there was an increase in all-cause mortality at 90 days in the tenecteplase group compared with the alteplase group.<sup>13</sup> Because of this concern, as well as the fact that NOR-TEST enrolled patients with mostly minor neurologic impairment, a conservative decision was made that for patients without LVO, tenecteplase 0.25 mg/kg (maximum dose 25 mg) would be considered over alteplase only in patients with an NIHSS score  $< 6$ .

### Time Window Selection Rationale

IV thrombolysis with alteplase remains the standard of care before thrombectomy for eligible patients within 4.5 hours of ischemic stroke onset.<sup>1</sup> For our tenecteplase clinical protocol, we limited the treatment time window to 4.5 hours, as previously established for alteplase and as studied in the EXTEND IA TNK, NOR-TEST, and ATTEST trials.<sup>6,7,10</sup>

In large-vessel arterial occlusions, alteplase has been found to result in reperfusion in only a minority of patients before thrombectomy.<sup>6</sup> Results of previous nonrandomized studies have suggested that patients who have a mismatch between the volume of brain tissue that may be salvaged and the volume of infarcted tissue as seen on imaging could benefit from reperfusion of occluded proximal anterior circulation vessels, even when the reperfusion is performed more than 6 hours after the patient was last known to be well.<sup>14,15</sup> A small Canadian study (N = 16) tested 0.25 mg/kg (maximum dose 25 mg) of tenecteplase using imaging selection criteria that identified ischemic penumbra. In this study, one patient (6.3%) developed symptomatic hemorrhagic transformation (sHT). This HT rate seems comparable to that reported in previous trials of tenecteplase in ischemic stroke, suggesting the feasibility of treating patients outside established treatment windows.<sup>16</sup> In a randomized trial in patients with a penumbral pattern within 6 hours of onset, sHT occurred in 2/25 tenecteplase-treated patients (8%) and in 3/25 tPA-treated patients (12%).<sup>10</sup> Finally, a recent open-label pilot

**Figure 3** Code Stroke Box With Separately Packaged Thrombolytic Agents



study reported that tenecteplase in minor ischemic stroke (NIHSS score  $\leq 5$ ) within 12 hours of symptom onset and with intracranial occlusion was associated with an sHT rate of 4% (1/25 patients treated with 0.25 mg/kg).<sup>17</sup> With this rationale, we continue to enroll patients in TIMELESS (NCT03785678), a clinical trial looking at using tenecteplase in patients with LVO within 4.5–24 hours of symptom onset, understanding that the tissue-based treatment effect will continue to be studied within a trial setting until there is enough evidence to support its application in clinical practice.

### Process Development and Implementation

Our core stroke committee, multidisciplinary stroke committee, and the HMH Stroke Council had many discussions about the use of tenecteplase until final approval was obtained with regard to the patient type and time window. A proposal to obtain tenecteplase on formulary was written and presented to the institution's Pharmacy & Therapeutics committee. Although the new process was in the midst of planning, the COVID-19 pandemic delayed its implementation. Once there was a reduction in the COVID-19 surge and usual operations were possible, our clinical practice guidelines and code stroke policies were updated to outline the new pathway, and our Acute Stroke Treatment Algorithm (Figure 2) was updated for rapid decision making and educational purposes. Our standard Code Stroke Evaluation form, which contains fields for time metrics, calculation of NIHSS, and treatment recommendations, was adjusted to include documentation of verbal consent to administer tenecteplase or alteplase.

### Safety Assurance

During process development, it was found that a significant safety risk existed when alteplase or tenecteplase was used in a

similar setting. Between 2000 and 2014, the FDA received 21 reports of medication errors involving alteplase and tenecteplase, including reports of accidental substitution.<sup>18</sup> These errors resulted in failure to treat or overdose of the agent. It is important to note that these substitution errors occurred at a time when alteplase and tenecteplase were primarily used in 2 different clinical settings, alteplase primarily in acute ischemic stroke (AIS) and tenecteplase primarily in acute myocardial infarction (AMI). This suggests that safety risk may be higher when both agents are used in the same setting.

It was determined by our pharmacy committee that tenecteplase could not simply replace alteplase on our hospital formulary as the only fibrinolytic agent; several strategies were implemented to reduce latent safety risks within the administration process. A major contributing factor to thrombolytic drug errors is the use of the abbreviation tPA or TNK. These abbreviations are listed in the Institute of Safe Medication Practice's list of error-prone abbreviations.<sup>19</sup> In addition, given the ubiquitous use of thick layers of PPE and respirators following the COVID-19 pandemic, errors stemming from verbal orders using these abbreviations are even more profound. To this end, the prohibited abbreviations were removed from all written materials and discouraged during regular discourse; they were replaced with the full generic names alteplase and tenecteplase. The pharmacy department redesigned the Code Stroke treatment box to include 2 separately packaged self-contained compartments, which includes all the equipment required (i.e., syringes, needles, and dosing guide) for that specific agent, to make it more difficult to inadvertently substitute one agent for another (Figure 3). The thrombolytic order set was updated to include tenecteplase with proper dosing and mixing instructions. Any practice of preparing the thrombolytic ahead of actual order entry was discouraged in favor of a real-time order entry, identification, and administration process. Order entry was required first, followed by scanning of the thrombolytic medication barcode and visual verification by multiple stroke team members before administration. Once education was provided to all nursing and physician staff involved in our Code Stroke response, our clinical pathway for use of tenecteplase in AIS was finally initiated in early October 2020.

### Early Efficacy and Workflow Advantages

Thus far, 8 patients with and without LVO have received tenecteplase according to our institute's protocol with excellent results and no systemic or intracranial hemorrhage. Of interest, at this time of the COVID-19 pandemic, tenecteplase seems to be advantageous over alteplase. Single bolus administration of tenecteplase over 5–10 seconds without a need for IV infusion and monitoring over 1 hour, as required with IV alteplase, reduces exposure to patients without compromising quality of care and reduces the need for extra equipment such as infusion pumps.<sup>20</sup> In fact, it has been recently found that a switch to tenecteplase from

alteplase in a multihospital network resulted in similar outcomes, cost savings, and no safety concerns.<sup>21</sup> As results of ongoing phase 3 studies come out, further considerations and adjustments will be made to our protocol, including treating patients without LVO and higher NIHSS, wake-up strokes, and those presenting beyond the 4.5-hour thrombolytic treatment window.

## Future Direction

The ATTEST-2 superiority trial (estimated completion early 2021) comparing tenecteplase 0.25 mg/kg vs alteplase 0.9 mg/kg is enrolling patients with AIS eligible for IV thrombolysis but excluding patients with any acute neurointervention treatment (NCT02814409). The AcT noninferiority trial (estimated completion in December 2022) comparing tenecteplase 0.25 mg/kg vs alteplase 0.9 mg/kg is enrolling patients with AIS who are eligible for IV thrombolysis alone or before endovascular treatment (NCT03889249). Finally, the TIMELESS trial (NCT03785678, estimated completion in April 2022) as described above will clarify the use of tenecteplase 0.25 mg/kg vs placebo for LVO stroke with the onset of symptoms between 4.5 hours and 24 hours. Results of these and other trials may further augment the use of tenecteplase in clinical practice. The future for treating acute ischemic stroke is exciting as we continue to introduce new agents, improve processes, enhance safety, and expand treatment eligibility. Tenecteplase may in the future prove to be a successful agent that safely and effectively treats an even larger number of patients with acute ischemic stroke.

## Study Funding

No targeted funding reported.

## Disclosure

The authors report no disclosures relevant to the manuscript. Full disclosure form information provided by the authors is available with the full text of this article at [Neurology.org/cp](http://Neurology.org/cp).

## Publication History

Received by *Neurology: Clinical Practice* November 4, 2020. Accepted in final form February 28, 2021.

## Appendix Authors

Name	Location	Contribution
<b>Spozhmy Panezai, MD</b>	HMH JFK Medical Center, Edison, NJ	Drafted the manuscript for intellectual content and creation of clinical pathway
<b>Ilya Dubinsky, PharmD, BCPS</b>	HMH JFK Medical Center, Edison, NJ	Revised the manuscript for intellectual content and cocreation of the clinical pathway
<b>Sindhu Sahito, MD</b>	HMH JFK Medical Center, Edison, NJ	Case write-up

## Appendix (continued)

Name	Location	Contribution
<b>Nancy Gadallah, DO</b>	HMH JFK Medical Center, Edison, NJ	Drafted the manuscript
<b>Laura Suhan, APN</b>	HMH JFK Medical Center, Edison, NJ	Cocreation of the clinical pathway
<b>Siddhart Mehta, MD</b>	HMH JFK Medical Center, Edison, NJ	Obtained imaging for figures
<b>Jawad Kirmani, MD</b>	HMH JFK Medical Center, Edison, NJ	Revised the manuscript for intellectual content and cocreation of the clinical pathway

## References

1. Powers WJ, Rabinstein AA, Ackerson T, et al. Guidelines for the early management of patients with acute ischemic stroke: 2019 update to the 2018 guidelines for the early management of acute ischemic stroke: a guideline for healthcare professionals from the American Heart Association/American Stroke Association. *Stroke*. 2019;50:e344-e418.
2. Logallo N, Kvistad CE, Thomassen L. Therapeutic potential of tenecteplase in the management of acute ischemic stroke. *CNS Drugs*. 2015;29:811-818.
3. Dunn CJ, Goa KL. Tenecteplase: a review of its pharmacology and therapeutic efficacy in patients with acute myocardial infarction. *Am J Cardiovasc Drugs*. 2001;1:51-66.
4. Van De Werf F, Adgey J, Ardissino D, et al. Single-bolus tenecteplase compared with front-loaded alteplase in acute myocardial infarction: the ASSENT-2 double-blind randomised trial. *Lancet*. 1999;354:716-722.
5. Burgos AM, Saver JL. Evidence that tenecteplase is noninferior to alteplase for acute ischemic stroke: meta-analysis of 5 randomized trials. *Stroke*. 2019;50(8):2156-2162.
6. Campbell BCV, Mitchell PJ, Churilov L, et al. EXTEND-IA TNK Investigators. Tenecteplase versus alteplase before thrombectomy for ischemic stroke. *N Engl J Med*. 2018;378:1573-1582.
7. Logallo N, Novotny V, Assmus J, et al. Tenecteplase versus alteplase for management of acute ischaemic stroke (NOR-TEST): a phase 3, randomised, open-label, blinded endpoint trial. *Lancet Neurol*. 2017;16:781-788.
8. Haley EC, Thompson JL, Grotta JC, et al. For the Tenecteplase in Stroke Investigators. Phase IIB/III trial of tenecteplase in acute ischemic stroke: results of a prematurely terminated randomized clinical trial. *Stroke*. 2010;41:707-711.
9. Parsons M, Spratt N, Bivard A, et al. A randomized trial of tenecteplase versus alteplase for acute ischemic stroke. *N Engl J Med*. 2012;366:1099-1107.
10. Huang X, Cheripelli BK, Lloyd SM, et al. Alteplase versus tenecteplase for thrombolysis after ischaemic stroke (ATTEST): a phase 2, randomised, open-label, blinded endpoint study. *Lancet Neurol*. 2015;14:368-376.
11. Xu N, Chen Z, Zhao C, et al. Different doses of tenecteplase vs alteplase in thrombolysis therapy of acute ischemic stroke: evidence from randomized controlled trials. *Drug Des Devel Ther*. 2018;12:2071-2084.
12. Campbell BCV, Mitchell PJ, Churilov L, et al. Effect of intravenous tenecteplase dose on cerebral reperfusion before thrombectomy in patients with large vessel occlusion ischemic stroke: the EXTEND-IA TNK Part 2 randomized clinical trial. *JAMA*. 2020;323(13):1257-1265.
13. Kvistad C, Novotny V, Kurz M, et al. Safety and outcomes of tenecteplase in moderate and severe ischemic stroke - results from NOR-TEST. *Stroke*. 2019;50(5):1279-1281.
14. Jovin TG, Liebeskind DS, Gupta R, et al. Imaging-based endovascular therapy for acute ischemic stroke due to proximal intracranial anterior circulation occlusion treated beyond 8 hours from time last seen well: retrospective multicenter analysis of 237 consecutive patients. *Stroke*. 2011;42(8):2206-2211.
15. Lansberg MG, Cereda CW, Mlynash M, et al. Diffusion and perfusion imaging evaluation for understanding stroke evolution 2 (DEFUSE 2) study investigators. Response to endovascular reperfusion is not time-dependent in patients with salvageable tissue. *Neurology*. 2015;85(8):708-714.
16. Kate M, Wannamaker R, Kamble H, et al. Penumbra imaging-based thrombolysis with tenecteplase is feasible up to 24 hours after symptom onset. *J Stroke*. 2018;20(1):122-130.
17. Coutts SB, Dubuc V, Mandzia J, et al. Tenecteplase-tissue-type plasminogen activator evaluation for minor ischemic stroke with proven occlusion. *Stroke*. 2015;46:769-774.
18. Dillon G, Stevens S, Dusenbury W, et al. Choosing the correct "-ase" in acute ischemic stroke: alteplase, tenecteplase, and reteplase. *Adv Emerg Nurs J*. 2019;41(3):271-278.
19. Cohen MR, Smetzer JL. Alteplase and tenecteplase confusion; lack of E-prescribing interoperability leads to double dosing; accidental overdoses involving fluorouracil infusions. *Hosp Pharm*. 2015;50(10):849-854.
20. Warach SJ, Saver JL. Stroke thrombolysis with tenecteplase to reduce emergency department spread of coronavirus disease 2019 and shortages of alteplase. *JAMA Neurol*. Published July 20, 2020. doi: 10.1001/jamaneurol.2020.2396.
21. Warach SJ, Miley J, Allen L, et al. *Prospective Observational Cohort Study of Tenecteplase as Standard of Care Thrombolysis in a Multihospital Network*. Initial safety and feasibility results\* [abstract LB10]. International Stroke Conference. Feb 2020; Los Angeles, CA.